

Minimally Invasive Direct Coronary Bypass Surgery via Distal Mini-sternotomy: Promising Clinical Results with Anaortic, Multivessel, All-arterial Technique

Martinović, Ivo; Lindemann, S.; Irsusi, M.; Mirat, Jure; Včev, Aleksandar; Wittlinger, T.; Noutsias, M.

Source / Izvornik: Herz, 2018, 44, 666 - 672

Journal article, Published version

Rad u časopisu, Objavljena verzija rada (izdavačev PDF)

<https://doi.org/10.1007/s00059-018-4696-0>

Permanent link / Trajna poveznica: <https://um.nsk.hr/um:nbn:hr:239:333478>

Rights / Prava: [Attribution 4.0 International](#)/[Imenovanje 4.0 međunarodna](#)

Download date / Datum preuzimanja: **2024-07-23**



Repository / Repozitorij:

[Repository UHC Osijek - Repository University Hospital Centre Osijek](#)

Herz

<https://doi.org/10.1007/s00059-018-4696-0>

Received: 22 January 2018

Revised: 1 March 2018

Accepted: 12 March 2018

© Springer Medizin Verlag GmbH, ein Teil von Springer Nature 2018



CrossMark

I. Martinovic^{1,3} · S. Lindemann² · M. Irgsusi¹ · J. Mirat³ · A. Vcev³ · T. Wittlinger⁴ · M. Noutsias⁵¹ Department of Cardiovascular Surgery, Philipps University of Marburg, Marburg, Germany² Department of Cardiology, Helios Hospital, Warburg, Germany³ Department of Internal Medicine, “J.J. Strossmeyer” University Osijek, Osijek, Croatia⁴ Department of Cardiology, Asklepios Hospital Goslar, Goslar, Germany⁵ Mid-German Heart Center, Department of Internal Medicine III (KIM-III), Division of Cardiology, Angiology and Intensive Medical Care, University Hospital Halle, Martin-Luther-University Halle, Halle (Saale), Germany

Minimally invasive direct coronary bypass surgery via distal mini-sternotomy

Promising clinical results with anaortic, multivessel, all-arterial technique

Despite being a more demanding surgical technique than conventional coronary artery bypass grafting (CABG) with cardiopulmonary bypass, off-pump CABG (OPCAB) was optimistically revived and expanded in the past 20 years to be more attractive for patients [1, 2]. The objectives were less tissue trauma, less myocardial damage caused by aortic cross-clamp-induced ischemia, better cosmetic results, and better clinical outcomes, especially neurological outcomes that have been confirmed with an anaortic or “aortic no-touch” technique in previously published reports [3]. Also, intensive care unit (ICU) and hospital stays were considered in the cost–benefit analysis. CABG can be performed via full sternotomy, mini-sternotomy, thoracoscopically, or endoscopically with the use of computer-assisted telemanipulation technology, either with or without cardiopulmonary bypass [4–6]. OPCAB can be performed in different ways also using a minimally invasive direct approach (MIDCAB). This technique usually consists of a left anterior small thoracotomy (LAST) and is in principle limited to single left anterior descending artery (LAD) revascularization only. Because several OPCAB methods have been introduced gradually

in clinical practice, the existence of any beneficial effect needs to be verified for every approach. The objectives of the distal mini-sternotomy (DIMS) method were to optimize the minimally invasive approach permitting both harvesting of the internal thoracic arteries (ITA) as well as excellent exposure and immobilization of the left (LCA) and right coronary arteries (RCA). According to only a few published reports, the MIDCAB procedure with this approach is feasible [7–9]. We describe our initial experience with a minimally invasive surgical approach consisting of a DIMS for anaortic, multivessel, all-arterial, minimally invasive direct CABG. This work represents a detailed standardized study that prospectively evaluated the feasibility and safety of performing DIMS and the clinical outcomes of the patients who underwent multivessel MIDCAB with this approach in 1 year. This minimally invasive technique is described here for the potential reduction of perioperative morbidity and accelerated postoperative recovery.

Patients and methods

There were special indications for patient selection. Patients who had major

coronary artery stenosis (75% angiographic diameter stenosis) limited to a double coronary distribution on the anterior and inferior surface of the heart were selected for revascularization using MIDCAB through the DIMS approach. Contraindications for the DIMS approach included the presence of major coronary artery disease on the lateral surface of the heart and acute myocardial infarction requiring intravenous administration of nitrates or an intra-aortic balloon pump. Patients were not excluded on the basis of their age, functional status, diameter of the target vessels, or other preoperative risk factors, such as previous stroke or myocardial infarction. From January 2016 through January 2017, 12 patients (ten men and two women) with a mean age of 61.5 ± 5.2 years (range: 52–71 years) underwent multivessel MIDCAB via the DIMS approach. All of the patients had LAD and/or diagonal branch disease and RCA disease. Seven patients were in New York Heart Association (NYHA) functional class III before the operation, while five were in class II. All of the MIDCAB procedures were performed by the same surgeon. All patients received arterial grafts. The mean number of grafts per patient was 2.08 ± 0.5 (range:

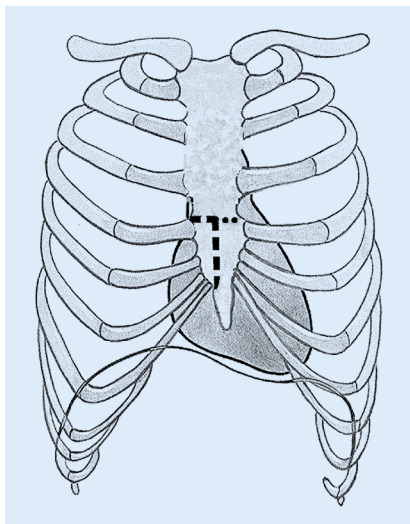


Fig. 1 ▲ Reverse L- or/and T-shaped distal mini-sternotomy

2–3). The surgical procedure consists of a technique that has been described previously [7–9] and remained constant throughout the study period: Distal midline skin incision from the fourth intercostal space to the xiphoid process with longitudinal division of the distal third or half sternum up to the third rib, with reverse L- or T-shaped division of the sternum was performed.

Patient follow-up

Electrocardiograms (ECGs) were recorded at least four times during admission, and serial myocardial fractions of creatine kinase (CK-MB) were determined at 1 h and every 4 h postoperatively on the first two postoperative days and then every 12 and 24 h for the next few days in all patients. Echocardiographic examinations were performed preoperatively, intraoperatively, and postoperatively at discharge to evaluate changes in the regional wall motion. Perioperative myocardial infarction was diagnosed in the presence of one or both of the following criteria: (1) CK-MB levels greater than 80 IU/l, and (2) the development of irreversible S-T elevation and new Q waves. Coronary angiography was performed only on patients who fulfilled the corresponding criteria. After extubation, all patients were given oral analgesic tablets (hydromorphone 8 mg/day) two times daily for 2 days. Pain intensity was

analyzed using the Verbal Rating Scale [12]. This is a five-point scale that allows for differentiation between no pain, mild pain, moderate pain, severe pain, and unbearable pain. Postoperative pain assessment was performed on a daily basis for 7 days by direct interview. The patients were followed up prospectively after operation at our outpatient clinic on a monthly basis.

Statistical analysis

All data are presented as mean \pm standard deviation. The 95% confidence intervals (CI) for mortality, morbidity, and major adverse cardiac events (MACE) were calculated using the exact binomial distribution. Postoperative NYHA functional class was compared with preoperative status using a paired *t* test. A value of *p* less than 0.05 was considered significant.

Operative technique

The operations were performed on a beating heart without cardiopulmonary bypass, without full sternotomy, and without touching the aorta. During the operation, the heart rate was controlled pharmacologically with the beta-blocker Sotalol (Bristol-Myers Squibb GmbH & Co., New York, USA). Transesophageal echocardiography was used for all patients to monitor changes in wall motion. The patient was placed in a supine position and prepared as for conventional cardiac surgical procedures. A skin incision was made from the fourth intercostal space to the base of the xiphoid process (7–8 cm). The distal half of the sternum was then divided up to the third rib starting from the bottom, using an oscillating saw, by making a reverse L- or T-shaped division of the sternum (Fig. 1). An ITA retractor (Delacroix-Chevalier, Paris, France) was used to harvest the ITA via a minimal-pedicle technique using electrocautery on a low-level program (Maxium-KLS Martin Group, Tuttlingen, Germany). The ITAs were exposed and harvested almost to the usual extent obtained with full sternotomy. When the radial artery (RA) was used, it was harvested from the left forearm simultaneously with the left ITA

(LITA), using scissors and clips. After all conduits were harvested, the sternum was carefully spread with the sternal retractor (Guidant-Maquet, Maquet, Gettinge Group, Rastatt, Deutschland). The pericardium was opened up to the aortic root and suspended with four stay sutures. Heparin at 1–1.5 mg/kg was given to keep the activated clotting time at around 300 s. The distal part of the conduit was then ligated and divided. A coronary artery stabilizer such as the Acrobat-i device (Guidant-Maquet, Maquet, Gettinge Group, Rastatt, Deutschland) or the Octopus (Medtronic Inc., Minneapolis, MN, USA) was set on the sternal retractor. The stay sutures were then revised and gently pulled upward lifting the LAD to the field. A suction-based epicardial stabilizer was routinely used. The LITA was grafted to the LAD or a diagonal branch or used as a sequential bypass for both vessels. The right ITA (RITA) or left radial artery (LRA) was used as a Y-graft constructed with the LITA. The anastomotic site of the LAD was chosen, and a 4–0 Prolene suture (Ethicon, Johnson & Johnson Medical, Norderstedt, Germany) was passed around proximally and distally to the anastomotic site of the coronary artery using a snare with a Teflon felt pledget. A 5-min test occlusion was undertaken routinely to confirm hemodynamic stability before proceeding with the arteriotomy and grafting, excluding cases of total occlusion of the coronary artery. When hemodynamic instability occurred, an intracoronary shunt (ClearView, Medtronic GmbH, Meerbusch, Germany) was inserted. The distal tourniquet was tightened only in cases with significant coronary backflow. The LAD was opened longitudinally and the proximal suture was snared gently to achieve hemostasis. The LITA–LAD anastomosis was created using the 8–0 Prolene single parachute technique. For the anastomosis on the main RCA, a suction-type stabilizer (Expose-Guidant, Maquet, Gettinge Group, Sweden) was used. The main RCA was opened longitudinally and the radial artery as a Y-graft was then fashioned using the 8–0 Prolene single running suture. For the anastomosis on the right

Herz <https://doi.org/10.1007/s00059-018-4696-0>
© Springer Medizin Verlag GmbH, ein Teil von Springer Nature 2018

I. Martinovic · S. Lindemann · M. Irsusi · J. Mirat · A. Vcev · T. Wittlinger · M. Noutsias

Minimally invasive direct coronary bypass surgery via distal mini-sternotomy. Promising clinical results with anaortic, multivessel, all-arterial technique

Abstract

Background. Minimally invasive direct coronary artery bypass grafting (MIDCAB) was developed to decrease perioperative morbidity, some of which may be related to the use of cardiopulmonary bypass and to cross-clamping of the aorta. We report our initial experience with multivessel MIDCAB via distal mini-sternotomy (DIMS). DIMS is performed to gain access to the left and right internal thoracic arteries and to reach the left anterior descending coronary artery (LAD), diagonal branches, and right coronary artery (RCA).

Methods. Between January 2016 and January 2017, 12 patients with significant coronary artery disease of the LAD and the RCA underwent multivessel, all-arterial MIDCAB

through a distal midline skin incision from the fourth intercostal space to the xyphoid process, with L- or T-shaped division of the sternum. The mean age of the patients was 61.5 ± 5.2 years (range: 52–71 years).

Results. We performed all-arterial revascularization using the left internal mammary artery in 12 patients, the radial artery in ten, and the right internal mammary artery in two patients. The mean number of grafts per patient was 2.08 ± 0.4 (range: 2–3). The mean length of the skin incision was 8.5 ± 1.3 cm (range: 7–11 cm). There was no perioperative ischemia, postoperative bleeding, or arrhythmia events. No postoperative cognitive dysfunction occurred. The mean hospital stay was 5.6 days. No major adverse cardiac events

(MACE) occurred at the 12-month follow-up. At follow-up, all patients were in New York Heart Association class I and there were no wound complications.

Conclusion. Although MIDCAB-DIMS is technically more demanding than conventional procedures and our experience is limited, we conclude that this technique can be used safely in selected patients, with promising 12-month follow-up results.

Keywords

Coronary artery stenosis · Coronary artery bypass grafting · Minimal surgical procedure · Myocardial revascularization · Follow-up

Minimalinvasive direkte koronare Bypass-Operation über eine distale Ministernotomie. Vielversprechende klinische Ergebnisse mit anaortaler komplett arterieller Mehrgefäßtechnik

Zusammenfassung

Hintergrund. Die minimalinvasive direkte Koronararterien-Bypass-Operation („minimally invasive direct coronary artery bypass grafting“, MIDCAB) wurde entwickelt, um die perioperative Morbidität zu senken, denn diese ist möglicherweise z. T. durch die Verwendung der Herz-Lungen-Maschine und das Abklemmen der Aorta bedingt. Die Autoren stellen ihre initialen Erfahrungen mit der Mehrgefäß-MIDCAB über eine distale Ministernotomie (DIMS) dar. Die DIMS erfolgt, um Zugang zur linken und rechten A. thoracica interna zu erhalten und den Ramus interventricularis anterior („left anterior descending coronary artery“, LAD), Diagonaläste sowie die rechte Koronararterie („right coronary artery“, RCA) zu erreichen.

Methoden. Zwischen Januar 2016 und Januar 2017 wurde bei 12 Patienten mit signifikanter koronarer Herzkrankheit (KHK) der LAD und der RCA eine komplett arterielle Mehrgefäß-

MIDCAB über eine Hautinzision in der distalen Mittellinie vom 4. Interkostalraum bis zum Processus xiphoideus mit L- oder T-förmiger Durchtrennung des Sternums durchgeführt. Das Durchschnittsalter der Patienten lag bei $61,5 \pm 5,2$ Jahren (Spanne: 52–71 Jahre).

Ergebnisse. Die Autoren führten die komplett arterielle Revaskularisierung bei 12 Patienten unter Verwendung der linken A. mammaria interna durch, bei 10 mit der A. radialis und bei 2 Patienten mit der rechten A. mammaria interna. Durchschnittlich erhielt ein Patient $2,08 \pm 0,4$ Transplantate (Spanne: 2–3). Die mittlere Länge der Hautinzision betrug $8,5 \pm 1,3$ cm (Spanne: 7–11 cm). Es gab weder Fälle mit perioperativer Ischämie noch postoperativer Blutung oder Arrhythmien. Eine postoperative kognitive Funktionsstörung trat nicht auf. Die mittlere Verweildauer im Krankenhaus betrug 5,6 Tage. Bis zum 12-Monats-Follow-up traten keine schweren

unerwünschten kardialen Ereignisse auf („major adverse cardiac events“, MACE). Bei der Nachuntersuchung waren alle Patienten in Klasse I gemäß New York Heart Association, Wundkomplikationen lagen nicht vor.

Schlussfolgerung. Die MIDCAB-DIMS ist zwar technisch anspruchsvoller als konventionelle OP-Verfahren und die Erfahrung der Autoren begrenzt, doch schlussfolgern die Verfasser, dass diese Technik sicher und mit vielversprechenden 12-Monats-Follow-up-Ergebnissen bei ausgewählten Patienten eingesetzt werden kann.

Schlüsselwörter

Koronararterienstenose · Koronararterien-Bypass-Operation · Minimalinvasive Operationstechnik · Myokardrevaskularisierung · Nachbeobachtung

posterior descending artery (PDA), the acute margin of the heart was displaced cranially by the Expose stabilizer to provide a good exposure of the inferior wall. The anastomotic site of the PDA was chosen and the anastomosis was created with a running 8–0 Prolene suture. When the RA graft was used, a Y-graft

was constructed with either the RITA or LITA with the 8–0 Prolene single running suture. Once the anastomosis was complete, the graft flow was tested using a handheld transit-time ultrasonic flow probe (Medistim VeriQ C, Oslo, Norway) to assist in the detection of technical problems with the anastomo-

sis. Heparin was reversed with a half dose of protamine that was given at the end of the procedure. After insertion of drains—one into the pericardial cavity and one in the pleural space—when opened, the lower sternotomy was closed with sternal wires and soft tissue was closed in layers.

Table 1 Baseline and follow-up clinical characteristics

Age (years)	61.5 ± 5
Male	10
Hypertension	9 (6)
Coronary artery disease, two-vessel	12 (12)
Myocardial infarction	5 (0)
Congestive heart failure	5 (0)
NYHA class II or III	12 (0)
Diabetes mellitus	3 (3)
Renal insufficiency	4 (4)
Liver dysfunction	1 (1)
Peripheral vascular disease	3 (3)
Carotid atherosclerotic disease	2 (2)
Stroke	1 (0)
Smoking	9 (2)
Chronic obstructive pulmonary disease	3 (3)
PCI	3 (0)
Reoperation	0 (0)

NYHA New York Heart Association, PCI percutaneous coronary intervention

Results

A total of 12 patients underwent MIDCAB using a DIMS approach over a 12-month period from January 2016 to January 2017. Neither hemodynamic changes nor transient S-T segment changes on the ECG occurred during the operation. There was no need for extension to a full sternotomy. The mean operative time was 188 ± 45 min (range: 165–260 min). The mean length of the skin incision was 8.5 ± 1.3 cm (range: 7.5–11 cm). Transient atrial fibrillation was not observed. There was no operative or follow-up mortality. There was also no postoperative bleeding requiring either operative revision or blood transfusion. All patients were extubated on the first day of the surgery and their ICU stay was 2 days. In all patients, recovery was rapid and uneventful. On postoperative day 2, both drains were removed from all patients. The median peak of the CK-MB was 23 U/l (range: 12–35 U/l). There were no perioperative neurological cognitive dysfunction events. Maximal pain levels were registered on postoperative day 2. The most pain was reported by patients when coughing and during in-

bed mobilization. The baseline clinical characteristics are listed in **Table 1**. Pain intensity according to the Verbal Rating Scale on postoperative day 2 was mild in ten and moderate in two patients, which was reduced on postoperative day 5 to almost no pain (no pain in eight cases and mild pain in four). At the follow-up examination, NYHA functional class was significantly improved from 2.5 to 1 ($p < 0.0001$; **Fig. 2**).

Discussion

Complex cases with a SYNTAX score of more than 32, diabetes mellitus, and lesions of the left main stem or three-vessel disease should in general not be treated by an ad hoc percutaneous coronary intervention (PCI) but should first be discussed in the heart team [11]. Culprit lesion PCI is usually the first choice in most patients with acute coronary syndrome [11]. If complete percutaneous revascularization is not possible, CABG should be considered by the heart team [11]. The team of cardiac surgeons should include at least one experienced OPCAB surgeon. The advantages of the OPCAB procedure stem from the avoidance of cardiopulmonary bypass, which may result in a reduced rate of postoperative complications such as bleeding, arrhythmia, stroke, renal failure, aortic injury, respiratory failure, and coagulation abnormalities [12, 13].

A large network meta-analysis of over 37,720 patients showed the difference in outcomes between patients undergoing OPCAB and conventional CABG and concluded that the elimination of cardiopulmonary bypass may reduce the risk of short-term mortality, renal failure, atrial fibrillation, bleeding, and length of ICU stay [3]. The authors also reported that the avoidance of aortic manipulation in an OPCAB group (anaortic OPCAB) may decrease the risk of postoperative stroke, especially in patients with a higher stroke risk. Another large meta-analysis of over 19,000 patients showed that OPCAB reduced the risk of death, stroke, and myocardial infarction in higher-risk patients [14]. Some authors emphasize that in the setting of a diseased or porcelain aorta, the avoidance of any aortic

manipulation is the most guaranteed way to reduce the risk of stroke [15, 16].

Our group's initial experience with the special minimally invasive technique for MIDCAB has been described and evaluated for the potential reduction of perioperative morbidity and accelerated postoperative recovery. The number of cases in our study was small since there was a special selection of patients: only patients with double coronary distribution, namely, LAD and RCA disease, were selected for the procedure. All procedures were performed by the same surgeon, who has 20 years of experience with OPCAB and MIDCAB using a LAST approach. Early procedures were limited to the LAST approach through which only the LAD can be grafted [2]. For patients who needed multivessel revascularization, full sternotomy was preferred. Several techniques have been proposed to improve beating heart surgery for patients with multivessel disease without full sternotomy [17, 18]. However, if the anterior small thoracotomy approach is used, access to both the RCA and LAD generally requires two incisions, resulting in incisions with total lengths that are the same or greater than those of a full sternotomy. By contrast, the DIMS approach provides ease of access to both vessels by means of a limited incision and allows for ITA harvesting under direct visualization [8, 19].

The results achieved in this study are similar to those reported in series using the LAST approach, in terms of mortality, major morbidity, and ICU stay [2]. However, the DIMS technique has several significant advantages over the LAST approach for MIDCAB. First, four arterial conduits can be used through a single incision: the LITA, RITA, gastroepiploic artery, and RA as a Y-graft [8]. Myocardial revascularization with these conduits is advantageous not only because of the long-term patency, but also because it enables the “anaortic technique” to be performed. An avoidance of touching the ascending aorta, especially in patients with a calcified aorta, minimizes the risk of perioperative stroke [3, 15, 16]. Harvesting the ITAs through the DIMS technique provides the conventional exposure with which the cardiac surgeon

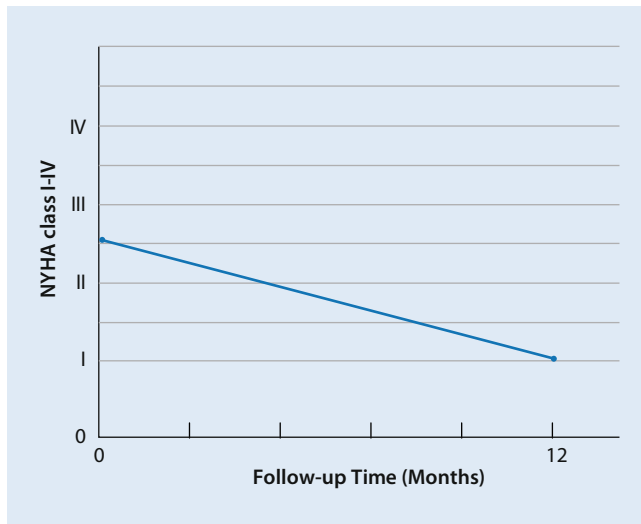


Fig. 2 ◀ New York Heart Association (NYHA) functional class, preoperatively and at 12-month follow-up

is familiar and allows for direct visualization of the field of operation using traditional instruments. Second, there is minimal postoperative wound pain with the DIMS approach. Although this is not a comparative study, we note that some authors have reported that the LAST approach causes significantly more pain in the early postoperative period compared with conventional full sternotomy [10, 20]. Strain caused by mobilization causes bony friction of the sternum in patients with full sternotomy. In particular, when full-sternotomy patients move their arms, they experience intense pain due to friction of the split manubrium sterni because of the sternoclavicular joints. We believe that with our approach, patients experience less pain than with full sternotomy, as the manubrium sterni is intact. Furthermore, Ng and associates [21] demonstrated that wound complications after MIDCAB with the LAST approach were not insignificant. In their study, the wound complication rate with the LAST approach was 9.1%, and this was significantly higher than the rate for median sternotomy. They reported that the difference in morbidity between LAST and median sternotomy could be due to the lack of collateral blood supply to the intercostal muscle. Second, the DIMS approach facilitates easy and rapid extension to a full sternotomy and avoids an additional skin incision in emergency cases in which full access is necessary to establish cardiopulmonary bypass. We did not have to extend any procedure to

a full sternotomy. Moreover, we did not register any cases of PCI or redo-CABG after our procedures.

Conclusion

Our first solid experience with the DIMS approach for MIDCAB demonstrates that it is technically feasible for revascularization of the LAD and the RCA system with the same small incision. This study also shows that a relatively low level of pain and good cosmetic results can be achieved. Although this approach is technically more demanding than conventional procedures, and despite our limited experience, on the basis of our promising 12-month clinical results we conclude that the DIMS technique can be used safely for off-pump, multivessel, anaortic, all-arterial myocardial revascularization.

Corresponding address

I. Martinovic, MD, PhD
 Department of Cardiovascular Surgery, Philipps University of Marburg
 Baldinger Straße 6, 35043 Marburg, Germany
 ivo.martinovic@med.uni-marburg.de

Compliance with ethical guidelines

Conflict of interest. I. Martinovic, S. Lindemann, M. Irsqusi, J. Mirat, A. Vcev, T. Wittlinger, M. Noutsias declare that they have no competing interests.

All procedures performed in studies involving human participants were in accordance with the ethical standards of the institutional and/or national research committee and with the 1964 Helsinki declaration and its later amendments or comparable ethical standards. Informed consent was obtained from all individual participants included in the study.

References

- Benetti FJ, Naselli G, Wood M et al (1991) Direct myocardial revascularization without extracorporeal circulation. Experience in 700 patients. *Chest* 100:312–316
- Calafiore AM, Di Giammarco G, Teodori G et al (1996) Left anterior descending coronary artery grafting via left anterior small thoracotomy without cardiopulmonary bypass. *Ann Thorac Surg* 61:1658–1665
- Zhao DF, Edelman JJ, Seco M, Bannon PG et al (2017) Coronary artery bypass grafting with and without manipulation of the ascending aorta: a network meta-analysis. *J Am Coll Cardiol* 69:924–936
- Benetti FJ, Ballester C, Sani G, Boonstra P, Grandjean J (1995) Video-assisted coronary bypass surgery. *J Cardiac Surg* 10:620–625
- Nataf P, Lima L, Regan M et al (1996) Minimally invasive coronary surgery with thoracoscopic internal mammary dissection: surgical technique. *J Cardiac Surg* 11:288–292
- Shennib H, Bastawasy A, Mack JM, Moll FH (1998) Computer-assisted telemanipulation: an enabling technology for endoscopic coronary artery bypass. *Ann Thorac Surg* 66:1060–1063
- Doty DB, DiRusso GB, Doty JR (1998) Full-spectrum cardiac surgery through a minimal incision: mini-sternotomy (lower half) technique. *Ann Thorac Surg* 65:573–577
- Niinami H, Takeuchi Y, Ichikawa S, Suda Y (2001) Partial median sternotomy as a minimal access for off-pump coronary artery bypass grafting: feasibility of the lower-end sternal splitting approach. *Ann Thorac Surg* 72:1041–1045
- Lichtenberg A, Klima U, Harringer W, Kim PY, Haverich A (2000) Mini-sternotomy for off-pump coronary artery bypass grafting. *Ann Thorac Surg* 69:1276–1277
- Walther T, Falk V, Metz S et al (1999) Pain and quality of life after minimally invasive versus conventional cardiac surgery. *Ann Thorac Surg* 67:1643–1647
- Sinning JM, Welz A, Nickenig G (2016) The heart team in planning and performance of revascularization: ESC guidelines versus clinical routine. *Herz* 41:562–565
- Calafiore AM, Di Giammarco G, Teodori G et al (1998) Midterm results after minimally invasive coronary surgery (LAST operation). *J Thorac Cardiovasc Surg* 115:763–771
- Mangano DT (1990) Perioperative cardiac morbidity. *Anesthesiology* 72:153–184
- Kowalewski M, Pawliszak W, Malvindi PG et al (2016) Off-pump coronary artery bypass grafting improves short-term outcomes in high-risk patients compared with on-pump coronary artery bypass grafting: meta-analysis. *J Thorac Cardiovasc Surg* 151:60–77
- Kowalewski M, Suwalski P, Pawliszak W et al (2016) Risk of stroke with “no-touch”—as compared to conventional off-pump coronary artery bypass grafting. An updated meta-analysis of observational studies. *Int J Cardiol* 222:769–771

16. Misfeld M, Potger K, Ross DE et al (2010) "Aortic" offpump coronary artery bypass grafting significantly reduces neurological complications compared to off-pump and conventional on-pump surgery with aortic manipulation. *Thorac Cardiovasc Surg* 58:408–414
17. Voutilainen S, Verkkala K, Jarvinen A et al (1998) Minimally invasive coronary artery bypass grafting using the right gastroepiploic artery. *Ann Thorac Surg* 65:444–448
18. Grandjean JG, Canosa C, Mariani MA, Boonstra PW (1999) Reversed-J inferior sternotomy for beating heart coronary surgery. *Ann Thorac Surg* 67:1505–1506
19. Wiklund L, Johanson M, Bugge M et al (2000) Early outcome and graft patency in mammary artery grafting of left anterior descending artery with sternotomy or anterior minithoracotomy. *Ann Thorac Surg* 70:79–83
20. Lichtenberg A, Hagl C, Harringer W et al (2000) Effects of minimal invasive coronary artery bypass on pulmonary function and postoperative pain. *Ann Thorac Surg* 70:461–465
21. Ng PC, Chua AN, Swanson MS et al (2000) Anterior thoracotomy wound complications in minimally invasive direct coronary bypass. *Ann Thorac Surg* 69:1338–1341