

The use of an Ultrasound-guided Supraclavicular Brachial Plexus Block in a high risk Patient with Cardiomyopathy

Palković, Barbara; Haršanji Drenjančević, Ivana; Ivić, Dubravka; Kvolik, Slavica

Source / Izvornik: **Periodicum biologorum, 2015, 117, 311 - 314**

Journal article, Published version

Rad u časopisu, Objavljena verzija rada (izdavačev PDF)

Permanent link / Trajna poveznica: <https://urn.nsk.hr/urn:nbn:hr:239:542643>

Rights / Prava: [In copyright](#)/[Zaštićeno autorskim pravom.](#)

Download date / Datum preuzimanja: **2024-11-23**



Repository / Repozitorij:

[Repository UHC Osijek - Repository University Hospital Centre Osijek](#)



The use of an ultrasound-guided supraclavicular brachial plexus block in a high risk patient with cardiomyopathy

BARBARA PALKOVIĆ¹
IVANA HARŠANJI DRENJANČEVIĆ²
DUBRAVKA IVIĆ²
SLAVICA KVOLIK²

¹ General Hospital Vinkovci
Department of Anesthesiology,
Reanimatology and Intensive Care
Zvonarska 57, 32100 Vinkovci, Croatia

² Osijek University Hospital
Faculty of Medicine, University of Osijek
Department of Anesthesiology,
Reanimatology and Intensive Care
Josipa Huttlera 4, 31000 Osijek, Croatia

Correspondence:

Barbara Palković
General Hospital Vinkovci
Department of Anesthesiology,
Reanimatology and Intensive Care
Zvonarska 57, 32100 Vinkovci, Croatia
E-mail: barbara.palkovic@gmail.com

Abstract

With the rapid growth of the elderly population, along with increased comorbidities and greater life expectancy, geriatric surgery has become more frequent and requires careful tailoring of anesthesia technique. Preanesthetic evaluation should concentrate on the identification of age-related diseases and an estimation of physiological reserve. Age-related cardiovascular changes are leading factors impacting perioperative outcomes among elderly patients. The management of a patient with dilated cardiomyopathy, who undergoes a non-cardiac surgery is always a challenge for an anesthesiologist, as this situation is associated with a high mortality rate.

We report a use of the ultrasound guided supraclavicular brachial plexus block in 87-year old woman for revision of wound of left wrist and reposition and immobilization of left forearm and elbow. Her previous medical records revealed that she arterial hypertension, chronic atrial fibrillation with dilated cardiomyopathy and chronic kidney disease, stage II. Postoperatively, she developed respiratory insufficiency.

This case report exemplifies how despite all the measures and precaution we had taken, with choosing anesthesia having only minimal hemodynamic fluctuations and carefully planned and balanced hydration of patient we still had unwanted outcome.

INTRODUCTION

In the last 50 years, the number of people over 65 years of age has tripled in the world. In Europe, they are expected to represent 30% of the population within 40 years (1). With the rapid growth of the elderly population, along with increased comorbidities and greater life expectancy, geriatric surgery has become more frequent and requires careful tailoring of anesthesia technique (2). Aging is a universal and progressive physiologic process characterized by declining in end-organ reserve, decreased functional capacity, increasing imbalance of homeostatic mechanisms, and an increasing incidence of pathologic processes (3). Aging is now viewed as an extremely complex multifactorial process with interaction of various pathways to differing degrees and effect (4). Age is not a contraindication to anesthesia and surgery; however, perioperative morbidity and mortality are greater in elderly than younger surgical patients. Anesthetic risk correlates much better with the presence of coexisting disease than chronological age. Therefore, preanesthetic evaluation should concentrate on the identification of age-related

diseases and an estimation of physiological reserve. Age-related cardiovascular changes are leading factors impacting perioperative outcomes among elderly patients, despite advances in perioperative care cardiac morbidity and mortality remain high ranging from 2-15% depending from the study (5).

Case report

A 87-year-old female patient, with 150 cm of height and 50 kg of weight, was hospitalized under diagnosis of fractured left femur neck, left elbow dislocation and fractured left forearm with open wound on the left wrist after she had fallen at home. Indication for revision of wound of left wrist and reposition and immobilization of left forearm and elbow was set.

Her previous medical records revealed that she arterial hypertension, chronic atrial fibrillation with dilated cardiomyopathy and chronic kidney disease, stage II. She was on treatment with amiodarone, trandolapril, metildigoxine and furosemide.

After admission, the patient's initial laboratory reports were: random blood glucose of 7.9 mmol/L, urea 17.4 mmol/L, creatinine 162 μ mol/L, sodium 140 mmol/L, potassium 3.8 mmol/L, hemoglobin 132 g/l, hematocrit 42.2%, CRP 80.5 mg/L, and blood coagulation were normal. Her chest X-ray revealed enlarged cardiac borders and clear lung fields [Figure 1].

On preanaesthetic examination her heart rate was irregular, presented as atrial fibrillation with an average ventricular response of 80 beats per minute. Systolic and diastolic blood pressures were 150 mmHg and 90 mmHg, respectively. Her respiratory rate was accelerated with jugular retraction and usage of accessory respiration muscles. She was given ASA IVE status on preoperative examination.

After reviewing medical records and patient examination, a supraclavicular brachial plexus block was chosen because it produces minimal effects on the heart rate, blood pressure and contractility of the heart. It was considered as appropriate form of anesthesia according to the planned surgical treatment and subsequent pain treatment. Before the beginning of the procedure, venous access and standard monitoring was established (pulse oximetry, electrocardiography and noninvasive arterial blood pressure monitoring). After aseptic preparations and under ultrasound guidance brachial plexus was identified and 20ml of 0.75% ropivacaine were administered slowly in 2ml increments with gentle aspiration between doses. After completion of the procedure, sensory (warm, cold, touch, pain) and motor (absence of foot mobility) blockade were evaluated in 10 minutes intervals. Visual analogue scale (VAS) was used for pain score recording. A paralysis of the left arm and VAS score 0 was recorded after 40 minutes and complete block was achieved.

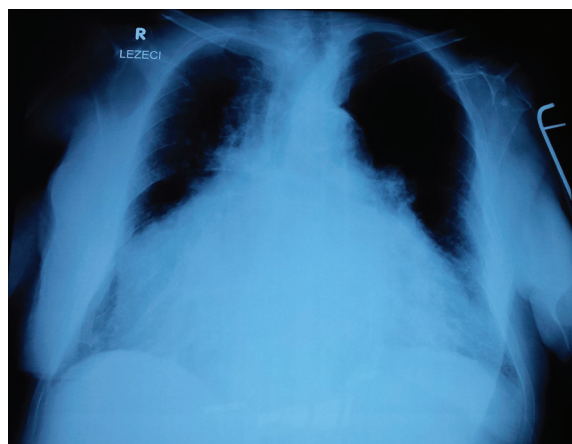


Figure 1. Chest X-ray at the admission in hospital.

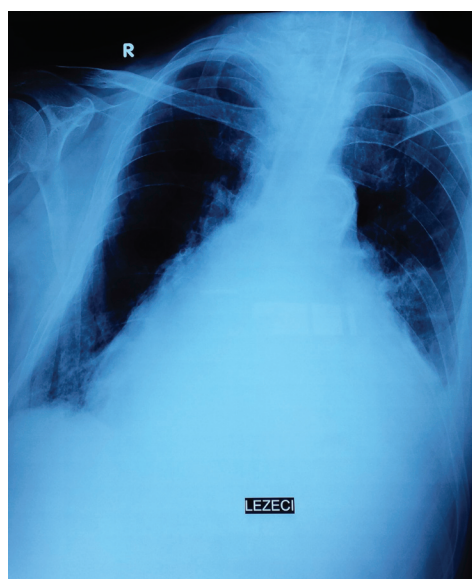


Figure 2. Control chest X-ray at the admission in ICU.

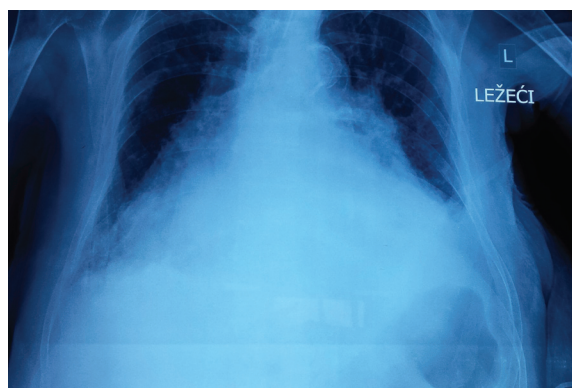


Figure 3. Control chest X-ray after interval of 6 hours from admission in ICU.

After that patient was taken to operation theatre and positioned supine. During the treatment patient had a fall of heart rate to 50/min and atropine 0.5mg was adminis-

tered after what heart rate revert to 80/min. There was no oscillation in blood pressure. The total duration of the surgery interventions were approximately 30 min. At the end of treatment patient become somnolent and respiratory insufficient and was intubated with cuffed endotracheal tube 7.5 mm ID (Internal Diameter). She was admitted to ICU and connected to respirator. Until that moment, from admission in hospital (interval of 6 hours), she received 700ml crystalloid solution.

First few hours after admission patient was hemodynamically unstable and continuous norepinephrine infusion was started in the dose required to attain normotension. Later during that day her neurological condition improved, in the evening she regained consciousness and became communicative. Thereafter, she was switched from SIMV mode to CPAP mode of respiration.

We investigated possible causes of such outcome. Since the peripheral nerve block was performed, two control chest X-rays were done (immediately after the surgery when she was admitted in the ICU, and 6 hours later) [Fig. 2 and 3]. A pneumothorax and iatrogenic paresis of phrenic nerve were excluded, and cardiac decompensation as a cause of patient's respiratory insufficiency and somnolence was suspected. Acute congestive heart failure was confirmed by combination of X-ray and increased proBNP 6781 g/L (normal value for patients over 75 years is under 450g/L).

During the next day patient's respiratory function improved and she was disconnected from respirator and extubated. A motor function of the left recovered within 14 hours after the local anesthetic injection. The patient reported that sensory block was present for 4 more hours after that (overall 18 hours). On the day after, she was discharged to surgical ward with normal blood pressure and respiratory function. The later was confirmed by blood gas analysis.

On the same day, in the afternoon, patient was readmitted to ICU because of repeated episode of respiratory insufficiency. Her saturation as measured by pulse oximetry, with 6L of 100% oxygen applied was 82%. She was intubated and assisted ventilation was continued. The control chest X-ray that was done has confirmed repeated congestive heart failure. In the laboratory reports an increased value of CRP (192.1 mg/L) was registered, the rest of findings didn't show any significant deviations. A tracheal aspirate for analysis was taken, and *Enterobacter* species was confirmed. A specific antibiotic therapy according to antibiogram was started. Despite all supportive measures, her physical condition deteriorated and she died on 19th day of hospitalization.

DISCUSSION

Anesthetic management of patients with cardiomyopathy, with reduced systolic function, is challenging and it may be associated with high mortality. It is commonly complicated by congestive heart failure and malignant

arrhythmias. Dilated cardiomyopathy is defined as a deterioration of the function of the myocardium, either caused by left ventricular or biventricular dilatation or due to impaired systolic function of one or both ventricles, with impaired ventricular contractility. The anesthesiologist should have a thorough knowledge on its pathophysiology, clinical features, diagnostic evaluations and the treatment modalities. This has to be accompanied by a careful planning to provide safe anesthesia. Choice of anesthesia should be planned and it should be aimed to reduce hemodynamic fluctuations (6). The use of peripheral nerve blocks in the elderly is a rational approach for appropriate surgery as it has minimal influence on hemodynamics (7).

All investigation that we took in our patient to define cause of respiratory insufficiency suggested that it was caused by acute congestive heart failure as a complication of severe cardiomyopathy. Our suspicion was supported with the fact that it occurred again shortly after discharge from ICU.

Studies show that overall mortality and morbidity is higher in emergency anesthesia than in elective anesthesia and that ASA physical status correlates with overall mortality and morbidity, regardless of etiology, as well. For the patients with ASA IVE physical status the incidence of all critical events totally attributable to anesthesia is 14.85% and the overall mortality rate totally attributable to anesthesia is 6.60% (8).

This case confirms that despite all the measures and precautions that were taken, with choosing anesthesia aimed to reduce haemodynamic fluctuations, with careful planning and balancing hydration of patient, we still may have unwanted complications.

CONCLUSION

The elderly population is the fastest growing part of the population in the developed world. Aging increases the probability of a person to undergo surgery. It alters both pharmacokinetic and pharmacodynamic aspects of anesthetic management (9). Anesthesia planning, preoperative assessment, optimizing cardiac status and medical management, formulating the good anesthetic plans and postoperative monitoring, prompt diagnosis and management of complications have to be considered to minimize the incidence of critical events and the mortality rate.

REFERENCES

1. BETTELLI G 2011 Preoperative evaluation in geriatric surgery: comorbidity, functional status and pharmacological history. *Minerva Anestesiol* 77: 637-46
2. YANG R, WOLFSON M, LEWIS M C 2011 Unique Aspects of the Elderly Surgical Population: An Anesthesiologist's Perspective. *Geriatr Orthop Surg Rehabil* 2(2): 56-64
3. WEINERT B T, TIMIRAS P S 2003 Invited review: Theories of aging. *J Appl Physiol* 95: 1706-1716

4. HOLLIDAY R 2006 Aging is no longer an unsolved problem in biology. *Ann N Y Acad Sci* 1067: 1-9
5. MANGANO D T 1990 Perioperative cardiac morbidity. *Anesthesiology* 72(1): 153-84
6. KUMAR K P, JAGADESH G 2014 Anaesthetic Management of a Patient with Dilated Cardiomyopathy for Fracture Femur Surgery-A Case Report. *J Clin Diagn Res* 8(3): 172-173
7. THIAGRARAJAH P H, THIAGARAJAH S, FROST E 2009 Anaesthetic considerations in patients with cardiomyopathies. *Middle East J Anaesthesiol* 20(3): 347-354
8. IRITA K, KAWASHIMA Y, TSUZAKI K, IWAO Y, KOBAYASHI T, SEO N, GOTO Y, MORITA K, SHIRAISHI Y, NAKAO Y, TANAKA Y, TOSAKI Y, DOHI S, OBARA H Perioperative mortality and morbidity in the year 2000 in 502 Japanese certified anesthesia-training hospitals: with a special reference to ASA-physical status-report of the Japan Society of Anesthesiologists Committee on Operating Room Safety. *Masui* 51(1): 71-85
9. KANONIDOU Z, KARYSTIANOU G 2007 Anesthesia for the elderly. *Hippokratia* 11(4): 175-177