

# Integrity of gut Mucosa During Anaesthesia in Major Abdominal Surgery

---

**Gulam, Danijela; Dmitrović, Branko; Kvolik, Slavica; Barbić, Jerko; Zibar, Lada; Kovačić, Damir**

*Source / Izvornik:* **Collegium antropologicum, 2011, 35, 445 - 451**

**Journal article, Published version**

**Rad u časopisu, Objavljena verzija rada (izdavačev PDF)**

*Permanent link / Trajna poveznica:* <https://um.nsk.hr/um:nbn:hr:239:105605>

*Rights / Prava:* [In copyright](#)/[Zaštićeno autorskim pravom.](#)

*Download date / Datum preuzimanja:* **2024-07-22**



*Repository / Repozitorij:*

[Repository UHC Osijek - Repository University Hospital Centre Osijek](#)

# Integrity of Gut Mucosa during Anaesthesia in Major Abdominal Surgery

Danijela Gulam<sup>1</sup>, Branko Dmitrović<sup>2</sup>, Slavica Kvolik<sup>1</sup>, Jerko Barbić<sup>3</sup>, Lada Zibar<sup>3</sup> and Damir Kovačić<sup>4</sup>

<sup>1</sup> »J. J. Strossmayer« University, Osijek University Hospital Center, Department of Anaesthesiology and Intensive Care Unit, Osijek, Croatia

<sup>2</sup> »J. J. Strossmayer« University, Osijek University Hospital Center, Department of Pathology and Forensic Medicine, Osijek, Croatia

<sup>3</sup> »J. J. Strossmayer« University, Osijek University Hospital Center, Clinical Department of Internal Medicine, Osijek, Croatia

<sup>4</sup> »J. J. Strossmayer« University, Osijek University Hospital Center, Clinical Department of Surgery, Osijek, Croatia

## ABSTRACT

*The aim of the study was to examine a perfusion and integrity of small bowel in 60 subsequent patients during the major open abdominal surgery which lasted from 2 to 7 hours. Two samples of the intestinal mucosa were removed: at the beginning, and at the end of the surgical procedure in general anaesthesia. A mucosal injury was classified into 4 grades. pH, PCO<sub>2</sub> and lactate level were measured in the blood samples from the arterial and mesenteric vein in one hour time intervals. The changes of intestinal mucosa were found in 31 patients (51.7%): in 19 patients (31.7%) grade 1 changes were recorded, in 10 patients (16.7%) grade 2, and in 2 patients (3.3%) grade 3. Grade 4 lesions were not recorded. There was a statistically significant correlation between grades of the mucosal damage and the surgery duration ( $p=0.001$ ). Analysis during the one hour intervals showed that there was no exact time point when the significant aggravation of the pathohistological changes in intestinal mucosa occurred. However, when patients were allocated into two subgroups with surgical procedures lasting less than 4 hours and more than 4 hours, there was a statistically significant difference in the grades of mucosal damage between subgroups ( $p<0.05$ ). More biopsies without pathohistological changes were observed in the patients whose procedure duration was  $< 4$  hours. A significantly higher lactate concentrations in arterial and mesenteric venous blood were observed in the patients with pathohistological changes at 6 hours time point as compared to 2 hour time point in the patients without pathohistological changes ( $p<0.05$ ). During the open abdominal surgery in general anaesthesia, the length of the procedure influences the grade of the intestinal mucosa injury. Deterioration of the pathohistological findings in the intestinal mucosa correlates with high lactate blood level, suggesting that the cause of these changes may result from tissue hypoxia.*

**Key words:** *intestinal mucosa, anaesthesia, abdominal surgery, anoxia*

## Introduction

Mucosa of the small bowel is the central organ in the pathophysiology of the shock, trauma, systemic inflammatory response syndrome (SIRS) and sepsis<sup>1,2</sup>. The relationship between gut mucosal hypoperfusion and those events has been very well established in the last two decades. From the first theory of bacterial translocation<sup>3</sup> it is well known that efforts preserving gut perfusion and integrity lead to better survival of critically ill patients. This concept evolved through Deitch hypothesis on the development of multiple organ dysfunction syndrome (MODS) in a condition of low gut perfusion, consequent

gut barrier injury, bacteria translocation and releasing endotoxin and cytokines in blood stream to the development of inflammatory response and other organs dysfunction<sup>4</sup> to »one hit«<sup>5</sup>, »two hit«<sup>6</sup> theories. The innate immune system detects »signals of dangers«: microbes and their toxins as exogenous signals<sup>7,8</sup> and endogenous danger signals after severe injury<sup>9</sup>. An innate immune host response through extracellular and intracellular pattern recognition receptors (PRRs) as a »molecular network« are the results of the innate immune system defence and proinflammatory cytokines release<sup>10</sup>.

Many methods for evaluating gut ischemia, focusing on the gut perfusion and integrity, have been developed during past years: classical gastric tonometry<sup>11–14</sup>, semi-continuous monitoring of gastric mucosal-to-end-tidal PCO<sub>2</sub> difference<sup>15</sup> and continuous intramucosal PCO<sub>2</sub> measurement in the ileum<sup>16</sup> and in the peritoneal cavity<sup>17</sup>. Measurement of the lactate concentration in the gut hypoperfusion state was tested in numerous studies<sup>18</sup>. In low perfusion state, hyperlactemia is a product of increased lactate production and reduced liver ability for lactate degradation<sup>19</sup>. Hyperlactemia was the most reliable marker of the tissue hypoxia and the most important laboratory finding in the tissue acidosis<sup>20,21</sup>. Other methods of hepato-splanchnic region, monitoring critically ill patients are, practically impossible without surgery and are currently used exclusively for clinical research: pulsed Doppler ultrasound flowmetry of the portal blood flow<sup>22</sup>, mucosal laser Doppler flowmetry<sup>23</sup> and remission spectrophotometry<sup>24</sup>.

Surgical manipulation of the gut elicits an inflammatory cascade within the intestinal smooth muscle with an activation of resident macrophages and a prolonged infiltration of neutrophils, monocytes and mast cells. They all produce cytokines: tumour necrosis factor alpha (TNF $\alpha$ ), interleukin IL1 $\beta$  and interleukin IL6<sup>25</sup>. The extent of surgical trauma is critical for the degree and duration of immune function deterioration<sup>26,27</sup>. Compromised mesenteric blood flow gives rise to the significant metabolic and histological changes. These local changes could not be easily detected. Knichwitz and co-workers observed metabolic and histology changes of the gut mucosa in provoked hypoperfusion state in the study on 12 anesthetized pigs<sup>16</sup>. The authors determined lactate concentration, pH, PCO<sub>2</sub>, PO<sub>2</sub> and bicarbonate concentration in arterial, mesenteric venous, portal venous, hepatic venous and pulmonary arterial blood. They also examined the gut histological changes at the end of the experiment on pigs. The mucosal low perfusion and hypoxia caused anaerobic metabolism with consequent high lactate production and gut mucosal cellular injury. Histological grading of the mucosal injury showed severe ischemic damage (grades 3 and 2) in the jejunum and ileum in all animals in the low gut perfusion state<sup>16</sup>.

An aim of the present study was to confirm the hypothesis that the perfusion disorder and consequent histological damage of the gut was already present during anaesthesia in major abdominal surgery. We hypothesized that a grade of mucosal injury depends on the procedure length. Therefore the concentrations of the pH, PCO<sub>2</sub> and lactate in arterial and mesenteric venous blood were examined during the different procedure lengths. We also tried to correlate pH, PCO<sub>2</sub>, lactate production and the grade of histological changes observed during the various length treatments.

## Subjects and Methods

The study was prospectively conducted over a period of 3 years in the Clinical Hospital Osijek, Croatia. After institutional Ethical Committee approval and patients' informed consent were obtained, 60 consecutive patients (21–80 years, mean age 58 $\pm$ 12 yr), 44 men and 16 women, undergoing elective major surgical procedures were studied. The inclusion criterion was a major abdominal surgery (digestive tract malignancies) with an expected duration of surgery of at least 2 hours. For analyses of correlations between the grade of mucosal damage and the procedure durations, groups were formed according to the procedure duration –2–7 hours (Table 1). Post hoc analysis was performed for evaluation of differences in the grades of the mucosal damage between group of procedure duration <4 hours and group of procedure duration  $\geq$ 4 hours. Subsequently, evaluation of differences in pH, PCO<sub>2</sub> and lactate concentrations, in the patients with and without pathohistological changes was performed. Those laboratory values in two groups of patients were analysed in the one hour intervals, starting from the second hour of the procedure. Finally, differences in pH, PCO<sub>2</sub> and lactate concentrations were analysed between the groups divided on: group with and group without histopathology changes but with final parameter values respectively to the time of the second mucosa biopsy.

The exclusion criteria for this study were age <18 yr and presence of the portal hypertension (preoperative Colour Doppler Imaging evaluation). Most patients were ASA II (n=25) and ASA III (n=30) physical preoperative

**TABLE 1**  
PERIOPERATIVE CLINICAL CHARACTERISTICS OF THE PATIENTS (N=60)

Procedure duration (hours)	2	3	4	5	6	7	Total
Number of patients	10	20	11	8	8	3	60
Sex ratio (M/F)	7/3	11/9	8/3	8/0	7/1	3/0	44/16
Type of the malignancy							
Colonic cancer	8	7	4	3	1	1	24
Pancreatic cancer		1	2	2	4	2	11
Ventricular cancer		7	5	2	1		15
Oesophageal cancer	1	2		1	2		6
Hepatic cancer	1	3					4

status. All patients received a standardized pre-medication consisted of midazolam 3–5 mg i.v. 30–60 minutes prior to the induction into the anaesthesia. Anaesthesia was induced with i.v. propofol 2 mg kg<sup>-1</sup> and fentanyl 2 µg kg<sup>-1</sup>. Rocuronium 0.7 mg kg<sup>-1</sup> was given for muscle relaxation and tracheal intubation. Anaesthesia was maintained with isoflurane at 1–1.5 minimal alveolar concentration (MAC) in the nitrous oxide and oxygen 50% along with fentanyl and rocuronium, as required. Perioperative antibiotic prophylaxis consisted of cefazolin 1 g, 1 hour before the procedure and another two doses repeated every 8 h. Hypothermia protection was maintained with Hotline fluid or blood warmer and electric gum blanket under complete body. Gut protection during surgery was maintained by sheathing of the intestine with warm wet sheets. No need for inotropic medication to maintain an arterial blood pressure in normal range was required. Blood pressure was maintained with colloid and crystalloid solutions according to the CVP (central venous pressure) values and patient's clinical presentation. Anaesthesia was performed by the same anaesthesiologist, researcher in this study. The same surgeon performed all surgical procedures. After induction in anaesthesia the radial arterial catheter was placed for obtaining blood samples. Shortly after the surgery started, during the first hour of surgery, a surgeon introduced central venous catheter (Vygon, 4.2 Fr) in the superior mesenteric vein through peripheral mesenteric vein. Blood samples from the mesenteric vein were obtained during the course of the surgery. During the surgery, two samples of the intestinal mucosa were removed: T<sub>0</sub> at the beginning of the procedure, and T<sub>N</sub> at the end (N = treatment duration in hours – 2 to 7 hours). The samples were analysed by a light microscopy with magnification 20–400x. All the biopsies were examined in 3–6 visual plains. The lesions of the intestinal mucous membrane were classified into 4 grades according to the published research on laboratory animals as presented in the Table 2.

### Blood sampling

Blood samples for determination of the biochemical parameters of hypoperfusion (pH, PCO<sub>2</sub>, lactate) were collected and analysed from arterial and mesenteric venous blood at the beginning of the procedure and in 1 hour intervals depending on the procedure duration (T<sub>2</sub>, T<sub>3</sub>, T<sub>4</sub>, T<sub>5</sub>, T<sub>6</sub> or T<sub>7</sub>).

**TABLE 2**  
CLASIFICATION OF THE PATHOHISTOLOGICAL CHANGES OF THE GUT MUCOSA

Grade	Villous epithelium	Mucosa damaged Lamina propria
0	no injury	no injury
1	no injury	isolated hemorrhage
2	lifting of the villous epithelium	isolated hemorrhage
3	damaged villi	hemorrhage
4	damaged villi	ulcerations, necroses

### pH, PCO<sub>2</sub>, and lactate determination

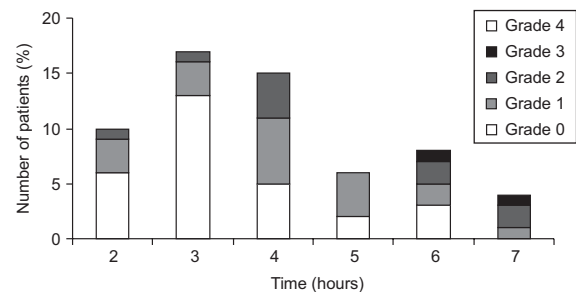
The quantity of blood was 1 mL per sample, thus from 9–24 mL depending on the procedure duration. During analysis, correction factors were considered like actual core temperature, percentage of oxygen in the inspiratory gas mixture and actual haemoglobin concentration. Analyses were performed on Nova Biomedical, »Stat Profile M« analyser by ion selective electrodes for PCO<sub>2</sub> (Severinghaus electrode) and pH (hydrogen glass electrode) determination. Lactate concentration was measured amperometrically using enzymatic electrode.

### Statistical analysis

The data were analysed with statistical programme package SPSS 15.0 for Windows Evaluation Version. Mean values were expressed as arithmetic mean value with standard deviation for normal variable distribution and as median with range for the distribution different from normal. Spearman's correlation analysis was calculated for the gut mucosal sample grade and the time of the procedure length. Differences between two independent samples were compared using the Student t-test for parametric and the Mann-Whitney U-test for nonparametric data. Parametric data were analyzed using ANOVA test and nonparametric data using Kruskal-Wallis if more than two independent samples were compared. Post hoc analysis was performed by the Scheffe's test for parametric and the Mann-Whitney U-test for nonparametric data.  $p < 0.05$  was considered as significant.

### Results

The lesions of the second intestinal mucosal biopsy as described in the Table 2, were classified into 4 grades according to the published animal studies<sup>16</sup>. After the pathohistological analysis was carried out in samples of the intestinal mucosa, no lesions were found in the biopsies taken at the beginning of the surgery (T<sub>0</sub>) in the 60 consecutive patients undergoing open abdominal surgery. In the second sample (T<sub>N</sub>, N=2 to 7 hours) removed at the



**Fig. 1.** The distribution of patients according to the time of the second intestinal biopsy (x-axis) and observed intestinal damage. A total number of patients in the each particular duration of surgery are presented on the y-axis. See that in the 70% of patients whose surgery lasted for 4 hours and longer the intestinal mucosa presents various degree of damage as compared to only 30% in the patients with mean duration of surgery of <4 hour.



**TABLE 2**  
CLASIFICATION OF THE PATHOHISTOLOGICAL CHANGES OF THE GUT MUCOSA

Grade	Villous epithelium	Mucosa damaged Lamina propria
0	no injury	no injury
1	no injury	isolated hemorrhage
2	lifting of the villous epithelium	isolated hemorrhage
3	damaged villi	hemorrhage
4	damaged villi	ulcerations, necroses

end of the procedure, the changes of intestinal mucosa were found in 31 patients (51.7%). Changes observed were grade 1 in 19 (31.7%) patients, grade 2 in 10 (16.7%) patients, and grade 3 in 2 (3.3%) patients. Grade 4 lesions of the intestinal mucosa were not observed in any sample (Figure 1).

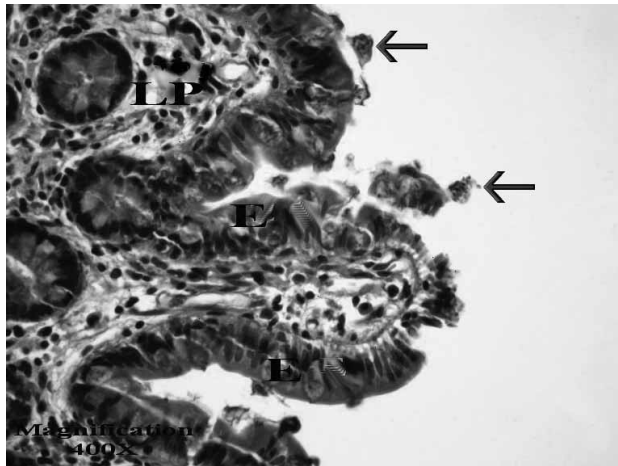


Fig.2. Detachment of the epithelial cells from the tip of the villus. Grade 1, time T<sub>7</sub>, HE - hematoxylin - eosin, E - Epithelium, LP - Lamina propria.

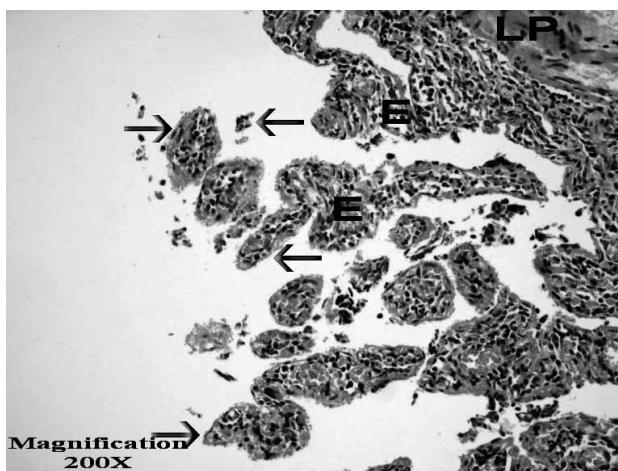


Fig.3. Denuded intestinal villi. Grade 3, time T<sub>4</sub>, HE - hematoxylin - eosin, E - Epithelium, LP - Lamina propria.

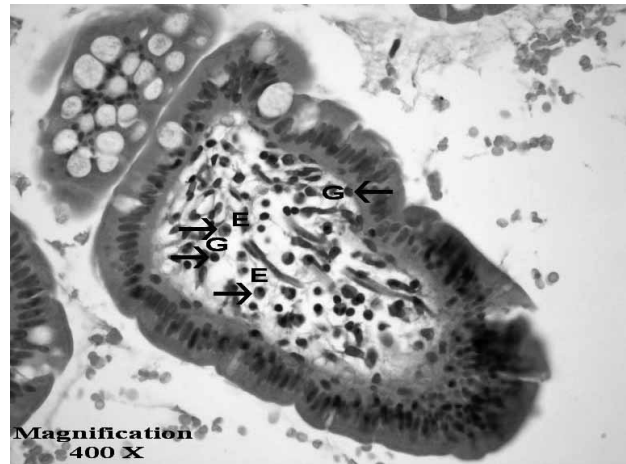


Fig.4. Appearance of the small granulocyte and eosinophils aggregates in blood vessels of the Lamina propria. Grade 3, time T<sub>4</sub>, HE - hematoxylin - eosin, E - eosinophil, G - granulocyte.

The earliest form of the gut epithelial damage was found in 19 patients. These changes were presented as a detachment of the group of epithelial cells from the basal membrane from the tip of the villi (Figure 2). In more profound damage denuded intestinal villi were found, presented in 12 patients (Figure 3). As the damage progressed changes were present in the lamina propria. In the course of that process small granulocyte and eosinophilic aggregates in blood vessels appeared (Figure 4), with margination of the granulocytes in the blood vessels (Figure 5) and finally with submucosal haemorrhage, varying from minimal (Figure 6) to extensive (Figure 7).

The Spearman correlation between observed changes and the time of the second intestinal biopsies was statistically significant ( $\rho=0.331$ ,  $p=0.001$ ,  $n=60$ ). Histopathological changes detected and classified into 3 grades (1–3), were usually found in patients whose the second biopsy was removed later, after more hours of the proce-

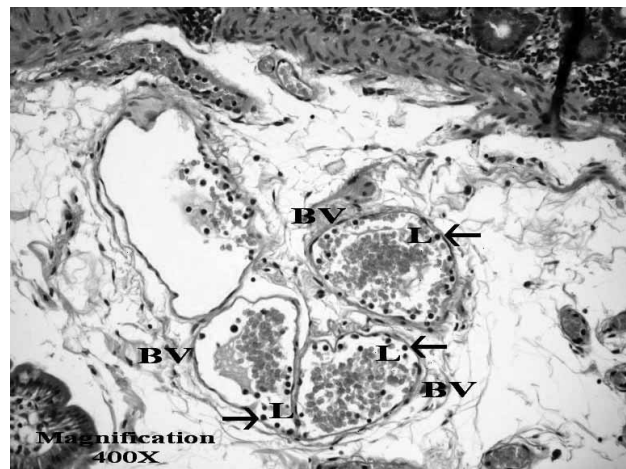


Fig.5. Margination of the granulocytes in the blood vessels of the Lamina propria. Grade 1, time T<sub>7</sub>, HE - hematoxylin - eosin, L - leucocytes, BV - blood vessel.

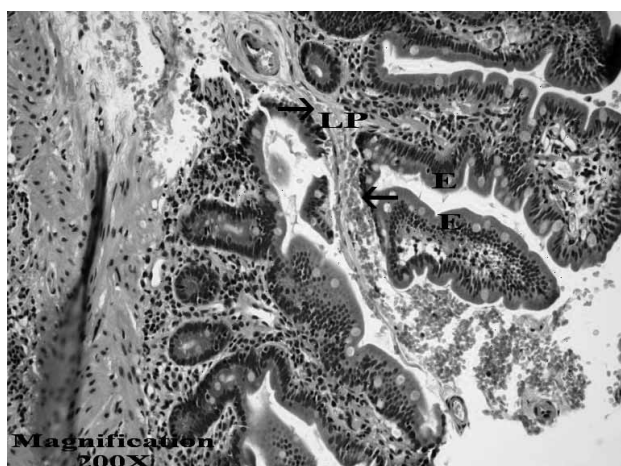


Fig.6. Minimal submucosal haemorrhage. Grade 1, time T<sub>7</sub>, HE – hematoxylin – eosin, E – Epithelium, LP – Lamina propria.

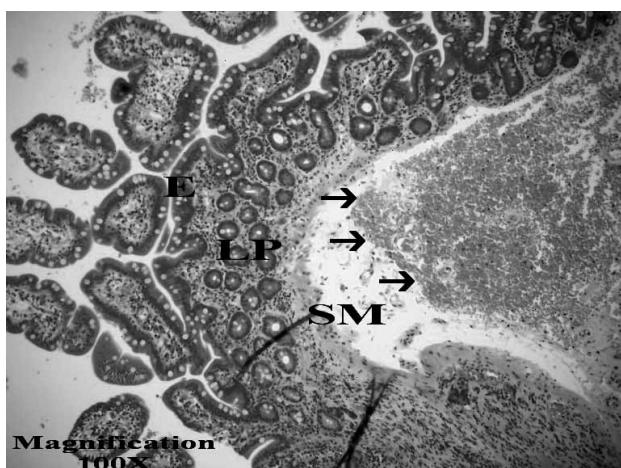


Fig.7. Extensive submucosal haemorrhage. Grade 3, time T<sub>6</sub>, HE – hematoxylin – eosin, E – Epithelium, LP – Lamina propria, SB – submucosis.

dure. To approve the exact time point when the aggravation of the pathohistological changes possibly occurs, we analysed grades of histopathology changes throughout one hour time intervals: grades after 2 and 3 hours ( $z=0.026$ ,  $p=0.0983$ ), between 3 and 4 hours ( $z=-0.445$ ,  $p=0.699$ ), between 4 and 5 hours ( $z=-1.380$ ,  $p=0.168$ ), between 5 and 6 hours ( $z=-0.110$ ,  $p=0.912$ ) between 6

and 7 hours ( $z=-1.157$ ,  $p=0.279$ ). Such a comparison revealed no exact time point when the significant aggravation of the pathohistological changes in intestinal mucosa occurred. However, post hoc analysis of the grades of the pathohistological changes between two subgroups, first with duration <4 hours and the second subgroup, duration  $\geq 4$  hours, confirmed statistically significant difference ( $z=-2.060$ ,  $p=0.039$ ). The group of patients in the procedure duration less than 4 hours had more biopsy samples without pathohistological changes, 70.4% whereas only 30.3% of the patients in the  $\geq 4$  hours subgroup had no mucosal damage.

There were no differences in pH, PCO<sub>2</sub> and lactate concentrations between two subgroups. In the subsequent analysis the values of pH, PCO<sub>2</sub> and lactate concentration were compared between the patients with ( $n=31$ ) and without pathohistological changes ( $n=29$ ). This analysis showed statistically significant differences only for lactate concentration, both in arterial and in mesenteric vein blood samples, after 2 and 6 hours of the procedure duration (Table 3). The differences in pH, PCO<sub>2</sub> and lactate concentrations between the patients with and without pathohistological changes, but with final parameters values, those at the time of the second mucosa biopsies, were statistically significant also only for arterial and mesenteric vein lactate concentrations (Table 4).

### Discussion and Conclusion

This study confirmed that pathohistological changes in the small bowel mucosal integrity occur during the anaesthesia and open abdominal surgery in various length procedures. We have registered the occurrence of intraoperative mucosal integrity impairment. To the best of our knowledge, this is the first study confirming such pathohistological changes in the human small bowel mucosal samples removed intraoperatively and published in the relevant literature. All the pathohistological studies, confirming intestinal mucosal damage, until now were performed on experimental animal models under generated low perfusion states<sup>16</sup>. Our study showed that 29 (48.3%) patients had no pathohistological changes in the mucosal biopsy at the end of the procedure. Different grades of intestinal mucosal changes were found in more than 50% of the patients. Furthermore, in the present study the correlation between the grade of the mucosal

TABLE 3  
DIFFERENCES IN THE LACTATE CONCENTRATIONS BETWEEN THE GROUP WITH AND THE GROUP WITHOUT PATHOHISTOLOGICAL CHANGES

Parametar	Concentration	Time	Number of patients	Difference	Validity of test	p
alac	mmol/L	T2	31–29	2.0 (0.4–8.3) vs. 1.1 (0.2–2.9)	$z=-3.254$	0.001
mlac	mmol/L	T2	31–29	2.2 (0.6–10.2) vs. 1.3 (0.5–3.0)	$z=-2.667$	0.008
alac	mmol/L	T6	8–3	4.3±1.6 vs. 1.8±0.7	$t=3.091$	0.013
mlac	mmol/L	T6	8–3	4.6±1.6 vs. 2.2±0.9	$t=2.980$	0.015

alac – arterial lactate, mlac – mesenteric venous lactate



**TABLE 4**  
DIFFERENCES IN THE FINAL LACTATE CONCENTRATIONS BETWEEN THE GROUP WITH AND THE GROUP WITHOUT PATHOHISTOLOGICAL CHANGES

Parameter	Concentration	Number of patients	Difference	Validity of test	p
alac	mmol/L	31–29	2.8 (0.5–8.9) vs. 1.4±0.7	z=−3.518	<0.001
mlac	mmol/L	31–29	2.9±2.0 vs. 1.8±0.8	t=0.949	0.005

alac – arterial lactate, mlac – mesenteric venous lactate

damage and the procedure duration is well established ( $p=0.001$ ). More profound pathohistological changes were observed in the long lasting surgical procedures. No precise moment of the mucosal damage aggravation was found. After the patients were allocated in the subgroup of procedure duration <4 hours and subgroup of procedure duration  $\geq 4$  hours, we found more biopsies with no changes in shorter procedure patients, whereas more pathological specimens were removed from  $\geq 4$  hours patients ( $p<0.05$ ). In the same populations no significant differences were found in pH,  $PCO_2$  and lactate values.

Pathohistological changes are the result of progressive accumulation of hypoxic changes. To confirm which laboratory parameter had the best correlation with the degree of pathohistological changes, patients with and without changes were analyzed. The differences between patients with and without pathohistological changes were significant only in respect to the lactate production after 2 and 6 hours of the procedure. High lactate production is a result of gradual transition of aerobic metabolism to anaerobic. It was registered in systemical arterial blood and local or mesenteric venous blood samples, and it correlates with pathohistological changes in intestinal mucosa. There are numerous studies investigating pH,  $PCO_2$  and lactate concentrations as parameters of low perfusion state and consequent hypoxia occurrence. All of them argue for the pH,  $PCO_2$  and lactate concentration as reliable markers of tissue hypoxia<sup>28–31</sup>.

The main disadvantage of this study was that it presents no follow up data in the postoperative period, during

patients ICU stay. Therefore, the influence of pathohistological gut mucosal changes detected on morbidity and mortality during postoperative period cannot be discussed. New well designed studies are needed to evaluate correlation between the duration of the anaesthesia and abdominal surgical procedures with SIRS and sepsis occurrence in the early postoperative period.

The gut mucosa hypoperfusion, permeability and integrity disorders are conditions related to shock, trauma, Systemic Inflammatory Response Syndrome (SIRS) and sepsis<sup>1,2</sup>. Because of the small bowel position, methods for functionality and integrity evaluation in human body are difficult<sup>11–16,22–24</sup>. Accordingly to the results of this study it can be emphasized that during the anaesthesia and surgery on open abdomen, the length of the procedure influences the grade of the intestinal mucosal injury. Aggravation of the pathohistological changes in intestinal mucosa correlates with high lactate blood level ( $p<0.001$ ), proving that the cause of these changes is the result of the tissue hypoxia. Criterion for the preservation of the perfusion and integrity of the gut mucosa has not been determined yet. Attention to the preserving of small bowel perfusion and integrity has to be undertaken intraoperatively using general supportive procedures. A careful maintenance of systemic blood pressure, haemoglobin concentration, body temperature, correction of metabolic acidosis, must be accompanied by minimizing surgeon's mechanical trauma to the small bowel, protection by sheathing of the intestines, especially during anaesthesia and open abdominal surgery lasting for a longer time periods.

## REFERENCES

- BOLT J, Crit Care, 6 (2002) 52. — 2. MOKART D, MERLIN M, SANNINI A, BRUN JP, DELPERO JR, HOUVENAEGHEL G, MOUTARDIER V, BLACHE JL, Br J Anaesth, 94 (2005) 767. — 3. KOH IH, LIBERATORE AM, MENCHACA-DIAZ JL, RUIZ-SILVA M, VILELA-OLIVEIRA L, WATANABE AY, SALOMAO R, FAGUNDES-NETO U, SILVA RM, Endocr Metab Immune Disord Drug Targets, 6 (2006) 143. — 4. BAUE AE, Shock, 26 (2006) 438. — 5. GROTZ MR, DEITCH EA, DING J, XU D, HUANG Q, REGEL G, Ann Surg, 229 (1999) 478. — 6. SAADIA R, SCHEIN M, J Accid Emerg Med, 16 (1999) 163. — 7. MEYLAN E, TSCHOOP J, KRIN M, Nature, 442 (2006) 39. — 8. KARIN M, LAWRENCE T, NIZET V, Cell, 124 (2006) 823. — 9. PATERSON H, MURPHY T, PURCELL E, SHELLEY O, KRYNOVICH SJ, LIEN E, MANNICK JA, LEDERER JA, J Immunol, 171 (2003) 1473. — 10. SANSONETTI PJ, Nat Immunol, 7 (2006) 1237. — 11. HEARD SO, Chest, 123 (2003) 469S. — 12. PALIZAS F, DUBIN A, REGUEIRA T, BRUHN A, KNOBEL E, LAZZERI S, BAREDES N, HERNANDEZ G, Crit Care, 13 (2009) R44. — 13. RANNA A, ROZENFELD MK, DISHART MK, TONNESSEN TI, SCHLICHTIN R, J Appl Physiol, 81 (1996) 1834. — 14. JAKOB SM, PARVIAINEN I, RUOKONEN E, KOGAN A, TAKALA J, Shock 29 (2008) 543. — 15. LEBUFFE G, ONIMUS T, VALLET B, Eur J Anaesthesiol, 20 (2003) 147. — 16. KNICHWITZ G, ROTKER J, MOLLHOFF T, RICHTER KD, BRUSSEL T, Crit Care Med, 26 (1998) 1550. — 17. KNICHWITZ G, BRUSSEL T, REINHOLD P, SCHAUMAN F, RICHTER KD, VAN AKEN H, Anesth Analg, 91 (2000) 1182. — 18. CALVETE JO, SCHONHORST L, MOURA DM, FRIEDMAN G, Rev Assoc Med Bras, 54 (2008) 116. — 19. KAPLAN LJ, KELLUM JA, Crit Care Med, 32 (2004) 1120. — 20. JAKOB SM, TENHUNEN JJ, LAITINEN S, HEINO A, ALHAVA E, TAKALA J, Am J Physiol Gastrointest Liver Physiol, 280 (2001) G819. — 21. THIRD EUROPEAN CONSENSUS CONFERENCE IN INTENSIVE CARE MEDICINE, Am J Respir Crit Care Med, 154 (1996) 1573. — 22. LEVY RJ, Shock, 28 (2007) 24. — 23. HUANG D, CHEN Y, LI K, ZHANG Q, J Huazhong Univ Sci Technolog Med Sci, 28 (2008) 284. — 24. MITSUOKA Y, HATA J, HARUMA K, MANABE N, TANAKA S, CHAYAMA K, Scand J Gastroenterol, 42 (2007) 513. — 25. KNOTZER H, HASIBEDER WR, Physiol Meas, 28 (2007) R65. — 26. SIDO B, TEKLOTE JR, HARTEL M, FRIESS H, BÜCHLER MW, Best Pract Res Clin Anaesthesiol, 18 (2004) 439. — 27. FLOHE S, LENDEMANS S, SCHADE FU, KREUZFELDER E, WAYDHAS C, Intensive Care Med, 30 (2004) 96. — 28. KASHIWA-

BARA M, MIYASHITA M, NOMURA T, MAKINO H, MATSUTANI T, KIM C, TAKEDA S, YAMASHITA K, CHAUDRY IH, TAJIRI T, J Nippon Med Sch, 74 (2007) 274. — 29. REHM M, CONZEN PF, PETER K, FINSTERER U, Anaesthesist, 53 (2004) 347. — 30. HEARD SO, Chest, 123 (2003) 469S. — 31. CRETEUR J, Curr Opin Crit Care, 12 (2006) 272. — 32. KE-

LLUM JA, SONG M, LI J, Crit Care, 8 (2004) 331. — 33. VODOPIJA N, OVČAK Z, ZUPANČIĆ M, KORSIĆ LJ, KRAMEŠ F, KRSTANOSKI Z, PARAC I, Coll Antropol, 33 (2009) 77.

*D. Gulam*

*Ilirska 27, 31000 Osijek, Croatia  
e-mail: danijela.gulam@xnet.hr*

## **CJELOVITOST SLUZNICE TANKOG CRIJEVA TIJEKOM ANESTEZIJE KOD VELIKIH KIRURŠKIH ZAHVATA TRBUHA**

### **SAŽETAK**

Cilj studije je bio ispitati perfuziju i cjelovitost sluznice tankog crijeva tijekom anestezije i kirurškog zahvata na otvorenom trbuhu kod 60 bolesnika u postupcima različitog trajanja. Tijekom operacije uzeta su dva uzorka crijevne sluznice:  $T_0$  na početku postupka i  $T_N$  na kraju postupka ( $N$ =trajanje postupka u satima, od 2 do 7 sati). Svi bioptički uzorci su pregledani a uočena oštećenja sluznice klasificirana u 4 stupnja. Promjene crijevne sluznice su nađene u 31 bolesnika (51,7%): u 19 bolesnika (31,7%) zabilježene su promjene 1. stupnja; u 10 bolesnika (16,7%) promjene 2. stupnja; u 2 bolesnika (3,3%) promjene 3. stupnja. Oštećenja 4. stupnja nisu zabilježena. Postojala je povezanost između stupnjeva oštećenja i trajanja operacije ( $p=0,001$ ). Analiza tijekom jednosatnih vremenskih intervala je pokazala da ne postoji određeno vrijeme kada nastupa značajno pogoršanje patohistološkog nalaza sluznice crijeva. Zatim su bolesnici podijeljeni u 2 skupine: bolesnici kod kojih su operacije trajale manje od 4 sata i oni kod koji su operacije trajale 4 i više sati. Postojala je statistički značajna razlika u stupnjevima oštećenja sluznice između ovako podijeljenih skupina ( $p<0,05$ ). Skupina bolesnika kod kojih je operacija trajala manje od 4 sata imala je više uzoraka biopsije crijeva u kojima nije bilo patohistoloških promjena. Tijekom operacije, u jednosatnim intervalima, uzimani su uzorci krvi iz arterije i mezenterične vene za određivanje pH, koncentracije ugljičnog dioksida i laktata. Razlike u koncentraciji laktata u arterijskoj i mezenteričnoj venskoj krvi nakon 2 i 6 sati postupka između skupine sa i one bez patohistoloških promjena bile su značajne ( $p<0,05$ ). Prema tome, za vrijeme anestezije i operacija na otvorenom trbuhu, dužina postupka utječe na stupanj oštećenja sluznice tankog crijeva. Pogoršanje patohistoloških promjena crijevne sluznice povezano je sa visokom razinom laktata u krvi, dokazujući tako da je uzrok ovih promjena povezan sa tkivnom hipoksijom.