

Partial Monosomy 2p and Partial Trisomy 4q due to Paternal Translocation t(2;4)(p25.1;q31.3)

Škrlec, Ivana; Wagner, Jasenka; Pušeljić, Silvija; Heffer, Marija; Stipoljev, Feodora

Source / Izvornik: **Collegium antropologicum, 2014, 38, 759 - 762**

Journal article, Published version

Rad u časopisu, Objavljena verzija rada (izdavačev PDF)

Permanent link / Trajna poveznica: <https://um.nsk.hr/um:nbn:hr:239:289807>

Rights / Prava: [In copyright](#)/[Zaštićeno autorskim pravom.](#)

Download date / Datum preuzimanja: **2024-11-13**



Repository / Repozitorij:

[Repository UHC Osijek - Repository University Hospital Centre Osijek](#)

Partial Monosomy 2p and Partial Trisomy 4q due to Paternal Translocation t(2;4)(p25.1;q31.3)

Ivana Škrlec¹, Jasenka Wagner¹, Silvija Pušeljić², Marija Heffer¹ and Feodora Stipoljev^{1,3}

¹ »J. J. Strossmayer« University, School of Medicine, Cytogenetics Laboratory, Osijek, Croatia

² »J. J. Strossmayer« University, University Hospital Center Osijek, Pediatric Clinic, Osijek, Croatia

³ University of Zagreb, University Hospital »Sveti Duh«, Department of Obstetrics and Gynecology, Cytogenetics Laboratory, Zagreb, Croatia

ABSTRACT

Clinical features in patients with segmental aneuploidy often vary depending on the size of the chromosomal segment involved. Monosomy 2p is usually observed as a part of more complex syndromes among probands of balanced reciprocal translocation carriers. Patients with dup4q syndrome have variable clinical features, which are both related to the size of duplicated segment of the 4q and specific associated monosomy. Clinical findings of our patient were compatible with those previously reported in dup4q and del2p patients. Herein are presented the clinical and cytogenetic findings in a 4-year-old female with an unbalanced karyotype 46,XX,der(2)t(2;4)(p25.1;q31.3)pat. Clinical phenotypes of 2p;4q translocation cases are variable, because the involved breakpoints vary case-by-case. We also compare similarity of the clinical features of our proband and other patients carrying either duplication of the distal part of 4q and patients carrying a deletion of distal part of 2p as described in the literature. To our knowledge, this is the first case of partial trisomy 4q accompanied with partial monosomy 2p.

Key words: partial monosomy 2p, partial trisomy 4q, translocation, fluorescence in situ hybridization

Introduction

Clinical features in patients with segmental aneuploidy often vary depending on the size of the chromosomal segment involved. Deletions of the distal segment of chromosome 2p are rare. Subtelomeric deletions of short arm of chromosome 2 have been demonstrated in few cases with developmental delay, mental retardation, facial dysmorphism and hypotonia^{1,2}. Monosomy 2p is usually observed as a part of complex chromosomal syndrome among probands of balanced reciprocal translocation carriers¹, like in our case. Partial trisomy of the long arm of chromosome 4, usually resulting from familial translocation segregation, has been described in a number of patients³. Clinically partial trisomy 4q is manifested by mental retardation, clinodactyly, facial dysmorphism, short neck and hypotonia¹. Patients with dup4q syndrome have variable clinical features, which are both related to the size and gene content of duplicated segment and specific associated monosomy³. Comparing the phenotypes of all previously published cases, many differences between them can be found and the reason

might be due to concomitant partial autosomal monosomy⁴. Although partial trisomy 4q and partial monosomy 2p vary in their phenotypes, they also have many common features. Herein are presented the clinical and cytogenetic findings in a 4-year-old female with karyotype 46,XX,der(2)t(2;4)(p25.1;q31.3)pat. We also compare similarity of the clinical features of our proband and other patients carrying solely duplication of the distal part of 4q and a deletion of distal part of 2p as described in the literature.

Case Report

The proband is a 4-year-old female referred for genetic evaluation because of poor verbal articulation. The girl is the first-born of young, healthy non-consanguineous parents. After uneventful pregnancy she was delivered at term, at birth, length was 51 cm (75th centile), weight 3290 g (50th centile), and head circumference 35,5

cm (50th centile). Hypotonia was observed at the age of 9 months. She took her first steps at 2 years and she is yet (4 year old) without sphincters control. Now weights 18,5 kg (95th centile) and 98 cm tall (75th centile). Distinctive facial dysmorphism is present: low hairline on the neck, hypertelorism, epicanthic folds, strabismus, broad nasal bridge, low set ears, irregular teeth growth, small mandible, short neck. A disproportion between large neurocranium and small viscerocranium is present, thorax examination was insignificant. She has short fingers with clinodactyly. Her language is limited to a few words pronounced in syllables. Moderate psychomotor delay was observed (development level 36) with hyperactivity and restlessness. However, there was no growth delay. Family history revealed that the proband's father had a mentally retarded sister, who was adopted and unavailable for cytogenetic study. This study was approved by the Ethics Committees of the University Hospital Center Osijek and School of Medicine, »J. J. Strossmayer« University in Osijek and the written informed consent was obtained from the parents of the girl.

Cytogenetic and FISH Analysis

Cytogenetic and fluorescence in situ hybridization (FISH) analysis were performed on cultured peripheral blood lymphocyte of the proband and her parents by standard methods⁵. Chromosome banding was performed by treatment with trypsin followed by staining with Giemsa to obtain a GTG banded pattern approximately at a resolution of 550 bands. The chromosome region specific probes for telomere 2p (VIJ2yRM2052), centromere 2 (D2Z1), locus specific probe Wolf-Hirschhorn Syndrome region 4p16.3 (LSI WHS) and telomere 4q (AFMA224XH1) (Abbott/Vysis) were used for detection of suspected rearrangement by FISH.

Cytogenetics examination of GTG banded metaphases using Olympus BX61 microscope and Cytovision 3.93 software (Applied Imaging, England) showed an unbalanced karyotype with extra chromosome material at the short arm of the chromosome 2. Subsequent chromo-

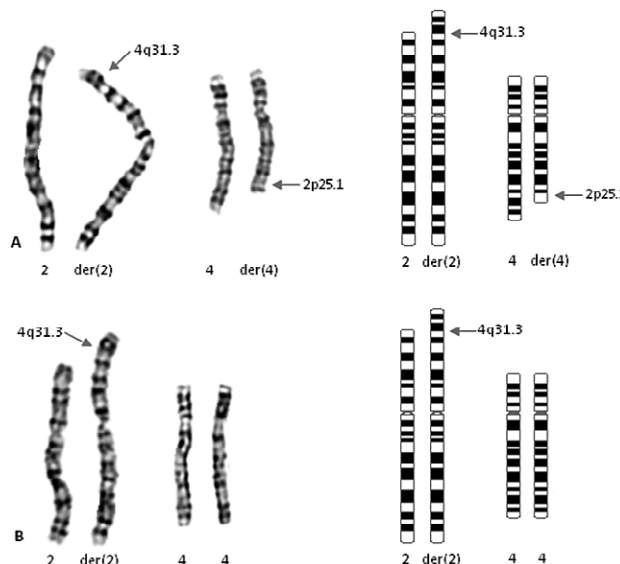


Fig. 1. Partial karyotypes of the GTG banded chromosomes and ideograms of a proband's father showing balanced reciprocal translocation between chromosomes 2 and 4 (A) and a proband showing paternally inherited derivative chromosome 2 and normal chromosome 4 (B).

somal analysis of the parents showed a balanced reciprocal translocation in the father; 46,XY,t(2;4)(p25.1;q31.3) (Figure 1). FISH with specific probes for chromosome regions: centromere 2, telomere 2, WHS and telomere 4q on metaphases showed that telomere 4q probe hybridized at the 4q and at the p arm of the derivative chromosome 2 (Figure 2), at the breakpoint 2p25.1 and 4q31.3. The karyotype of proband is then 46,XX,der(2)t(2;4)(p25.1;q31.3)pat.

Discussion and Conclusion

We described a proband with moderate mental retardation and dysmorphic features with an unbalanced

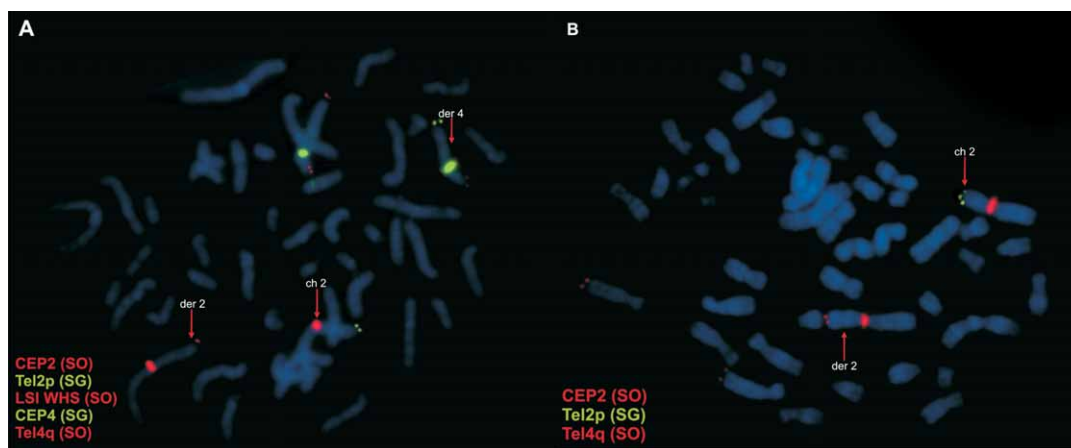


Fig. 2. Proband's father (A) and proband (B) FISH analysis using centromere probes 2 (D2Z1) and 4, locus specific probe for Wolf-Hirschhorn syndrome (LSI WHS) – 4p16.3 and telomere probes 2p (VIJ2yRM2052) and 4q (AFMA224XH1) (Vysis/ Abbott).

TABLE 1
CLINICAL FEATURES OF PURE PARTIAL MONOSOMY 2p AND PURE PARTIAL TRISOMY OF 4q

	Francis et al. (1990) ⁶ Del(2)(pter-p24)	Lo-Castro et al. (2009) ¹ Del(2) (pter-p25.2)	Becker et al. (2010) ² Del(2)(pter-25.2)	Our case 46, XX,der(2)t(2;4) (p25.1;q31.3)	Cernakova et al. (2006) ³ Dup(4)(q28-qter)	Cui et al. (2006) ⁴ Dup(4)(q27-qter)
Short stature	+	–	–	–	–	–
Brachycephaly	+	–	–	+	–	–
Microcephaly	+	+	–	–	+	–
Facial dysmorphism	+	+	–	+	+	+
Strabismus	–	+	–	+	+	–
Epicanthic folds	–	+	–	+	+	+
Ears anomalies	+	+	–	+	+	–
Nose anomalies	–	–	+	–	+	+
Short neck	–	–	–	+	–	–
Clinodactyly	+	–	–	+	–	–
Poor verbal articulation	–	–	+	+	–	+
Hyperactivity	–	+	–	+	–	+
Mental retardation	+	–	+	+	+	+
Growth retardation	+	–	–	–	–	+
Hypotonia	–	+	–	+	+	–

translocation resulting, from paternal balanced reciprocal translocation, in partial trisomy for 4q31.3→qter and partial monosomy for 2p25.1→pter. Further family investigations revealed the balanced paternal reciprocal translocation. A review of other cases identifies variable features in common with pure del 2p^{1,6} and pure dup 4q syndrome^{4,5}. Those include: mental retardation, facial dysmorphism, hypotonia, hyperactivity and speech delay. The phenotypic features of our proband are summarized and compared with previously reported cases of partial trisomy 4q and partial monosomy 2p in Table 1. With exception of microcephaly, widely spaced nipples and congenital heart disease, our proband had most of the clinical features associated with dup 4q syndrome. The variation may be related to such variables as age, sex and different size of chromosome segment involved in dup 4q syndrome, as well as the terminal loss of genetic material of the second chromosome involved in such an unbalanced translocation³. Our case does have most features in common with other cases of complete trisomy 4q. These included delayed development, deep set eyes, strabismus, hypertelorism, epicanthic folds, broad nasal bridge, low set ears, short neck, clinodactyly and mild mental retardation. The involved breakpoints vary between the cases, with consequently variation in phenotypes. Severe stigmatisation has been observed in patients with a larger degree of partial trisomy and in the patients with duplications spanning the distal part of 4q³. The patients with duplicated fragment close to centromere or telomere had mild abnormal phenotype while the segment from 4q27 to 4q31 seemed to be preferentially engaged in the tri-

somy 4q syndrome with severe clinical effects⁴. The strongest association was found between reviewed terminal 2p aberrations and the presence of a wide range of developmental delay, from profoundly impaired, if larger size of chromosome segment was involved in del 2p, to mild¹.

Several features set this patient apart from those with pure 2p deletion and pure dup 4q syndrome. These features included an enlarged neurocranium, minor facial dysmorphism, irregular teeth growth and lack of growth retardation.

Risk of unbalanced offspring in carriers of a balanced reciprocal translocation depends on the length and genetic constitution of exchanged segments⁷. In our family both possible unbalanced karyotypes are probably viable, as a deletion 4q31.3→4qter has been reported in several patients⁸ as well as the partial trisomy of the small terminal part of 2p^{9,10}. Our case represents the clinical manifestations of the combination of small region 2p deletion and 4q duplication.

In conclusion, we reported a case with a karyotype which was not published previously and establish a genotype-phenotype correlation. Reports of small regions of duplication or deletion may contribute significantly to the clarification of region specific phenotypes. It should be useful then to compare clinically other subjects with identical cytogenetic anomalies. Further case reports of this nature would help in further delineating this chromosomal abnormality.

REFERENCES

1. LO-CASTRO A, GIANA G, FICHERA M, CASTIGLIA L, GRILLO L, MUSUMECI SA, GALASSO C, CURATOLO P, Eur J Med Genet, 52 (2009) 67. DOI: 10.1016/j.ejmg.2008.09.004. — 2. BECKER K, JAGGARD C, HORROCKS S, Clin Dysmorphol, 19 (2010) 101. DOI: 10.1097/MCD.0b013e328337bb28. — 3. CERNAKOVA I, KVASNICOVA M, LOVASOVA Z, BADOVA N, DRABEK J, BOUCHALOVA K, TROJANEC R, HAJDUCH M, Biomed Pap Med Fac Univ Palacky Olomouc Czech Repub, 150 (2006) 113. — 4. CUI YX, WANG YH, HAO LJ, HOU L, LI W, HUANG YF, Chin Med J, 119 (2006) 1136. — 5. MOORHEAD PS, NOWELL PC, MELLMAN WJ, BATTIPS DM, HUNGERFORD DA, Exp Cell Res, 20 (1960) 613. — 6. FRANCIS GL, FLANNERY DB, BYRD JR, FISHER ST, J Med Genet, 27 (1990) 137. — 7. PLOMP AS, ENGELEN JJM, ALBRECHTS JCM, de Die-SMULDERS CEM, HAMERS AJH, J Med Genet, 35 (1998) 604. DOI: 10.1136/jmg.35.7.604. — 8. — LIPSON A, COLLIS J, GREEN C, J Med Genet, 19 (1982) 155. — 9. AVIRAM-GOLDRING A, FRITZ B, BARTSCH C, STEUBER E, DANIELY M, LEV D, CHAKI R, BARKAI G, FRYDMAN M, REHDER H, Am J Med Genet, 91 (2000) 74. DOI: 10.1002/(SICI)1096-8628(20000306)91:1<74::AID-AJMG14>3.0.CO;2-O. — 10. THANGAVELU M, FROLICH G, ROGERS D, Am J Med Genet, 124A (2004) 170. DOI: 10.1002/ajmg.a.20322.

I. Škrlec

»J. J. Strossmayer« University, School of Medicine, Cytogenetics Laboratory, J. Huttlera 4, 31 000 Osijek, Croatia
e-mail: iskrlec@mefos.hr

DJELOMIČNA MONOSOMIJA 2p I DJELOMIČNA TRISOMIJA 4p USLIJED OČEVE TRANSLOKACIJE t(2;4)(p25.1;q31.3)

SAŽETAK

Klinička slika pacijenta s djelomičnom aneuploidijom ovisi o veličini kromosomskog segmenta uključenog u translokaciju. Monosomija 2p često je dio složenih sindroma u potomaka nositelja uravnotežene recipročne translokacije. Pacijenti sa sindromom dup4q imaju promjenjivu kliničku sliku koja ovisi o veličini dupliciranog segmenta 4q i specifičnoj pridruženoj monosomiji. Klinička slika naše pacijentice podudara se s kliničkom slikom već objavljenih pacijenata s dup4q i del2p. Prikazani su klinički i citogenetički nalazi četvrogodišnje djevojčice sa nebalansiranim kariotipom 46, XX,der(2)t(2;4)(p25.1;q31.3)pat. Fenotipovi slučajeva translokacije 2p;4q su promjenjivi jer točke loma variraju od pacijenta do pacijenta. Usporedili smo sličnost kliničkih nalaza naše pacijentice s ostalim pacijentima opisanim u literaturi koji imaju ili duplikaciju distalnog dijela 4q ili deleciju distalnog dijela 2p. Ovo je prva pacijentica s djelomičnom trisomijom 4q povezana s djelomičnom monosomijom 2p.