

Our Experience with Virtual Endoscopy of Paranasal Sinuses

Stanko Belina¹, Višeslav Čuk², Ivica Klapan^{3,4,6}, Željko Vranješ⁵ and Juraj Lukinović⁴

¹ Special Hospital for Medical Rehabilitation »Krapinske Toplice«, Krapinske Toplice, Croatia

² General Hospital »Zabok«, Zabok, Croatia

³ School of Medicine, University of Zagreb, Zagreb, Croatia

⁴ University Hospital Centre »Zagreb«, Zagreb, Croatia

⁵ University Hospital Center »Osijek«, Osijek, Croatia

⁶ Polyclinic »Klapan Medical Group«, Zagreb, Croatia

ABSTRACT

The main goal of our work was to evaluate advantages and disadvantages of virtual endoscopy (VE) techniques in routinely diagnostic and preoperative management of patients with various sinus diseases or head traumas in our practice. Fly-through algorithm was performed using an Xeon based workstation on data sets created from axial CT images acquired from 320 patients with various paranasal sinus disorders. Images were created using Siemens Somatom Emotion 16 continuously rotating helical CT scanner and archived in DICOM format. In comparison with real endoscopy, the VE has several advantages. It is completely non-invasive. It is possible to repeat the same procedure several times, therefore it may be a valuable tool for training. Interactive control of all virtual camera parameters, including the field-of-view is possible. Endoscopic viewing as opposed to real endoscopy is not restricted to the spaces defined by inner surfaces. The viewer may penetrate the walls and see the extent of lesions within and beyond the wall as well as the adjacent anatomic structures. Virtual endoscopy also has a potential to stage tumors by determining the location and the extent of transmural extension.

Key words: *Virtual endoscopy, high resolution helical CT, paranasal sinuses*

Introduction

Classical endoscopic procedures performed with rigid endoscopes are invasive and often uncomfortable for patients. Some of them may have serious side effects such as perforation, infection and hemorrhage. Virtual endoscopy (VE) is a new 3D technique which permits to depict the inner surface of anatomic cavities. It is a new method of diagnosis using computer processing of 3D image datasets (such as CT or MRI scans) to provide simulated visualizations of patient specific organs similar or equivalent to those produced by standard endoscopic procedures^{1,2}. Development of new computer techniques and fly through algorithms offers a valuable non-invasive additional tools in diagnostics and preoperative planning in otorhinolaryngology^{2,3}. The main objective of our work was to evaluate virtual endoscopy in patients with various paranasal sinus diseases.

Virtual endoscopy visualization avoids the risks associated with real endoscopy, and when used prior to per-

forming an actual endoscopic exam can minimize procedural difficulties and decrease the rate of morbidity, especially for endoscopists in training^{1,4-7}. We report our experience in the study of the nasal cavity and paranasal sinuses. The main goal of our work was to evaluate advantages and disadvantages of virtual endoscopy (VE) techniques in routinely diagnostic and preoperative management of patients with various sinus diseases or head traumas in our practice.

Patients and Methods

Siemens Somatom Emotion 16 CT scanner was used for image acquisition. CT images were stored in DICOM format and transferred to Xeon-based workstation running standard postprocessing software 3D Syngo CT 2006G from Siemens Medical Systems. Initial postpro-

cessing was performed by one radiologist and one ENT specialist working together on In-space and Fly-through software. Working area during fly-through was divided in four windows showing CT image reconstruction in three major planes and resulting 3D rendered virtual endoscopic view for current position of virtual endocamera. Fly-through path planning was performed by moving mouse pointing device. Recordings of virtual endoscopic images together with appropriate CT images in three major planes during fly-through was performed with Camtasia recorder in real-time.

3D Syngo CT 2006G is the new overall platform for the imaging workstation of Siemens Medical Systems. Virtual endoscopy on the Syngo platform is performed using ray casting method with space leaping as major acceleration technique. It also provides an automatic navigation mode.

We performed VE of paranasal sinuses and nasal cavity in 320 patients with various sinus disorders. Postprocessing of HRCT data produced set of VE images. VE images from selected cases were presented. We present postprocess-

ing results in cases of 31-years old woman, 55-years-old man, 43-years-old man, 21-years-old man, 47-years-old man and 41-year-old woman. Fly-through algorithm was performed using an Xeon based workstation.

Results

We performed VE of maxillary, frontal and sphenoid sinus and also nasal cavity of patients with chronic sinus diseases as a part of diagnostic or preoperative management. Furthermore, we examined three patients with head traumas involving paranasal sinuses, one with multifragment fracture of maxillary sinus wall, one with fracture of the ethmoid and lamina papiracea and one with fracture with sphenoid sinus wall. We also performed a high resolution helical CT scan of paranasal sinuses in a 41-year-old female with maxillary sinus cancer. VE results were then compared by those obtained with standard diagnostic procedures. The results are shown of Figures 1-21.

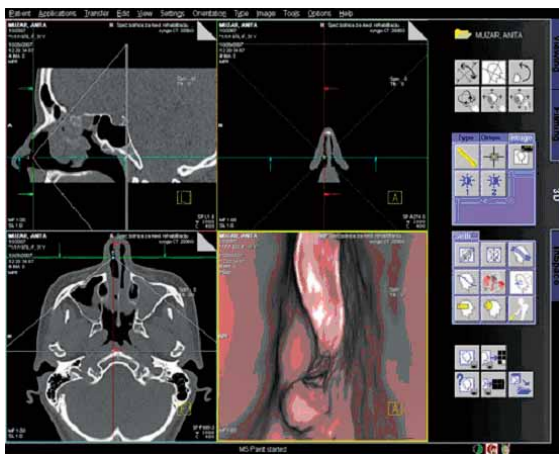


Fig. 1. Anterior rhinoscopy. Polypous mass in the right nasal cavity above the inferior turbinate (31-year old woman).

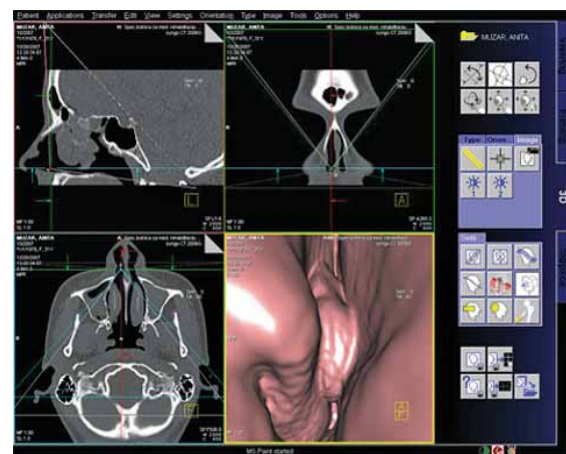


Fig. 2. Anterior rhinoscopy. The virtual endocamera was moved anteriorly and inferiorly. (The same patient as Figure 1).

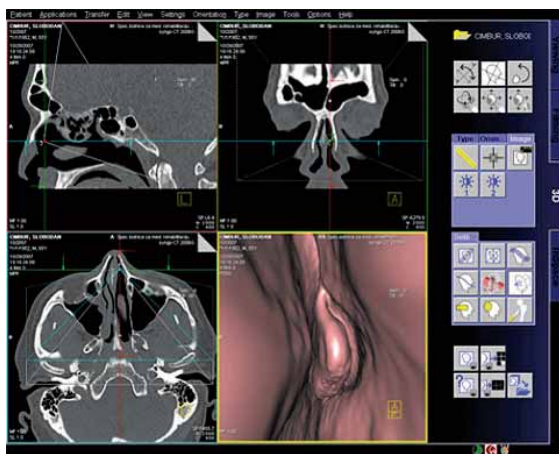


Fig. 3. Anterior rhinoscopy. The view of middle turbinate and ostiomeatal complex from the left side (55-years old man).

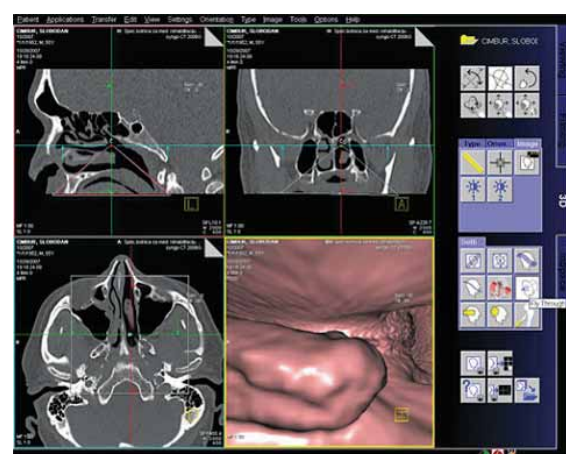


Fig. 4. Virtual endocamera is placed above the inferior turbinate. The posterior part of the septum and the caudal part of inferior turbinate is now visible.

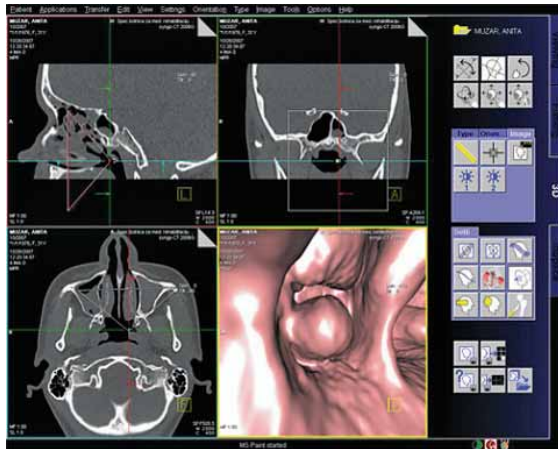

Fig. 5. Posterior rhinoscopy. The virtual endocamera is in the left epipharynx looking towards the inferior turbinate. The posterior part of septum is also visible. (31-years old patient with the history of allergic rhinitis and nasal polyposis).

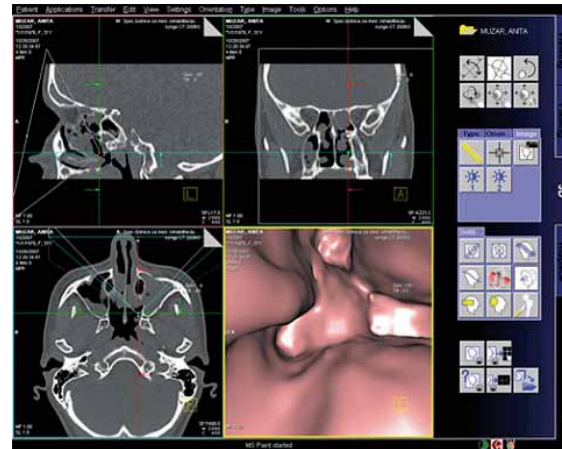

Fig. 6. Virtual endocamera (the same patient) is now positioned anteriorly in the meatus between the left inferior and middle turbinate and the lateral nasal cavity wall. The polypoid masses below the middle turbinate are visible.

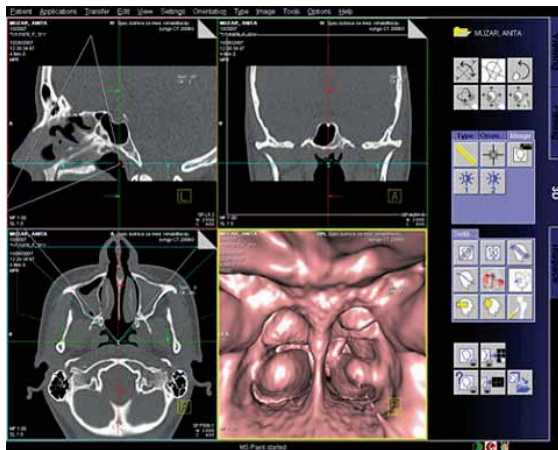

Fig. 7. Posterior rhinoscopy. Virtual endoscope is placed in epipharynx (medial line) and both inferior and middle turbinates

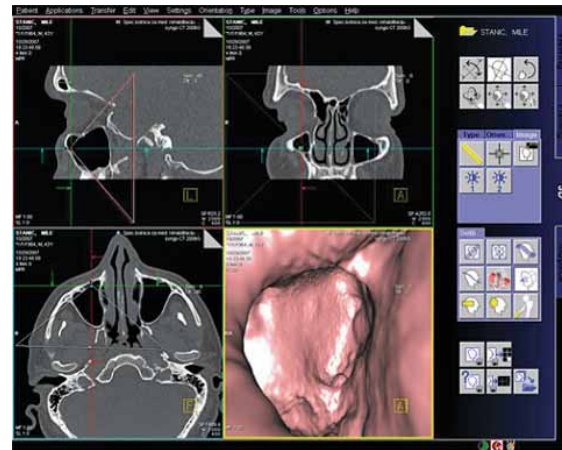


Fig. 8. The virtual endoscopy of the right maxillary sinus (43-year old male patient). The endocamera is turned towards the posterior wall of the sinus. No major pathology can be seen.

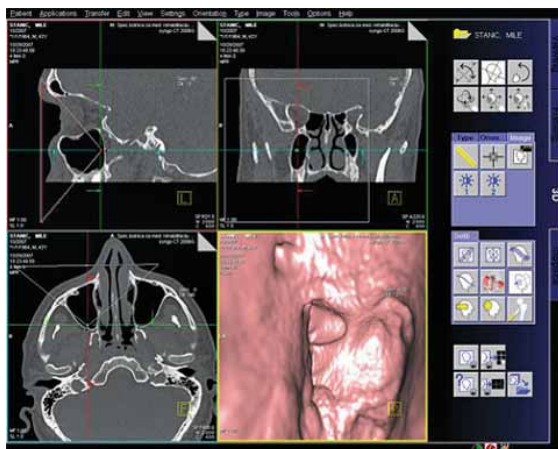


Fig. 9. The same patient as on Figure 8 the endocamera is placed near the posterior wall of the maxillary sinus turned anteriorly. The discrete polypoid thickening of the mucosa of the maxillary sinus is visible.

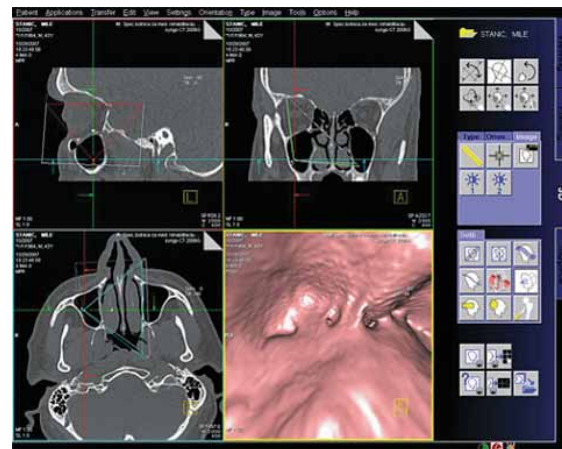

Fig. 10. The endocamera is now placed near the maxillary sinus floor facing towards its medial wall. The ostium of the sinus on the medial wall and the part of its roof can be seen.

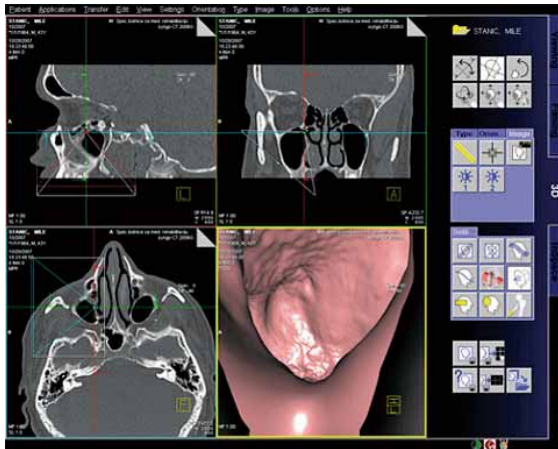


Fig. 11. Virtual camera is placed near the inferior part of maxillary sinus entrance showing towards lateral nasal wall.

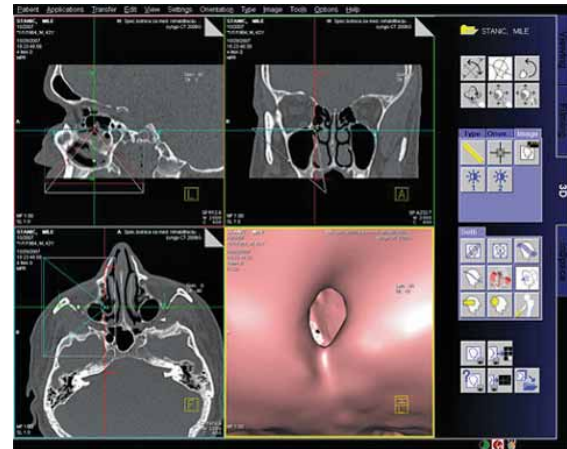


Fig. 12. Virtual endocamera is now turned in the same direction, but now it's moved medially, so the whole maxillary sinus entrance is in the vision, through which some details on the lateral nasal wall can be seen.

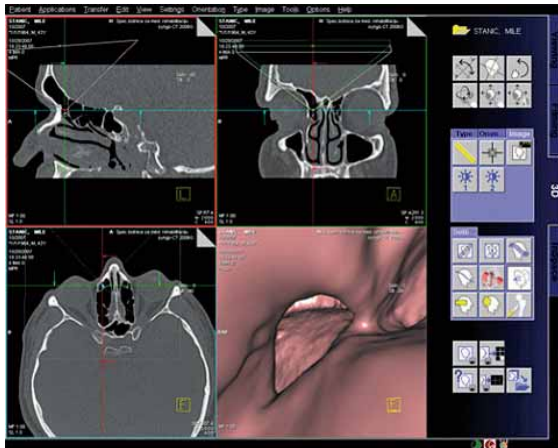

Fig. 13. Virtual endocamera is placed in the frontal recess (43 years old male patient), with the view through the ostium of the right frontal sinus. Through the opening you can see the details of the posterior wall and the roof of the frontal sinus.

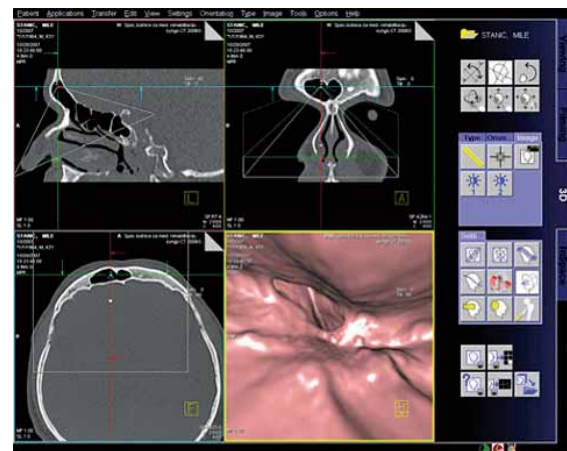


Fig. 14. The virtual endocamera is placed just below the roof of the frontal sinus looking towards its ostium.

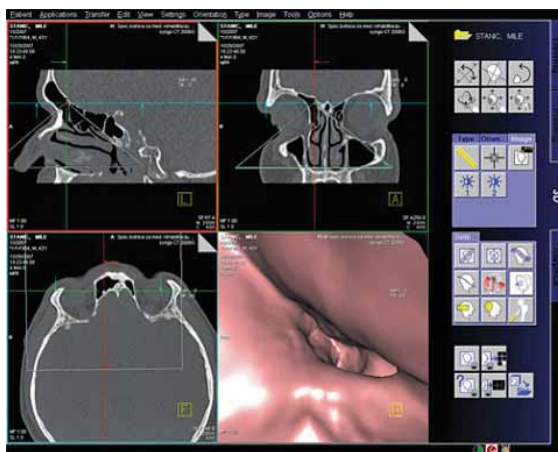


Fig. 15. The endocamera is now moved to caudal facing the ostium of the right frontal sinus.

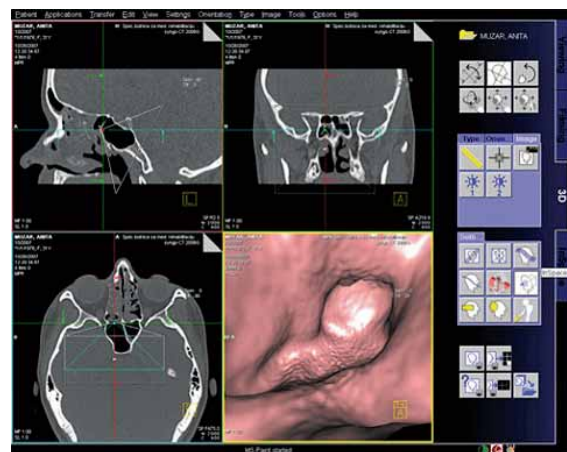


Fig. 16. The endocamera is placed near the anterior wall of the sphenoid sinus (31-years old female), facing backwards. No major pathology can be observed.

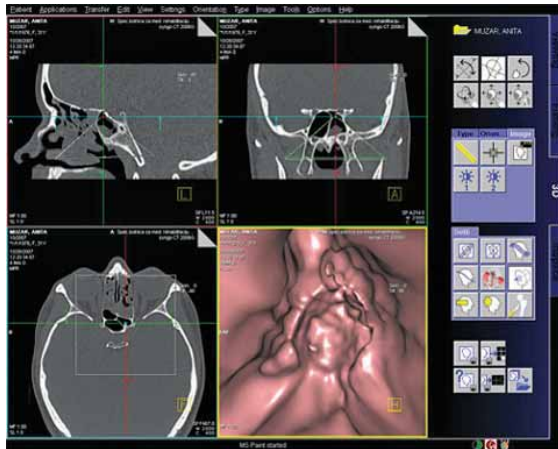


Fig. 17. The endocamera is now placed near the cranial and anterior wall of the sphenoid sinus (the same patient) showing the polypoid masses filling almost one third of the sinus.

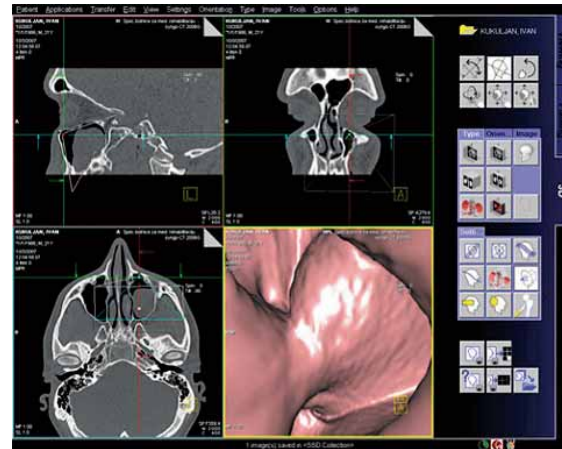


Fig. 18. The big polyp is filling almost the whole maxillary sinus (21-years old male)

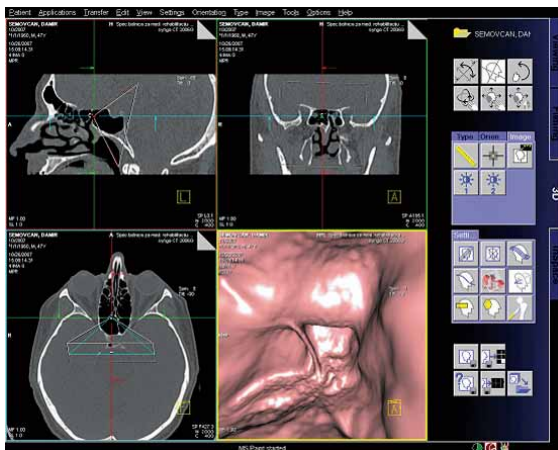

Fig. 19. The virtual endocamera is placed near the anterior wall of the sphenoid sinus (47 years-old male) facing towards the posterior wall. The anatomic variation: a short partial septum can be seen.

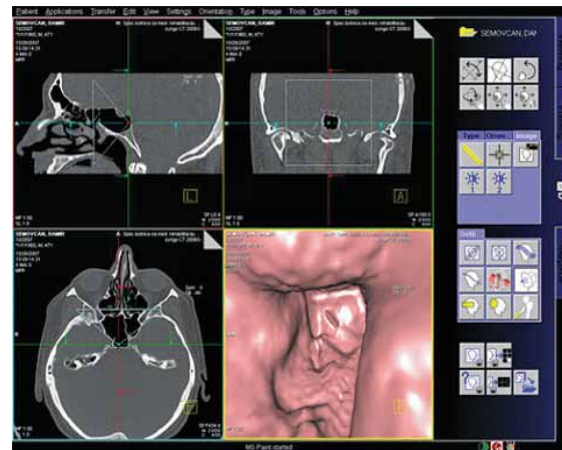


Fig. 20. The virtual endocamera is placed near the posterior wall of the right sphenoid facing anteriorly. The sinus ostium is visible on the frontal wall (47 years old male).

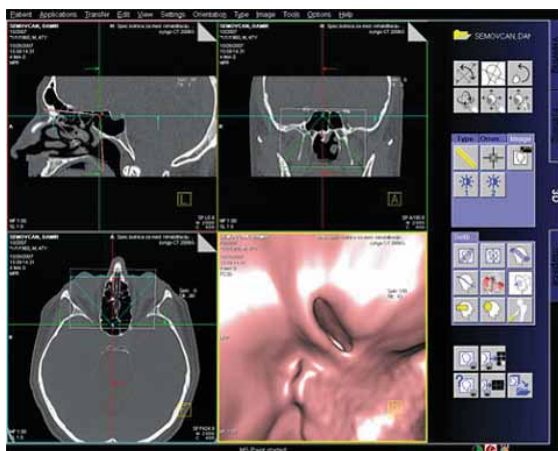

Fig. 21. The endocamera is moved anteriorly and placed in front of the ostium of the right sphenoid showing the anatomical details of the anterior sinus wall.

Discussion and Conclusion

VE or Fly-through methods which combine the features of endoscopic viewing and cross-sectional volumetric imaging may provide an advance in diagnostics and management of our patients^{8–10}. Using virtual endoscopy different goals can be achieved. These goals range from teaching⁴, diagnosis^{5,11}, intervention planning⁶: providing insight into the potentially complicated and non-standard anatomy^{6,7,10} of the patients intra-operative navigation⁷ etc. VE can also be applied for training and familiarize the operator with endoscopic anatomic appearance. Virtual endoscopic presentation of image data enables the operator not only to explore the inner wall surfaces but also to navigate inside the virtual organs extracted from CT and MR images. VE of nasal cavity and paranasal sinuses in combination with in-space skull bone rendering may offer plastic and accurate additional 3D information for head and neck surgeon in combination with classical 2D CT images.

Interactive display of correlated 2D and 3D data in a four-window format may assist the endoscopist in performing various image guided procedures^{4,7,9,12,13}. The current advance in computer technologies makes virtual endoscopy available not only on large clinics but also for routine work in small hospitals^{14,16}.

In comparison with real endoscopy, the VE has several advantages. It is completely non-invasive. It is possible to repeat the same procedure several times, therefore it may be a valuable tool for training. Interactive control of all virtual camera parameters, including the field-of-view is possible. Endoscopic viewing as opposed to real endoscopy is not restricted to the spaces defined by inner surfaces. The viewer may penetrate the walls and see the extent of lesions within and beyond the wall as well as the adjacent anatomic structures. VE has a potential to stage tumors by determining the location and the extent of transmural extension. This is essentially a hybrid technique in which the virtual endoscopic view is used for primary localization but it is the corresponding and accurately referenced 2D image which is ultimately used for assessing the extent of transmural involvement. Without the constraint of the real anatomic boundaries,

the operator is not confined to the inner space of the organs and can easily conceive the entire structure and context. Therefore virtual endoscopy is even more informative than conventional endoscopy¹⁶.

We found Syngo 3D platform for postprocessing CT data easy to use and our generated images and fly through were of good quality with acceptable frame rate therefore our results were comparable or even better than other platforms like VirEn or EasyVision Endo3D – Philips Medical Systems. Virtual endoscopy is relatively simple to carry out as a special representation of a helical CT scan of paranasal sinuses^{13–15}. Compared with classical endoscopy it has several advantages: it is noninvasive; it can pass even high-grade stenoses due to tumors; and for every position of the virtual endoscope in the nasal cavity or sinus cavity, it is possible to refer to the corresponding cross-sectional image or to other multiplanar reconstructions to evaluate structures outside the sinus cavity. A major disadvantage is its inability to evaluate the mucosal surface. Furthermore, biopsy as well as cytologic and microbiologic specimens cannot, be obtained with this method.

REFERENCES

1. ROBB RA, Computerized Medical Imaging and Graphics, 24 (2000) 133. — 2. WICKHAM JEA, BMJ, 308 (1994) 193. — 3. BISDAS S, VERINK M, BURMEISTER HP, STIEVE M, BECKER H, J Comput Assist Tomogr, 28 (2004) 661. — 4. CAVERSACCIO M, EICHENBERGER A, HAUSLER R, Am J Rhinol, 17 (2003) 283. — 5. DI RIENZO L, COEN TIRELLI G, TURCHIO P, GARACI F, GUAZZARONI M, Ann Otol Rhinol Laryngol, 112 (2003) 139. — 6. TAO X, ZHU F, CHEN W, ZHU S, Chin Med J (Engl), 116 (2003) 679. — 7. KLAPAN I, SIMICIC L, RISAVI R, BESENSKI N, PASARIC K, GORTAN D, JANJANIN S, PAVIC D, Otolaryngol Head Neck Surg, 127 (2002) 549. — 8. WOOD BJ, RAZAVI P, Am Fam Physician, 66 (2002) 107. — 9. NAKASATO T, KATOH K, EHARA S, TAMAKAWA Y, HAYAKAWA Y, CHIBA H, MURAI K, J Comput Assist Tomogr, 24 (2000) 486. — 10. MORRA A, CALGARO A, CIOFFI V, PRATTO M, COVA M, POZZI MUCELLI R, Radiol Med (Torino), 96 (1998) 29. — 11. GILANI S, NORBASH AM, RINGL H, RUBIN GD, NAPEL S, TERRIS DJ, Laryngoscope, 107 (1997) 25. — 12. ECKE U, KLIMEK L, MULLER W, ZIEGLER R, MANN W, Comput Aided Surg, 3 (1998) 45. — 13. ROGALLA P, NISCHWITZ A, GOTTSCHALK S, HUITEMA A, KASCHKE O, HAMM B, Eur Radiol, 8 (1998) 946. — 14. DESSL A, GIACOMUZZI SM, SPRINGER P, STOEGER A, POTOTSCHNIG C, VOLKLEIN C, SCHREDER SG, JASCHKE W, Aktuelle Radiol, 7 (1997) 216. — 15. BISDAS S, VERINK M, BURMEISTER HP, STIEVE M, BECKER H, J Comput Assist Tomogr, 28 (2004) 661. — 16. JOLESZ FA, LORENSEN WE, SHINMOTO H, ATSUMI H, NAKAJIMA S, KAVANAUGH P, SAIVIRONPORN P, SELTZER SE, SILVERMAN SG, PHILLIPS M, KIKINIS R, Interactive Virtual Endoscopy, Available from: http://www.spl.harvard.edu/archive/spl-pre2007/pages/papers/frank/virt_endoscopy/endoscopy.html, accessed: September 1, 2008.

S. Belina

Special Hospital for Medical Rehabilitation »Krapinske Toplice«, Gajeva 2, 49217 Krapinske Toplice, Croatia
e-mail: stanko.belina@krt-com.hr

NAŠA ISKUSTVA SA VIRTUALNOM ENDOSKOPIJOM PARANAZALNIH ŠUPLJINA

SAŽETAK

Glavni cilj ovog rada je ocijeniti prednosti i nedostatke virtualne endoskopije (VE) u rutinskoj dijagnostici i preoperativnoj pripremi bolesnika oboljelih od različitih bolesti sinusa i sa ozljedama glave. Algoritam pregleda je načinjen korištenjem radne stanice bazirane na Xeonu i temeljen je na aksijalnim CT snimkama prikupljenih od bolesnika. Snimke su učinjene pomoću Siemens Somatom Emotion 16 spiralnog CT uređaja uz pohranu u DICOM formatu. U usporedbi sa stvarnom endoskopijom, VE ima nekoliko prednosti. U potpunosti je neinvazivna. Moguće je ponoviti isti postupak više puta te je zbog toga vrijedna za edukaciju. Moguća je interaktivna kontrola svih virtualnih parametara kamere, uključujući vidno polje. Korisna je za stupnjevanje (staging) tumora određivanjem lokalizacije i dubine transmuralnog širenja.