

A Coincidence of HLA-B27 Negative Spondyloarthritis and Paravertebral Non-Hodgkin's Lymphoma - A Lesson to be Learned from the Past Experience

Glasnović, Marija; Majnarić, Ljiljana; Sinčić Petričević, Jasminka; Borzan, Vladimir; Kolak, Željka; Včev, Aleksandar; Horvatić, Elizabeta

Source / Izvornik: **Collegium antropologicum, 2015, 39, 219 - 224**

Journal article, Published version

Rad u časopisu, Objavljena verzija rada (izdavačev PDF)

Permanent link / Trajna poveznica: <https://urn.nsk.hr/urn:nbn:hr:239:972127>

Rights / Prava: [In copyright](#)/[Zaštićeno autorskim pravom.](#)

Download date / Datum preuzimanja: **2024-11-22**



Repository / Repozitorij:

[Repository UHC Osijek - Repository University Hospital Centre Osijek](#)

A Coincidence of HLA-B27 Negative Spondyloarthritis and Paravertebral Non-Hodgkin's Lymphoma – A Lesson to be Learned from the Past Experience

Marija Glasnović¹, Ljiljana Majnarić², Jasminka Sinčić Petričević¹, Vladimir Borzan¹, Željka Kolak³, Aleksandar Včev¹ and Elizabeta Horvatić⁴

¹»J. J. Strossmayer« University, School of Medicine, University Hospital Centre Osijek, Clinic for Internal Medicine, Osijek, Croatia

²»J. J. Strossmayer« University, School of Medicine, Osijek, Croatia

³County General Hospital Vinkovci, Vinkovci, Croatia

⁴»Tomislav Bardek« General Hospital, Department of Pathology and Cytology, Koprivnica, Croatia

ABSTRACT

We reported a case of a 71-year-old woman with progressive low back pain and neurologic symptoms of lower extremities, who in the background had the coexistence of spondyloarthritis (SpA) and non-Hodgkin's lymphoma of the paravertebral location. This example describes a situation where SpA with minimal sacroiliac joints affection has nevertheless led to the overt axial SpA. This situation included undifferentiated or reactive SpA, as well as unusual disease context, presented with late-life disease onset, older age, female gender and no obvious hereditary predisposition. This combination of comorbid factors could allow environmental and disease-specific factors to accumulate over time and to, by modifying the primary, low-penetrant genetic background, lead to the development of lymphoma. By achieving better understanding of disease pathophysiology dynamic, we will be able to improve our capabilities to navigate biologic therapy in the future, in order to prevent the development of both, overt SpA and lymphoproliferative disease.

Key words: Spondyloarthritis, HLA-B27 negative, non-Hodgkin's lymphoma, paravertebral location, ageing

Introduction

Ankylosing spondylitis (AS) is a chronic inflammatory disease of the sacroiliac (SI) and vertebral joints which begins in early adulthood, affects men rather than women and leads to severe disability¹. In addition to AS, four other entities have been included under the common classification criteria of spondyloarthritides (SpA), based on similar clinical and genetical features. They include: psoriatic arthritis, reactive arthritis, arthritis associated with inflammatory bowel disease and undifferentiated arthritis². These entities can also be divided according to whether peripheral or axial joints are predominantly affected. The importance of the SpA concept is in observation that patients diagnosed with SpA can also progress into the overt spine disease.

The common symptom of all SpA subgroups is inflammatory back pain, characterized with morning stiffness and nocturnal lower back and buttock pain³. Yet, diagno-

sis has been based on the radiographic signs of the SI joints inflammatory affection⁴. This has been for years the reason of diagnostic delay, as radiographic signs reflect structural changes, the consequences of inflammation, rather than inflammation itself⁵. Testing for Human Leukocyte Antigen B27 (HLA-B27) has been shown to contribute to the diagnosis in patients with symptoms of low back pain and the absence of radiographic signs of sacroiliitis, or when peripheral arthritis is dominating. The rationale is that, in these patients, HLA-B27 positivity brings a 20-fold higher risk of SpA⁶. Diagnostic procedure has recently been improved by introducing magnetic resonance imaging (MRI) technique to detecting early inflammatory signs of sacroiliitis. In this regard, it has been observed that a reasonable proportion of patients with early MRI signs of the SI joints affection subsequently turn into radiographically recognised sacroiliitis⁷. Based

on this observation, MRI testing is now involved in a new, more accurate classification of SpA⁸. In this classification, combination of clinical, imaging and laboratory parameters is used to improve decision on diagnosis, which is particularly helpful in early disease stages, when radiographic signs of disease are still absent.

The need for more accurate identification of patients with SpA and especially of those of them who have higher disease activity and are therefore at increased risk of developing severe disease, has been emphasized in the recent years, when new anti-inflammatory drugs have been shown to provide substantial benefit to these patients^{1,9,10}. Although generally beneficial, these drugs can also lead to harm¹¹. This is a reason more why it is important to understand the pathogenetic background of this group of diseases, where the level of inflammation and therefore also anti-inflammatory drugs, can change their course.

Evidence has been increasing to support the association of inflammatory rheumatic diseases with other serious conditions, including cardiovascular diseases, cancer and lymphoproliferative diseases^{12–14}. Learning from case reports is an appropriate method to improve our sensibility on the existence of a variety of these conditions and to provide us with better insight into their complex underlying pathophysiologic network. In this way also, this method can improve our capabilities to cope with challenges of biological treatment.

In this sense, a case report presented here is of utmost importance. It should turn our attention on situations where SpA with minimal SI joints affection can nevertheless lead to overt axial SpA. These situations may include, as presented here, cases with undifferentiated or reactive SpA and less usual context, such as late-life disease onset in a woman with no obvious hereditary predisposition. Such specific situation, probably exactly for the reason of a delay in clinical expression of SpA, or of a slow course of disease progression, could lead to the development of another serious disorder, in the form of non-Hodgkin's lymphoma (NHL). In this way, this report tends to emphasize the importance of the context, in our efforts to predict future events. This is also the first case reported until now, within those engaged in SpA matters, presented with paravertebral location of NHL.

Case Report

A 71-year-old woman was referred to the rheumatologist in March, 2013, for severe low back pain with irradiation into the left low extremity. The pain has started 3 months ago and has been becoming worse, despite the use of analgesics and nonsteroidal anti-inflammatory drugs and physical therapy. Since several days ago, the pain has become penetrating and she felt numbness in both legs. Laboratory check up indicated mild anaemia, with red blood cell (RBC) count of 3.95 (x 10¹²/L) and Haemoglobin (Hb) level of 116 g/L. Inflammatory markers were not in favour of acute inflammation, with sedimentation rate

(SE) of 21, the White Blood Cell (WBC) count of 4.9 (10³/mm³) and C-reactive protein (CRP) of 1.9 (mg/L).

This was her second visit to the rheumatologist. The first one took place 7 years ago (2006), when she also presented with low back pain and lumboschialgia. On the available radiographs from that time, overt degenerative changes of the cervical and thoracic spine were evident, including large osteophytes and syndesmophytes. Local fusion of thoracic vertebrae was suspected on »bamboo spine«. Laboratory testing, at that first encounter, did not show active inflammation. HLA-B27 antigen testing yielded a negative result.

At this repeated visit, she has been hospitalized for further examination. Medical history did not reveal rheumatic diseases in the family and she denied peripheral joints swelling from before. She has only had hypertension for a long time. Her sister died from myocardial infarction. When she was 59, she experienced an episode of postmenopausal vaginal bleeding. On examination, she still looked overweight, although noted the loss of 20 kg in the last 4 months. When questioned, she reported on low back morning stiffness of 2h duration and the pain in the knees, more intensively expressed on the left-side. There were no eczematous rash or sole lesions on the skin. Peripheral lymph nodes did not seem enlarged, nor the liver and spleen. Neither ultrasound abdominal examination could provide us with such information. All tests done, including blood biochemical tests, rheumatoid factors testing, urine microbiology culture and monoclonal proteins in the blood, were within the reference range. Only cervical and urethral smear culture was positive on ureaplasma urealyticum. Renewed radiography of the thoracic and lumbar spine demonstrated paravertebral ossification and flowing osteophytes across multiple vertebral levels, on the ventral and lateral sides, predominantly in the thoracic spine (Figure 1 a,b). Degenerative intervertebral osteochondrosis was visible alongside the thoracolumbar spine. Medial and dorsal columns were also degeneratively affected. The parrot's beak osteophyte-like growths discriminated in favour of AS, or reactive SpA. In the same sense, the radiographs of the SI joints revealed advanced sacroiliitis, although of a minimal change involvement, as based on patchy bilateral subchondral sclerosis and a small sclerotic area (insula compacta), located in the upper part of *masse lateralis*, on the right side.

Soon after admission, weakness in her legs increased, being suggestive of a spinal cord disease. There were no alerts in laboratory findings, only mildly increased total leukocyte count of 12.2. Urgent MRI scan of the spine, both native and contrast-enhanced, showed tissue/fluid dorsal paravertebral mass in the close proximity of the thoracic aorta, with the spread in the caudal third of the thoracic spine, encompassing levels Th VII/VIII to L I/II (Figure 2). Described mass caused infiltration and destruction of Th VII and Th IX vertebrae, while vertebrae Th X showed changed signals intensity by means of inflammation. There was infiltration of this tumorous mass into *canalis vertebralis* at the level Th VIII–IX. Heterogeneity of MRI signals at the sagittal plane suggested also

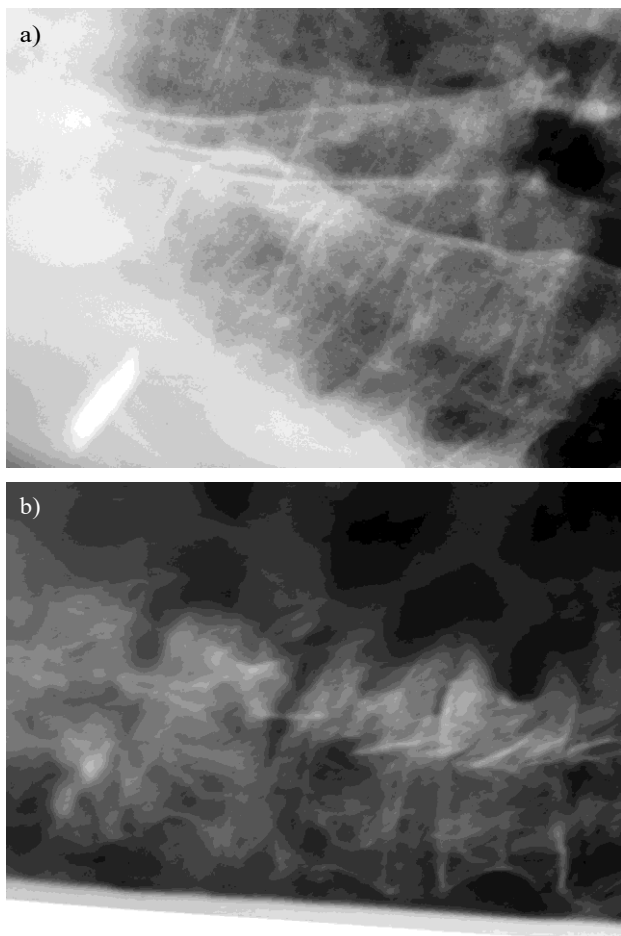


Fig. 1. a, b. Radiographs of the thoracolumbar spine demonstrating paravertebral ossification (a), and flowing osteophytes on the ventral and lateral sides (b).

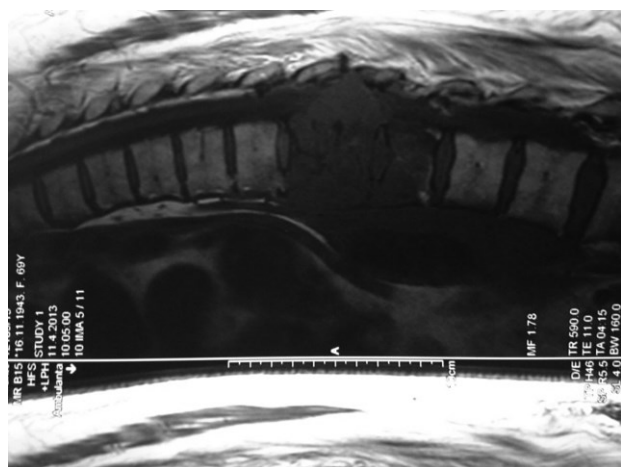


Fig. 2. Contrast-enhanced MRI scan of the spine showing tissue/fluid dorsal paravertebral mass with the spread in the caudal third of the thoracic spine and the thoracolumbar transition. Destruction of Th VII and Th IX vertebrae and infiltration of the canalis vertebralis caused by tumorous mass is visible on the photograph.

spinal cord infiltration, while its compression was clearly visible at the corresponding intervertebral (i.v.) disc space levels. Of other important MRI signs, there were overt degenerative changes of i.v. discs visible across multiple levels of thoracolumbar spine and foraminal disc protrusions at all levels of lumbar spine. Ligamenta flava showed hypertrophy and there were also degenerative changes of small joints.

It was a month after admission, in the mid of April, when the patient was urgently replaced to the department of neurosurgery, for urgent spinal cord decompression and tumor mass pathological examination. Pathohistological and phenotypic analysis revealed Diffuse Large B-cell CD20+ Lymphoma (Figure 3). After surgery, the patient was replaced to the department of haemathology, for disease staging and polychemotherapy. Extensive staging showed the systemic spread of disease. Treatment, according to the R-CHOP protocol, together with intrathecal

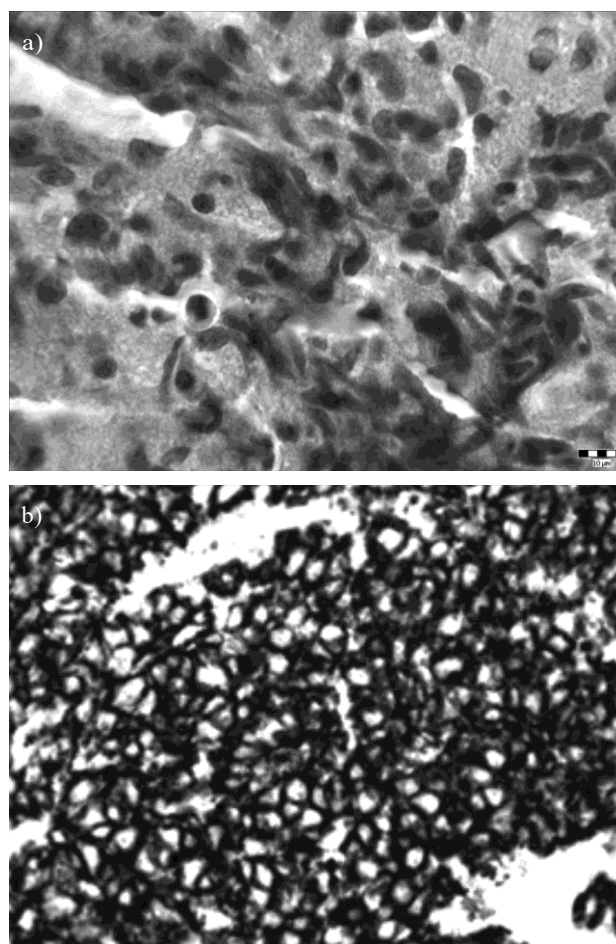


Fig. 3. a) Histological examination. The tumor tissue is densely populated by atypical cells with eosinophilic cytoplasm and erose boundaries. The cells show oval pleomorphic hyperchromatic nuclei while large eosinophilic nucleoli are scattered all around. Mitotic activity is sporadic. The tumor tissue is highly saturated with vasculature abundantly infiltrated with mononuclear inflammatory cells. (1000 x 1); b) Immunophenotypical analysis. Cells are strongly positive for B cell marker CD20. (400 x 1c).

MTX application and local radioation, has immediately been introduced. The requirement for the treatment with Rituximab was applied to the Hospital Drug Approval Committee. However, shortly after the beginning of the therapy, the clinical course of disease was complicated with severe neutropenia and mucositis. During the second cycle of the protocol, performed in June, Filgrastin was given to her through five days, but very low leukocyte number has persisted and her physical condition has further deteriorated. Three days after the last discharge, in August, she was urgently readmitted because of febrile neutropenia. She was also highly anemic. She had haemoculture positive for MRSA and an inflammatory infiltrate in the lungs. Ten days later, she died.

Discussion

Great advances in classification of the SpA disease group and in assessment of disease activity, in the last decade, have allowed for clinical studies to be conducted in early disease state and the results of biological treatment to be followed and compared^{1,15}. Under the influence of targeted anti-inflammatory therapy, such as anti-TNF α , it is likely that the biological landscape of these diseases turns on the change, by means of symptoms reduction and overt clinical disease disappearance¹⁵. In addition, the course of many comorbid conditions is also likely to be modified. In this regard, it is known that, specifically for undifferentiated arthritis, dispersion of pathogenesis is possible, by gaining into the course of SpA also psoriasis or IBD¹⁶. Related to the latter, there may be a new onset of IBD, or an outbreak of silent colitis, arising from sub-clinical gut inflammation¹⁷. Or, SpA may occur after an asymptomatic gastrointestinal and urinary triggering infection, for which reason is difficult to discriminate between reactive and undifferentiated SpA, especially when peripheral disease is dominating¹⁶. Relative relationships between these pathogenetic conditions and their translations over time, from one state to the other, can be largely affected by the use of biological treatment. To understand these translations, it is important to get better insight into underlying complexity and the time-dependent course of these conditions.

In this report, we presented an older woman with progressive low back pain and neurologic deficit of the lower extremities who in the background had the coexistence of SpA and NHL of the paravertebral location. Although the link of systemic autoimmune and rheumatic diseases, such as Sjogren's syndrome and rheumatoid arthritis (RA), with lymphoproliferative disorders, has already been established, this association in respect to SpA has not yet been confirmed^{14,18,19}. The probable reason is that this association is rare and might have been stayed beyond what observers can usually see. This problem has turned into the focus of researchers just recently, when it has been shown that anti-TNF- α therapy, applied in patients with RA, can trigger the development of lymphoma²⁰. There have also been a few reports stating increased risk of lymphoma in patients with AS who have received anti-TNF treatment^{20,21}.

Based on these reports, the question arises on the relative importance of inflammation and immunosuppression in the pathogenesis of lymphoproliferative disorders. In this regard, the both, inflammation-related and immunodeficiency-related etiologies of lymphoma, however each entity studied separately, have so far been recognised^{22,23}. There is also a notion that the higher cumulative level of inflammation, in patients with RA, in comparison to those with SpA, is probably responsible for the higher observed risk of lymphoma, in the former group¹⁹. A logical inference arising from these facts is that there must be some other relevant factors except inflammation which may, in patients with SpA, direct pathogenetic mechanisms towards lymphomagenesis. Based on the existent knowledge, this extra contribution may come from the specific genetic background which in patients with SpA is marked with the presence of the HLA-B27 antigen. In this regard, the evidence suggests that patients with AS and the concomitant expression of this antigen are likely to be predisposed to more aggressive forms of haematological malignancies, specifically of the lymphoid tissue origin²⁴. Moreover, not only the status of being HLA-B27 positive, but also the level of this antigen expression, is likely to be important for the decision on whether clinical expression of AS will really occur²⁵. Taken together, strong HLA-B27 positivity, as responsible for fast progression of AS and early age at disease onset, might also, in these patients, be associated with the propensity of developing lymphoma in early adulthood age. This statement is likely to be supported by the evidence that factors responsible for the fast transfer from early SpA disease stage to the overt spine disease include male sex (known to be more strongly associated with the HLA-B27 antigen expression than female sex) and elevated inflammation level, manifested with increased C-reactive protein (CRP)²⁶. Recently published case reports may be used to support this assumption. These reports include the case of a 38-year-old man with 15 year long history of HLAB-27 positive AS and the naturally developed Hodgkin's lymphoma²⁷. When this strictly genetically engineered program, based on the HLA-B27 antigen expression, is lacking, some other contributing factors, in patients with SpA, such as severe immunosuppression, developed for example after intensive anti-inflammatory treatment, might be necessary to mediate lymphoma development. This alternative scenario is likely to be described in another case report, presented with a 45-year old woman with the history of AS who received TNF blocker etanercept and large amounts of glucocorticoid immunosuppressive therapies and was, not long after that, complicated with lymphoma²⁸. In this regard, world knowledge on the association of chronic inflammatory and rheumatic diseases with the subsequent lymphoma development has revealed some common risk factors, including prolonged disease course and increased disease severity. B-cell NHL, especially diffuse large B-cell lymphoma, was found to be the most frequent type of lymphoproliferative disorders, in these patients. By information integration, it was possible to realise that the question of whether or not lymphoma will occur, and of which kind, is largely influenced by patient age and disease-

specific mechanisms^{14,22,29}. In this context, the method of case-based reports might be of significant importance to learning on the time-dependent course of a disease and on complexity of the contextual factors, providing us with better understanding and the capability to deal with new antiinflammatory treatments.

In contrast to what has been described above as to be conventional AS/lymphoma phenotypes, we presented here the case of an older woman with late-life AS expression, on the basis of undifferentiated SpA, or reactive arthritis, combined with abundantly developed degenerative changes of the spine and peripheral joints (the knees). This jointed condition could contribute a lot to the overall inflammation burden in this woman. Chronic latent infection, as indicated with ureaplasma positive cervical smear culture, could also give the contribution to both, pathogenesis of inflammatory joint disease and increased systemic inflammation. In addition to that, advanced age per se is a condition known to cause increased systemic inflammation, which has been proposed to account for many age-dependent phenotypic changes³⁰. On such background, persistent B-lymphocyte proliferation, mandatory to lymphoma formation, could easily take place. Namely, each of these mechanisms, including aging, increased systemic inflammation and autoimmune inflammatory disease, even taken separately, can be the underlying mechanism of abnormal cells growth and impaired cell-cycle control, leading to the both, the immune system dysfunction and the development of lymphoproliferative disorders^{31–33}. This can especially be a case when older age, as it is in this example, is combined with unfavorable disease context, including insulin resistance, due to the overweight and long-lasting hypertension³⁴. Insulin resistance state, in our report, is further implicated by endometrial hypertrophy and the episode of vaginal bleeding. When wider pathophysiologic background, shared between close family members, are added, then cardiovascular diseases (CVDs) can also be taken into account as a part of this complex pathogenetic background (history of CV death in a sister). In this regard, it is known that in patients with AS, there is higher risk for CVDs, independently on whether they are HLA-B27 positive, or not^{35,36}.

Taken together, in our example, it is likely that HLA-B27 negativity, combined with female gender and older age at disease onset, has allowed for many environmental and

disease-specific factors to gather overtime and to modify the primary genetic background, which was not propense enough to allow the early SpA development. Exactly advanced age, due to the late SpA onset, by masking the course of the disease, could allow lymphoma to develop. By revealing these multiple pathogenetic layers, we could improve our capabilities to navigate biologic therapy in the future, by targeting both, the course of AS and lymphoid tissue malignant transformation³⁷. By fine tuning this therapy, we would be also able to mitigate the hazardous effect of the concomitant CV risk factors³⁸.

We selected this case for presentation for one more reason – to show that an inflammatory niche, in addition to the systemic factors, might also be necessary for lymphoma development. This is indicated by the paravertebral location of the lymphoid tumor, indicating its origin in the local lymph nodes, placed in the close proximity of the spine structures. This location might have been important for the reason of supply of proliferated B-cells, within germinal centers, with chronic antigenic load, in the form of degraded products of the inflammatory affected spine structures, which is necessary for B-cells oncogenic transformation^{14,39–42}. This location could also provide an appropriate microenvironment for the tumor growth, due to the large amounts of proinflammatory cytokines and other important mediators^{42,43}. The requirement for the local inflammatory niche, for lymphoma development, in patients with SpA, can also be recognised in some other published reports, including an example of an older man with primary knee synovial NHL, associated with longstanding AS and the knee inflammation⁴⁴.

It seems, based on this analysis, that early detection of subjects at increased risk for the development of lymphoma, in patients with SpA, would require biomarkers development and predictive modeling, to support our efforts to target anti-inflammatory treatment on time, to prevent clinical expression of both, overt spinal disease and its hazardous complications. In order to achieve this goal, case-based reports can be a valuable method, by providing us with necessary understanding of the complex pathogenetic background of SpA related issues and factors influencing changes through time. In case of this achievement, reports as it is this one, would only be a lesson learnt from the past time.

REFERENCES

1. BRAUN J, PHAM T, SIEPER J, DAVIS S, van der LINDEN, M DOUGADOS, D VANDERHEIJDE, *Ann Rheum Dis*, 62 (2003) 817. — 2. DOUGADOS M, VAN DER LINDEN S, JUHLIN R, HUITFELDT B, AMORB, CALINA, CATSA, DIJKMANS B, OLIVIERI I, PASERO G, *Arthritis Rheum*, 34 (1991) 1218. — 3. CALIN A, PORTA J, FRIES JF, SCHURMANDJ, *JAMA*, 237 (1977) 2613. — 4. BENNETT PH, BURCH TA, *Excerpta Medical Foundation (Amsterdam)*, (1966) 456. — 5. RUDWALEIT M, van der HEIJDE D, KHAN MA, BRAUN J, SIEPER J, *Radiology*, 194 (1995) 529. — 6. SHEEHAN NJ, *JR Soc Med*, 97 (2004) 10. — 7. WEBER U, LAMBERT RG, ØSTERGAARD M, *Arthritis Rheum*, 62 (2010) 3048. — 8. RUDWALEIT M, VAN DER HEIJDE D, LANDEWÉ R, LISTING J, AKKOC N, BRANDT J, BRAUN J, CHOU CT, COLLANTES-ESTEVEZ E, DOUGADOS M, HUANG F, GU J, KHAN MA, KIRAZLI Y, MAKSYMOWYCH WP, MIELANTS H, SØRENSEN IJ, OZGOCMEN S, ROUSSOU E, VALLE-ORIENTE R, WEBER U, WEI J, SIEPER J, *Ann Rheum Dis*, 68 (2009) 777. — 9. BRAUN J, BARALIAKOS X, GOLDER W, BRANDT J, RUDWALEIT M, LISTING J, BOLLOW M, SIEPER J, van der HEIJDE D, *Arthritis Rheum*, 48 (2003) 1126. — 10. MAKSYMOWYCH WP, POOLE AR, HIEBERT L, WEBBA, IONESCU M, LOBANOK T, KING L, DAVIS JC Jr, *J Rheumatol* 32 (10) (2005) 1911. — 11. ANTONI C, BRAUN J, *J Clin Exp Rheumatol*, 20 (suppl 28) (2002) S1 52. — 12. SZABO SM, LEVY AR, RAO SR, KIRBACH SE, LACAILLE D, CIFALDI M, MAKSYMOWYCH WP, *Arthritis Rheum*, 63 (2011) 3294. — 13. LEANDRO MJ, ISENBERG DA, *Scand J Rheumatol*, 30 (2001) 185. — 14. HANSEN A, LIPSKY PE, DORNER T, *Nat Clin Pract Rheumatol*, 3 (2007) 561. — 15. KHAN MA,

- Rheumatology, 50(2011)637. — 16. ZOCHLING J, BRANDT J, BRAUN J, Rheumatology (Oxford), 44 (2005) 1483. — 17. JACQUES P, ELEWALT D, MIELANTS H, Curr Rheumatol Report, 22 (2010) 368. — 18. EKSTROM SK, VAJDIC CM, FALSTER M, ENGELS EA, MARTINEZ-MAZAO, TURNER J, HJALGRIMH, VINEIS P, SENIORI CONSTANTINA, BRACCIPM, HOLLY EA, WILLETT E, SPINELLI JJ, La VECCHIA C, ZHENG T, BECKER N, De SANJOSE S, CHIU BC, Dal MASO L, COCCOP, MAYNADIEM, FORETOVA L, STAINESA, BRENNAN P, DAVIS S, SEVERSON R, CERHAN JR, BREEN EC, BIRMAN B, GRULICH AE, COZEN W, Blood, 111 (2008) 4029. — 19. ASKLING J, KLARESKOG L, BLOMQVIST P, FORED M, FELTELIUS N, Ann Rheum Dis, 65 (2006) 1184. — 20. AKSU K, DONMEZ A, ERTAN Y, KESER G, INAL V, ODER G, TOMBULOGLU M, KABASAKAL Y, DOGANAVSARGIL E, Rheumatol Int, 28 (2007) 185. — 21. AKSU K, CAGIRGAN S, OZSAN N, KESER G, SAHIN F, Rheumatol Int, 31 (2011) 1645. — 22. SMEDBY KE, HJALGRIMH, ASKLING J, CHANG ET, GREGERSEN H, PORWIT-MacDonald A, SUNDSTROM C, AKERMAN M, MELBYE M, GLIMELIUS B, ADAMI HO, J Natl Cancer Inst, 98 (2006) 51. — 23. TRAN H, NOURSE J, HALL S, GREEN M, GRIFFITHS L, GANDHI MK, Blood Rev, 22 (2008) 261. — 24. AU WY, HAWKINS BR, CHENG N, LIE AK, LIANG R, KWONG YL, Br J Haematol, 115 (2001) 320. — 25. CAULI A, DESSOLE G, FIORILLO MT, VACCA A, MAMELI A, BITTI P, PASSIU G, SORRENTINO R, MATHIEU A, Rheumatology (Oxford), 41 (2002) 1375. — 26. RUDWALEIT M, HAIBEL H, BARALIAKOS X, LISTING J, MARKER-HERMANN E, ZEIDLER H, BRAUN J, SIEPER J, Arthritis Rheum, 60 (2009) 717. — 27. KIM YS, KIM HS, Int J Rheum Dis, 15 (2012) e68. — 28. XU L, BMJ Case reports, (2011). DOI: 10.1136/bcr.05.2011.4245. — 29. DIAS C, ISENBERG DA, Nat Rev Rheumatol, 7 (2011) 360. — 30. ERSHLER WB, KELLER ET, Annu Rev Med, 51 (2000) 245. — 31. DIENZ O, RINCON M, Clin Immunol, 130 (2009) 27. — 32. BLAESER A, McGLAUCHLEN K, VOGEL LA, BioMed Central Immunity&Aging, 5 (2008) 15. DOI:10.1186/1742-4933-5-15. — 33. VINUESA CG, SANZI, COOK MC, Nat Rev Immunol, 9 (2009) 845. DOI: 10.1038/nri2637. — 34. LARSSON SC, WOLK A, Eur J Cancer, 47 (2011) 2422. — 35. PETERS MJ, VAN DER HORST-BRUIJNSMA IE, DIJKMANS BA, NUROMO-HAMED MT, Semin Arthritis Rheum, 34 (2004) 585. — 36. MATHIEU S, GOSSEC L, DOUGADOS M, SOUBRIER M, Arthritis Care Research, 63 (2011) 557. — 37. PLOSKER GL, FIGGITT DP, Drugs, 63 (2003) 803. — 38. CUGNO M, INGEGNOLI F, GUALTIEROTTI R, FANTINI F, Curr Vasc Pharmacol, 8 (2010) 285. — 39. SMEDBY KE, HJALGRIMH, ASKLING J, CHANG ET, GREGERSEN H, PORWIT-MACDONALD A, SUNDSTROM C, AKERMAN M, MELBYE M, GLIMELIUS B, ADAMI HO, J Natl Cancer Inst, 98 (2006) 51. — 40. DU M, DISS TC, XU C, PENG G H, ISAACSON PG, PAN L, Leukemia, 10 (1996) 1190. — 41. FRASER A, FEARON U, BILLINGHURST RC, IONESCU M, REECE R, BARWICK T, EMERY P, POOLE AR, VEALE DJ, Arthritis Rheum, 48 (2003) 3085. — 42. HAMEL KM, LIARSKI VM, CLARK MR, Autoimmunity, 45 (2012) 333. — 43. SEIFERT M, SCHOLTYSIK R, KUPPERS R. Origin and pathogenesis of B cell lymphomas. In: Lymphoma: Methods and protocols, 971 (2013) 1. DOI: 10.1007/978-1-62703-269-8_1. — 44. KHAN SY, HUTCHINSON DG, Rheumatology, 43 (2004) 391. DOI: 10.1093/rheumatology/keh015

Lj. Majnarić

»J. J. Strossmayer« University, School of Medicine, J. Huttlera 4, 31000 Osijek, Croatia
e-mail: ljiljana.majnarić@hi.t-com.hr

KOINCIDENCIJA IZMEĐU HLA-B27 NEGATIVNOG SPONDILOARTRITISA I PARAVERTEBRALNE LOKALIZACIJE NON-HODGKIN-OVOG LIMFOMA – LEKCIJA KOJU BI TREBALO NAUČITI IZ PROŠLOSTI

S A Ž E T A K

Prikazali smo slučaj 71-godišnje žene s progresivnim bolom u križima i neurološkim simptomima donjih ekstremiteta, čiju je pozadinu činila koegzistencija spondiloartritisa (SpA) i ne-Hodgkin-ova limfoma paravertebralne lokalizacije. Taj slučaj opisuje situaciju gdje je SpA s minimalnim promjenama na sakroilijačnim zglobovima ipak doveo do razvoja uznapredovalog oblika aksijalnog SpA. Ta situacija je uključivala nediferencirani ili reaktivni SpA, kao i neuobičajeni klinički kontekst predstavljen kasnim početkom bolesti, starijom dobi, ženskim spolom i odsustvom nasljedne predispozicije bolesti. Takva kombinacija ko-morbiditetnih čimbenika je bila pogodna da omogući okolišnim i za bolest specifičnim čimbenicima da se nakupljaju kroz vrijeme i da, modificirajući primarnu, slabo penetrirajuću genetsku podlogu, dovedu do razvoja limfoma. S boljim razumijevanjem patofiziološke dinamike bolesti, poboljšat ćemo i našu sposobnost da specifično usmjeravamo biološku terapiju u budućnosti, da bi spriječili razvoj, kako uznapredovalog oblika SpA, tako i limfoproliferativne bolesti.