

Coronary Microcirculatory Dysfunction in Human Cardiomyopathies

A Pathologic and Pathophysiologic Review

Kristina Selthofer-Relatic, MD, PhD,*† Martina Mihalj, MD, PhD,‡ Aleksandar Kibel MD, PhD,*‡ Ana Stupin, MD, PhD,‡ Marko Stupin, MD,*‡ Ivana Jukic, MD, PhD,‡ Akos Koller, MD, PhD, §¶ and Ines Drenjancevic, MD, PhD‡

Abstract: Cardiomyopathies are a heterogeneous group of diseases of the myocardium. The term cardiomyopathy involves a wide range of pathogenic mechanisms that affect the structural and functional states of cardiomyocytes, extravascular tissues, and coronary vasculature, including both epicardial coronary arteries and the microcirculation. In the developed phase, cardiomyopathies present with various clinical symptoms: dyspnea, chest pain, palpitations, swelling of the extremities, arrhythmias, and sudden cardiac death. Due to the heterogeneity of cardiomyopathic patterns and symptoms, their diagnosis and therapies are great challenges. Despite extensive research, the relation between the structural and functional abnormalities of the myocardium and the coronary circulation are still not well understood in the various forms of cardiomyopathy. The main pathological characteristics of cardiomyopathies and the coronary microcirculation develop in a progressive manner due to (1) genetic-immunologic-systemic factors; (2) comorbidities with endothelial, myogenic, metabolic, and inflammatory changes; (3) aging-induced arteriosclerosis; and (4) myocardial fibrosis. The aim of this review is to summarize the most important common pathological features and/or adaptations of the coronary microcirculation in various types of cardiomyopathies and to integrate the present understanding of the underlying pathophysiological mechanisms responsible for the development of various types of cardiomyopathies. Although microvascular dysfunction is present and contributes to cardiac dysfunction and the potential outcome of disease, the current therapeutic approaches are not specific for the given types of cardiomyopathy.

Key Words: dilated cardiomyopathy, ischemia, hypertrophic cardiomyopathy, restrictive cardiomyopathy, aging, coronary microvessels, nitric oxide availability, reactive oxygen species, inflammation, adhesion molecules, genetic diseases

(*Cardiology in Review* 2017;25: 165–178)

The coronary microcirculation is the major reservoir for myocardial blood supply, holding 90% of the total myocardial blood volume. Coronary blood flow is the result of a pressure difference between the aortic and coronary sinus where the epicardial coronary artery serves as a conductance vessel, whereas coronary arterioles

are the true intramyocardial regulatory components of blood flow. The differences in arteriolar diameter, reactive mechanisms, and myocardial perfusion are dependent on vascular endothelial and smooth muscle function and cardiac metabolic activity.^{1–3}

Coronary microcirculatory disease results from structural, functional, or their combined changes in the microcirculation. Alterations in the coronary microcirculation, which limit myocardial perfusion, can cause repetitive ischemic events, which usually present as typical acute or chronic symptoms and signs of myocardial ischemia with normal coronary angiograms (such as in microvascular angina), or as a part of some other cardiac process which can lead to cardiomyopathy and heart failure (HF).^{4–6} Pathogenic mechanisms that lead to coronary microcirculatory disease are as follows: (1) structural changes (vascular obstruction due to spasm, thrombosis, microemboli after percutaneous coronary intervention, infiltration, remodeling, hypertrophy); (2) vascular dysfunction (intramural arteriolar layer, endothelial and smooth muscle cell, autonomic nervous system); (3) extravascular changes (shortened diastolic filling, increased cardiac metabolism, compressive forces)^{7,8}; (4) aging process (sclerosis, fibrosis, extracellular matrix remodeling, intramyocardial fat infiltration)^{9–11}; and (5) immunomodulation after heart transplantation.¹² All these mechanisms, individually or combined, either functional or structural, lead to progressive, irreversible abnormalities resulting in some form of cardiomyopathy. Chronic changes in both growth factors and the inflammatory milieu with permanent cardiomyocyte necrosis and apoptosis, extracellular matrix remodeling, coronary microcirculation obliteration and cardiac fibrosis, indicate impairment of the integrity of the coronary microcirculation.^{2,9,13,14}

Figure 1 presents a proposed algorithm of the development of cardiomyopathies. The basic pathophysiological mechanism is usually ischemia, hypertension, or structural disease (such as deposition of collagen matrix, fibrosis, and similar), which primarily starts with changes of myocyte structure and function. Concomitant changes in the coronary microvasculature occur and lead to circulatory and perfusion imbalance in regard to functional myocardial needs. If the etiological factors persist, the microvascular adaptation becomes inadequate and the functional impairment becomes irreversible, leading to microvascular dysfunction, metabolic needs and blood delivery mismatch, structural changes of ventricular tissue and functional insufficiency. Impaired coronary blood flow occurs not only in coronary artery disease (CAD) but also in various myocardial diseases, such as in longstanding hypertension, hypertrophic cardiomyopathy (HCM), and infiltrative heart disease (eg, Anderson-Fabry CM).¹⁵

Myocardial diseases are associated with abnormal coronary microvascular structure and function, but the relation between myocardial and coronary microvascular structural and functional abnormalities in CMs, in terms of clinical symptoms presentation, has not been well understood.¹⁵ Unfortunately, there are no adequate animal models for CMs, therefore most of our knowledge is derived from human studies, preventing a deeper understanding of the responsible pathophysiologic mechanisms in the etiology of CMs. The aim of this present review is to summarize the most important findings regarding

From the *Department for Cardiovascular Diseases, Osijek University Hospital, Osijek, Croatia; †Department of Internal Medicine, Family Medicine and History of Medicine, Faculty of Medicine, Josip Juraj Strossmayer University of Osijek, Osijek, Croatia; ‡Department of Physiology and Immunology, Faculty of Medicine, Josip Juraj Strossmayer University of Osijek, Osijek, Croatia; §Department of Pathophysiology, Semmelweis University, Budapest, Hungary; ¶Institute of Natural Sciences, University of Physical Education, Budapest, Hungary; and †Department of Physiology, New York Medical College, Valhalla, NY. Supported by Hungarian National Science Research Fund, OTKA K108444 (to A.K.). Disclosure: The authors have no conflicts of interest to report.

Correspondence: Ines Drenjancevic, MD, PhD, Department of Physiology and Immunology, Faculty of Medicine, Josip Juraj Strossmayer University of Osijek, Cara Hadrijana 10E, HR-31 000, Osijek, Croatia. E-mail: ines.drenjancevic@mefos.hr.

Copyright © 2017 Wolters Kluwer Health, Inc. All rights reserved.

ISSN: 1061-5377/17/2504-0165

DOI: 10.1097/CRD.0000000000000140

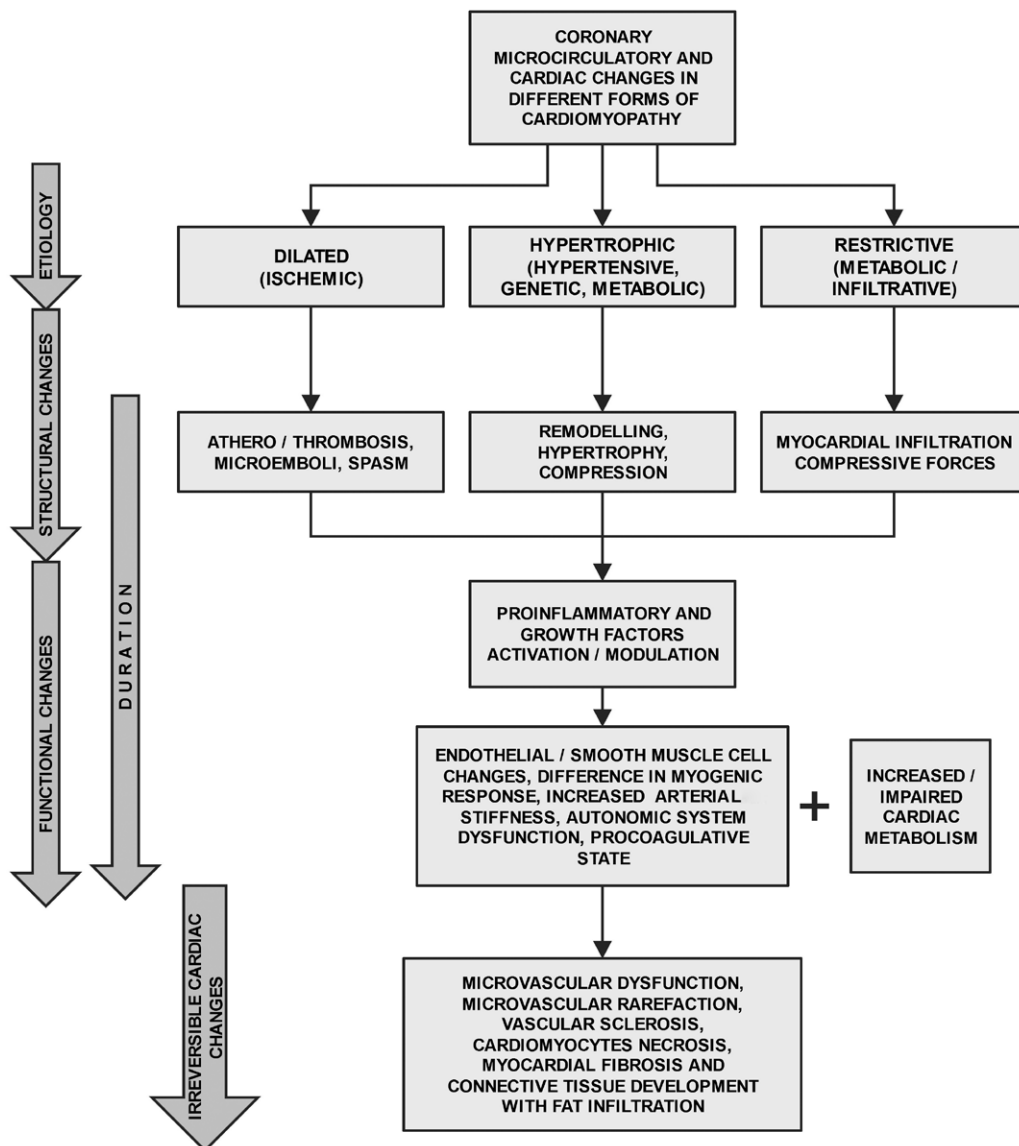


FIGURE 1. Proposed algorithm for the pathophysiology of the coronary microcirculation impairment found among different cardiomyopathies.

dysfunction of the coronary microcirculation found in several types of CMs in humans, and to present our recent understanding of their pathophysiological mechanisms. In addition, although the current therapeutic approaches are not specific for the given type of CM, we will highlight the potential therapeutic modalities.

HYPERTROPHIC CARDIOMYOPATHY

Primary: Idiopathic Hypertrophic Obstructive Cardiomyopathy

Primary HCM is a common inherited heart disease with a diverse genetic background and phenotypic expression. It has a wide spectrum of clinical presentations and natural history, ranging from asymptomatic to arrhythmic sudden cardiac death, progressive HF with exertional dyspnea and functional limitation, and paroxysmal or chronic atrial fibrillation with a risk of stroke.¹⁶

The hallmark of primary HCM is unexplained left ventricular hypertrophy (LVH, ≥ 15 mm for adults) without LV chamber dilatation that develops in the absence of pressure overload or storage/infiltrative processes. Usually this is an asymmetric hypertrophy involving the inter-ventricular septum, as opposed to the concentric hypertrophy found in aortic stenosis or hypertension.¹⁷

In the past, primary HCM was considered a rare disease, diagnosed mainly postmortem after sudden death or progressive HF in young individuals. Advances in diagnostic procedures, especially gene sequencing techniques, along with magnetic resonance imaging (MRI) and positron-emission tomography (PET) imaging techniques, have allowed for the early diagnosis among members of affected families and an increased recognition of the disease in clinical practice. As such, cardiac MRI has become a powerful complementary tool for identifying the various HCM phenotypes, based on its excellent strengths of tomographic imaging and improved spatial resolution.¹⁸

The current estimated prevalence of HCM among the general population ranges from 1/200 to 1/500; however, most genetically and clinically affected individuals are free from disease-related complications and remain undiagnosed.^{16,19,20} In addition, due to improved diagnostic approaches and treatment in recent years, the mortality rate of patients with HCM has considerably decreased to about 0.5% per year.¹⁶

Genetics

Primary HCM is inherited with an autosomal dominant Mendelian pattern, with variable expressivity, and incomplete age-related penetrance.^{21,22} The systematic testing of affected individuals and their family members has led to the recognition of more than 1500 individual mutations (90% missense mutations), with the majority of these found in 1 or only a few families.¹⁶ Intensive genetic research on HCM has resulted in the discovery of more than 11 genes affected by the mutations, including genes encoding for thick and thin contractile myofibrillar protein components of the sarcomere and adjacent Z-disc. Interestingly, almost 80% of identified mutations affect cardiac β -myosin heavy chain (*MYH7*) and cardiac myosin binding protein C (*MYBPC3*) genes.²³ The enormous diversity among mutations and genes responsible for HCM has limited their use in predicting the clinical outcome of HCM in affected individuals; nevertheless, genetic testing should be encouraged to continue identifying specific gene mutations responsible for causing HCM and at-risk relatives (genotype+, phenotype-) that should be followed up for a delayed disease onset.¹⁷

Coronary Microcirculatory Impairment in Primary HCM

Patients with HCM commonly present with symptoms and signs of myocardial ischemia whereas their coronary angiographic findings remain normal.²⁴ Myocardial ischemia found in primary HCM patients can lead to lethal complications of HCM, including sudden death, progressive LV remodeling, ventricular arrhythmias, and systolic dysfunction.²⁴ In addition, coronary microvascular dysfunction (CMVD) is an independent predictor of adverse LV remodeling, systolic dysfunction, and mortality in patients with HCM.⁸

Cokkinos et al^{25,26} were among the first to report an increased incidence of CAD in patients with HCM, and the basis of their clinical observation was soon attributed to alterations in small intramural coronary vessels, hypertrophy, and increased LV pressure. Histopathological assessment of the intramural coronary arteries revealed thickening of the vessel wall combined with luminal narrowing, as a result of media and/or intima proliferation, particularly the smooth muscle cell proliferation and collagen production.²⁷

Implementation of semiquantitative imaging techniques, the single photon emission computed tomography, and nuclear magnetic resonance spectroscopy, for the assessment of myocardial perfusion led to the discovery of an impaired vasodilator response and myocardial perfusion in primary HCM patients.^{28,29} Hampered myocardial perfusion during pharmacologically-induced stress or vasodilation (ie, to dipyridamole) was evident not only in the hypertrophied septum but also in the nonhypertrophied LV free wall, suggesting the presence of diffuse microvascular dysfunction in primary HCM.^{24,30–32} This is in line with a histological finding of arterial remodeling across the entire myocardium.²⁷ There is an increasing amount of evidence that mechanisms contributing to perfusion abnormalities include (1) increased vascular resistance due to reduced capillary density caused by hypertrophy and vascular remodeling, and (2) extravascular compressive forces caused by elevated LV cavity pressure and wall stress caused by diastolic dysfunction and outflow tract obstruction.^{33–35} In a study by Knaapen et al³³ in HCM patients, echocardiography assessed diastolic perfusion time, heart catheterization measured LV outflow tract gradient and LV pressures, and serum NH(2)-terminal probrain natriuretic peptide (NT-proBNP), as a biochemical marker of LV wall stress, was measured. An MRI was

performed to determine LV mass index (LVMI) and volumes. Hyperemic myocardial blood flow (MBF) was blunted in HCM versus controls (2.26 ± 0.97 vs 2.93 ± 0.64 mL/min/g, respectively; $P < 0.05$), and the endocardial-to-epicardial MBF ratio decreased significantly in HCM during hyperemia (1.20 ± 0.11 to 0.88 ± 0.18 , respectively; $P < 0.01$). Hyperemic MBF was inversely correlated with LV outflow tract gradient, NT-proBNP, left atrial volume index, and LVMI (all $P < 0.01$). Only LVMI and NT-proBNP were independently related to hyperemic MBF, with greater impact at the subendocardial myocardial layer. The level of impairment is related to markers of increased hemodynamic LV loading conditions and LV mass. These observations suggest that extravascular compressive forces become the predominant determinants of perfusion in a situation where the autoregulatory mechanisms of the microvessels are exhausted, such as during pharmacologically-induced maximum vasodilation.³³

Interestingly, Heffernan et al⁸ found that an impaired vascular response to stimuli in HCM was not restricted to the coronary vasculature. Based on flow-mediated dilatation (FMD) of the brachial artery, the investigators found lower FMD in patients with HCM compared with those without CAD ($P < 0.05$) but similar to FMD in patients with CAD (HCM $8.4 \pm 0.9\%$; CAD- $12.3 \pm 0.9\%$; CAD+ $9.1 \pm 0.9\%$; $P < 0.05$).⁸ Physiologic evidence on the precise vasodilator mechanisms in the coronary microcirculation of HCM patients is scarce; however, advances in functional imaging techniques have opened a new era for research opportunities in this field.

Secondary Hypertrophic Cardiomyopathy

Hypertensive HCM

Hypertensive heart disease is a well-studied phenomenon that is characterized by LVH leading to myocardial ischemia and systolic and diastolic dysfunction, and manifested by arrhythmias and symptomatic HF. The LV wall thickens in response to elevated blood pressure as a compensatory mechanism to minimize wall stress.^{36,37} Echocardiographic measurements of the ratio of the LV wall thickness to diastolic diameter (“relative wall thickness”) show 3 types of LVH in hypertensive patients: concentric (increased relative wall thickness), eccentric (the relative wall thickness is not increased), and concentric remodeling (the relative wall thickness, but not LV mass, is increased).³⁶ Pathohistologically, hypertensive LVH is characterized by myocyte hypertrophy, myocardial fibrosis, and structural changes of the intramural coronary arteries, including medial hypertrophy and perivascular fibrosis.^{36,38,39}

Coronary Microcirculatory Impairment in Hypertensive HCM

Hypertensive HCM is associated with important structural alterations of the vasculature, such as large artery stiffening, small artery remodeling, and microvascular rarefaction.^{39,40} The cross-sectional medial area of the arterioles, as well as the periarteriolar collagen area in hypertensive HCM, is significantly increased.⁴⁰ Functionally, there is impaired endothelium-dependent response to vasodilators and vasoconstrictors.^{38,41,42} Hamasaki et al⁴¹ have demonstrated that the vessel area of hypertensive patients with LVH (group 1) was significantly ($P < 0.01$) greater than that in hypertensive patients without LVH (group 2), but similar to the vessel area of normotensive patients (group 3) (12.8 ± 0.8 mm², 10.7 ± 0.4 mm², and 11.5 ± 0.3 mm², respectively). Coronary blood flow at baseline for patients in group 1 (with LVH) was significantly greater than it was for patients in groups 2 and 3 (81.1 ± 9.9 mL/min, 56.5 ± 6.2 mL/min, and 48.1 ± 3.2 mL/min, both $P < 0.05$). The vasodilator response to both acetylcholine and adenosine was significantly reduced in hypertensive patients with LVH compared with 2 other groups. All together, these results have demonstrated that hypertension with LVH is associated with both coronary vascular remodeling and attenuated endothelial and non-endothelial coronary flow reserve (CFR).⁴³

Thus, impaired coronary reserve is an early indicator of the conversion from the normal into the pathologic state.⁴² In study by Indermühle et al,³⁸ myocardial contrast echocardiography (MCE) was introduced as a noninvasive method for measurement of the MBF via determination of the underlying microvascular parameters, relative blood volume (a measure of the intravascular volume fraction), and its exchange frequency (a measure of the resistance to MBF). Hypertensive patients had a lower relative blood volume and a significantly higher exchange frequency compared with athletes or sedentary persons. MCE can differentiate between LVH in hypertensive heart disease and an athlete's heart.³⁸ Increased coronary microcirculatory resistance in hypertensive heart disease has been supported by quantitative MCE, in which isolated coronary microvascular abnormalities are evident by reduced CFR despite normal epicardial coronary arteries.⁴⁴ In another study, long-term therapy with the angiotensin converting enzyme inhibitor perindopril induced structural repair of coronary arterioles, which is mainly characterized by the regression of periarteriolar fibrosis and is associated with a marked improvement in coronary reserve,⁴⁵ supporting the importance of structural vascular changes in impaired myocardial function.

Lysosomal Storage Disease (Mb Fabry)

Genetics

Anderson-Fabry's disease is an X-linked lysosomal storage disorder caused by α -galactosidase A deficiency and subsequent globotriaosylceramide accumulation. Cardiac abnormalities are frequent and patients exhibit concentric nonobstructive LVH with end-diastolic wall thickness that is mildly increased, leading to LV systolic dysfunction as the disease progresses. Lipid storage is present in all the cells of the heart, including the myocytes, conduction system, heart valves, and the endothelium.⁴⁶ Classically, LVH manifests in the fourth decade; however, signs of cardiovascular disease are observed also later in life in "cardiac variant" patients and symptomatic female heterozygotes.⁴⁷

Coronary Microcirculatory Impairment in Anderson-Fabry Disease

Patients with Fabry disease have a very abnormal coronary microvascular function. They present with accelerated coronary atherosclerosis. Globotriaosylceramide is deposited in interstitial capillary endothelial cells and large, laminated inclusions within cardiomyocytes that have been associated with elevations in markers of endothelial injury and activation, leukocyte activation, and coagulation.^{48,49} In a study by Elliott et al,⁵⁰ mean MBFs at rest and during hyperemia (adenosine 140 μ g/kg/min) were measured in 10 male, nonsmoking patients (53.8 [10.9] years, cholesterol 5.5 [1.3] mmol/l) and in 24 age-matched male, nonsmoking controls (52.0 [7.6] years, cholesterol 4.5 [0.6] mmol/l) by PET. Resting and hyperemic MBF and CFR (hyperemic/resting MBF) were reduced in patients compared with controls (0.99 [0.17] vs 1.17 [0.25] mL/g/min, $P < 0.05$; 1.37 [0.32] vs 3.44 [0.78] mL/g/min, $P < 0.0001$; and 1.41 [0.39] vs 3.03 [0.85], $P < 0.0001$, respectively) and resting and hyperemic MBF and CFR were not affected by enzyme replacement therapy (MBF 0.99 [0.16] vs 0.99 [0.16] mL/g/min; 1.56 [0.29] vs 1.71 [0.3] mL/g/min; and CRF 1.6 [0.37] vs 1.74 [0.28], respectively). Results suggest that treatment in the earlier stage of the disease is needed to improve coronary microvascular function in these patients.

DILATED CARDIOMYOPATHY

Despite the advances in pharmacologic therapies and device interventions, dilated cardiomyopathy (DCM) is still a major cause of sudden cardiac death and HF, and is the leading indication for cardiac transplantation in children and adults worldwide.⁵¹ Its prevalence

is about 1:2500,⁵² and is clinically characterized by enlargement of 1 or both of the ventricles and associated with systolic dysfunction. Macroscopically, DCM consists of hearts that are heavy (increased LV mass) with geometric changes indicating eccentricity (defined as low relative wall thickness—eg, normal or reduced wall thickness in relation to dilated LV chamber size).⁵³ Microscopically, cardiomyocytes in DCM often consist of a classic histological triad—myocyte hypertrophy, myocyte loss, and interstitial fibrosis.⁵⁴ However, these findings are imprecise in identifying underlying etiologies for CMs.

Many diverse etiologies, either primary (genetic, mixed or predominantly familial nongenetic, or acquired) or secondary (inflammatory, autoimmune, or thyrotoxic) may lead to the DCM phenotype.⁵⁵ This disease can be diagnosed in association with recognized cardiovascular disease; however, to qualify as DCM, the extent of myocardial dysfunction cannot be explained exclusively by abnormal loading conditions (hypertension or valve disease) or ischemic heart disease. A diagnosis of DCM requires evidence of dilation and impaired contraction of the LV or both ventricles (eg, LV ejection fraction $<40\%$).⁵⁶

As mentioned above, a large number of cardiac and systemic diseases can cause systolic dysfunction and LV dilation, but in the majority of cases no definite cause is found. This has led to the common terminology of idiopathic DCM (IDCM).⁵⁵ IDCM is frequent and distinct from specific forms of the disease caused by toxic agents (ie, alcoholic CM), systemic (ie, diabetic CM), or other cardiovascular disorders (ie, ischemic CM). Although its incidence is not as high as that of other specific forms of DCM, it represents one of the most frequent indications for heart transplantation.⁵¹ The mechanisms involved in the progressive deterioration of cardiac function are largely unknown. Because of the epidemiologic and prognostic relevance of IDCM, intensive clinical and experimental research is ongoing to understand the mechanisms of the condition.

Primary Dilated Cardiomyopathy

Classical pathogenic mechanisms in IDCM include a genetic etiology, a viral etiology, and autoimmunity.⁵⁷ These pathogenic mechanisms may be considered the leading cause of IDCM in only a minority of patients in whom a clear genetic disease or viral myocarditis can be documented. However, even in these patients, progressive cardiac dilation and HF cannot be completely attributed to the same factors. Other mechanisms are more likely involved, both in the genesis of the disease and in its progression.

Coronary Microcirculatory Impairment in DCM

It has been hypothesized that impairment of the coronary blood flow has a potential role in the pathogenesis of IDCM. This hypothesis is derived from the common clinical observations that CM patients frequently come to the attention of physicians before the occurrence of overt HF, because of chest pain symptoms or ventricular arrhythmias. Horwitz et al⁵⁸ first demonstrated a decreased response of coronary blood flow to an isoproterenol infusion in IDCM patients, and many investigators thereafter documented impaired coronary reserve in response to different stimuli.⁵⁹ In 1987, Yamaguchi et al⁶⁰ reported regional wall motion abnormalities and resting and stress-induced perfusion defects detected by stress perfusion scintigraphy in DCM. These findings commonly suggest the presence of coronary artery stenosis, which is not seen at cardiac catheterization in these patients. However, abnormalities at the coronary microvascular level might similarly be responsible for these observations. In this context, Cannon et al⁶¹ found that DCM patients with chest pain showed an increased sensitivity of coronary microvessels to vasoconstriction as compared with those having no chest symptoms. Furthermore, 3 years later, Treasure et al⁶² demonstrated impaired relaxation of the coronary microcirculation in response to intracoronary infusion of the endothelium-dependent vasodilator acetylcholine (measured by Doppler catheter) in patients with DCM. They postulated that there

might be pathogenic links between dysfunction of the endothelium and myocardial failure.

In CMs, alterations of the coronary microvascular component may also be secondary to the structural and functional alterations of the myocardium, or damage to the coronary microcirculation may be a cause of the CM progression and HF development. In HCM, as in hypertension, structural alterations of the microvessels, characterized by hypertrophy of the arteriolar wall, can be documented.²⁷ However, in explanted hearts from patients with end-stage HF due to DCM, MBF is severely reduced at rest, independently of myocardial fibrosis which does not involve more than 20% of the myocardial mass.⁶³ Furthermore, in DCM, similar structural abnormalities like those in HCM have never been demonstrated, hence much evidence exists in favor of functional abnormalities of the coronary microvasculature.

As mentioned above, an increasing number of different clinical studies have demonstrated an impaired response of the coronary microvasculature to the endothelium-dependent vasodilator⁶² as part of a systemic alteration of the vascular endothelium.⁶⁴ Thus, it has been proposed that an impairment of coronary endothelial function may be responsible for the marked decrease in CFR. Endothelial dysfunction is able to limit the coronary vasodilator response to stress and to cause an imbalance between myocardial oxygen demand and blood flow delivery. A relevant question is whether endothelial dysfunction arises late in the natural history of the disease, as a consequence of HF, or may occur earlier, participating in the progression of ventricular dysfunction toward HF. An answer to this question was provided by the studies of Neglia and L'Abbate⁵⁷ who reported LV MBF impairment in patients with DCM before clinical and hemodynamic evidence of HF. MBF values were reduced at baseline or in response to stress in most of the patients studied (82%) and even in the presence of normal LV end-diastolic volumes. These results demonstrate that myocardial perfusion may be abnormal in IDCM patients even before the occurrence of hemodynamic changes that can further limit blood flow delivery to the myocardium.⁵⁷ Moreover, the severity of MBF abnormalities (probably due to primary coronary microcirculatory dysfunction), is able to predict the evolution of the disease toward progressive ventricular dysfunction and HF.⁶⁵ It becomes more evident that an understanding of the changes of the pathological microcirculation at different stages of IDCM could provide a reliable background for making proper therapeutic decisions.

The most recent study from 2015 has shown that the condition of the coronary microcirculation corresponds with the progression of HF in patients with IDCM.⁶⁶ Another research group reported that altered function of the subresolution intramyocardial microcirculation can be quantified by myocardial perfusion computed tomography and that significant changes in these parameters occur in IDCM subjects with LV wall thickness >11.5 mm.⁶⁷

Therefore, it is now more evident that IDCM is characterized by dysfunction of the coronary microvessels related to its very early onset. Recent studies have shown that coronary microcirculatory dysfunction is not due to myocardial damage, but it seems to be the cause of progressive contractile impairment, ventricular dilation, and HF.^{57,64-66} Because the coronary microcirculation is involved in the pathogenesis of IDCM, it should be considered as a new target for the treatment of those cardiac diseases that evolve in the development HF.

Secondary Dilated Cardiomyopathy

Ischemic DCM

Ischemic CM is an anatomic condition emanating from a sustained imbalance between oxygen supply and demand of the heart, which, in turn, leads to myocyte loss with resultant myocardial scarring and ventricular failure. Cell loss can occur as a result of (a) focal narrowing or occlusion of the main coronary arteries by atherosclerosis, (b) spasm of the epicardial or intramural branches

of the coronary circulation (CAS), and (c) primary CMVD. These pathological processes affecting the large, intermediate, and small-sized arteries and arterioles, and the capillary microcirculation, are responsible for a variety of clinical conditions ranging from acute myocardial infarction to chronic ischemic CM.⁶⁸ Patients with ischemic CM cannot be distinguished from those with IDCM by clinical features. Coronary angiography is recommended for patients without a defined etiology for their DCM or for those in whom an endomyocardial biopsy demonstrates replacement fibrosis.⁶⁹

Atherosclerosis

Atherosclerosis is the major cause of ischemic heart diseases. Originally thought to be dominantly a lipid storage disease, our current understanding of the pathogenesis of atherosclerosis implicates endothelial injury and inflammation.⁷⁰ In the largest diameter epicardial coronary vessels, coronary blood flow is primarily limited due to obstructive atherosclerotic CAD. Inflammation-induced atherosclerosis does not occur linearly. Instead, bursts of atherosclerotic plaque progression occur and are triggered by physical disruption to endothelial cells, hemorrhage into the plaque, clot formation, and vascular remodeling. As atheromatous plaque continues to increase, deposition occurs principally within the vascular wall, with compensatory enlargement of the external diameter of vessel. This positive outward vessel remodeling phenomenon, described by Glagov et al,⁷¹ permits maintenance of the lumen size and delays stenosis until the plaque occupies 40% of the internal elastic lamina area. Once this compensatory mechanism is exhausted, the plaque begins to bulge into the lumen, causing obstruction of coronary blood flow, which becomes important during periods of increased oxygen demand.⁷¹ However, this notion is in sharp contrast with the observation that about 40% of patients with ischemic CM have low or very low plasma levels of C-reactive protein, a very sensitive marker of inflammation.⁷⁰ In these patients, other mechanisms are likely to play key pathogenic roles, which include extreme emotional disturbance, and local mechanical stress at the level of the arterial wall, that is, both circumferential stress and shear stress.⁷²

Abela et al⁷³ proposed an intriguing working hypothesis that shifts in environmental factors, including local saturation of cholesterol, temperature, pH, and hydration status, could alone or in various combinations lead to cholesterol crystallization with sudden and forceful volume expansion causing plaque fissure and thrombosis. Intraplaque hemorrhage can enhance this mechanism by triggering the crystallization of free cholesterol from erythrocyte membranes, causing abrupt enlargement of the necrotic core.⁷⁴ Although elevated low-density lipoprotein cholesterol still remains a major contributor to atherosclerosis and adverse ischemic heart disease events, therapies which target low-density lipoprotein reduced coronary events by only 33% over a 5-year treatment period. This observation has led to the conclusion that additional chemical and mechanical insults also trigger endothelial injury, including altered shear stress, high oxidative stress, smoking, and insulin resistance.⁷⁵

Coronary Microcirculatory Impairment in Ischemic DCM

The role of abnormalities of the microcirculation as a cause of atherosclerotic heart disease is less well established, and it is traditionally accepted that the microcirculation is not affected by the atherosclerotic process. Although the microcirculation does not exhibit gross atherosclerotic lesions, they show altered responses to pharmacological stimulation by endothelium-dependent agonists. The results of studies on animal models indicate that coronary microvessels that do not develop lesions are nevertheless exposed to the abnormally high levels of circulating lipid and circulating cholesterol incorporated into specific lipoproteins, which may be a sufficient pathological stimulus to produce the observed attenuated endothelium-dependent vasodilation to adenosine triphosphate (ATP), histamine, and serotonin,

as well as an absent FMD of coronary arterioles.⁷⁶ An impairment of endothelial function could have 2 important consequences in the coronary circulation: first, as the mechanism preceding and leading to the development of atherosclerosis of the epicardial vessels, and second, as a mechanism responsible for vasoconstriction (or reduced vasodilation) of the segment of the coronary microvasculature under endothelial control.⁷⁷

Primary Coronary Microvascular Dysfunction

Myocardial ischemia can produce anginal chest pain without angiographically obstructive CAD, often due to CMVD. Autopsy reports in patients with normal angiograms and angina pectoris have revealed myointimal proliferation, endothelial degeneration, and lipid deposits in the microvasculature.⁷⁸ Coronary blood flow abnormalities and the consequent myocardial alterations related to CMVD may differ substantially from those caused by flow-limiting stenosis in large coronary arteries. In the latter case, the impairment of myocardial perfusion is homogeneously distributed within the myocardial layers perfused by the stenosed artery, resulting in detectable segmental impairment of contractile function. In contrast, in the case of CMVD, the abnormality may not involve all coronary microvessels of a major coronary branch uniformly, but may be distributed in the myocardium in a scattered manner.^{1,4} Structural abnormalities of small coronary arteries have been described, including smooth muscle hypertrophy,⁷⁹ but other studies have failed to show significant structural alterations.

Functional abnormalities of coronary resistance vessels have instead been reported in a large number of studies. An impairment of endothelium-dependent vasodilation due to reduced nitric oxide release is among the most commonly proposed mechanisms of CMVD and it has been suggested to occur mainly by a reduced coronary blood flow response to acetylcholine.⁸⁰ Furthermore, some evidence for endothelial progenitor cell abnormalities has also been suggested.⁸¹ However, the reduced endothelium-dependent vasodilation does not seem to fully account for CMVD. Because of the potential direct vasoconstrictor effects of acetylcholine, tests with this drug are, in fact, not highly specific for the assessment of endothelial function, and in some studies the metabolic pathway of nitric oxide did not seem to be affected.⁸² Moreover, the reduced coronary blood flow response to endothelium-independent vasodilators (eg, adenosine, dipyridamole, papaverine) has been reported repeatedly,⁸³ suggesting an important role for a primary impairment of smooth muscle cell relaxation.

Coronary Artery Spasm

CAS is defined as the abnormal contraction of an epicardial coronary artery resulting in myocardial ischemia. The causes and the mechanisms underlying the development of CAS are still poorly defined and are likely to be multifactorial. In the 1980s, the autonomic nervous system was found to play an important role in the pathophysiology of CAS.⁸⁴ In the 1990s, inflammation, endothelial dysfunction, oxidative stress, respiratory alkalosis, and magnesium deficiency were identified as predisposing factors.⁸⁵ In the late 1990s and early 2000s, genetic mutations were found to be associated with CAS.⁸⁵ Nonetheless, coronary vascular smooth muscle cell hyperactivity seems to constitute the basis or reason for CAS. Inflammation is thought to initiate vascular damage as patients with CAS tend to have higher levels of circulating leukocytes, C-reactive protein, and interleukin-6 (IL-6), as compared with control populations. Inflammatory mediators promote smooth muscle cell migration into the intima. Endothelial damage exposes smooth muscle cells to agents that cause vasoconstriction.⁸⁶ However, the direct involvement of the coronary microcirculation in CAS is not clear.

Myocarditis

Myocarditis represents a nonischemic inflammatory heart disease with a highly variable clinical outcome. The major long-term consequence of myocarditis is inflammatory DCM.⁸⁷ Moreover, in the WHO 1996 classification of cardiomyopathies, inflammatory DCM was included as a subtype of the specific cardiomyopathies and defined as “myocarditis associated with cardiac dysfunction.”⁵⁶ Infectious causes of DCM are predominantly viruses, most commonly the Coxsackie viruses, especially group B Coxsackie viruses. Other viruses include various respiratory tract viruses, cytomegalovirus, parvovirus, mumps virus, and hepatitis C virus. Endomyocardial biopsy represents the standard for the *in vivo* diagnosis of myocarditis, and should be considered in patients with unexplained cardiac dysfunction of recent onset.⁸⁷

Coronary Microcirculatory Impairment in Myocarditis

Most studies investigating the pathophysiological link between myocarditis and later inflammatory DCM have focused on intramyocardial infiltrates. However, endothelial cells are probably infected before cardiotropic viruses invade the myocardium. Thus, it was hypothesized that endothelial inflammation may have an important role in the pathogenesis of an inflammatory DCM progression. This hypothesis was confirmed by Noutsias et al⁸⁸ who brought evidence for endothelial activation in inflammatory DCM. They have reported that inflammatory endothelial activation is present in 67% of DCM patients. The immunohistological evaluation of myocardial biopsies in patients with myocardial inflammation (myocarditis) demonstrated a myocardial lymphocyte infiltrate and endothelial activation that can be detected by enhanced expression of cell adhesion molecules (CAMs). Thus, the vessel wall is involved in the inflammatory process. Klein et al⁸⁹ reported diminished coronary reserve due to reduced coronary vasodilator capacity in patients with biopsy-proven inflammatory infiltrates. Several studies reported that in these patients, endothelial activation [estimated by the increased level of soluble intercellular AMs (ICAM-1) or an enhanced expression of human leukocyte antigen] of peripheral arteries correlated with endothelial expression of inflammatory markers in myocardial biopsies.^{90,91} Subsequently, Vallbracht et al^{92,93} aimed to investigate the impact of myocardial virus persistence in patients with inflammatory DCM on endothelial function. They have found a relationship between the presence of viral myocardial disease and an impaired FMD of systemic arteries.

Thus, it became evident that myocardial inflammatory immune responses observed in patients with inflammatory DCM are associated with reduced coronary blood flow and increased coronary resistance, as well as with impaired FMD in systemic arteries. Moreover, further studies have demonstrated that inhibition of inflammation (demonstrated as decreased serum ICAM-1, C-reactive protein, and von Willebrand factor levels), alleviating impaired FMD of the brachial artery, and LV ejection fraction might comprise part of the underlying mechanisms leading to the improvement of LV function in patients with inflammatory DCM.⁹⁴

The results from the above mentioned studies suggest that endothelial function of the coronary microcirculation is impaired in patients with myocardial virus persistence and in patients with myocardial leukocyte infiltrates and endothelial activation. This finding may be clinically important, as endothelial function represents an important predictor of prognosis and may influence therapeutic decisions in patients with inflammatory DCM.

RESTRICTIVE CARDIOMYOPATHY

The definition of restrictive cardiomyopathy (RCM) is based on hemodynamic abnormalities (myocardial relaxation abnormality), characterized by impaired ventricular filling and diastolic HF.

Restrictive filling is due to higher diastolic pressure and causes passive venous congestion. RCMs may be classified as primary [endomyocardial fibrosis (EMF)] or secondary (caused by infiltrative diseases, such as amyloidosis, sarcoidosis, and storage diseases, such as hemochromatosis, Fabry's disease).⁸⁷

Endomyocardial Fibrosis

EMF is a RCM of unknown etiology, having a poor prognosis. It is geographically restricted to some economically poor regions of Africa, Latin America, and Asia, affecting primarily children and adolescents.⁹⁵ The major risk factors for developing EMF seem to be age, ethnicity, poverty, cassava, magnesium deficiency, autoimmunity, and eosinophilia.⁹⁶ The primary target of injury in EMF is not known. It has been suggested that the endomyocardial lesions may be the result of a primary injury to the endocardial endothelium, subendocardial fibroblast, coronary microcirculation, or myocytes.⁹⁷ Antibodies against myocardial proteins were demonstrated in a subset of EMF patients.⁹⁸

The pathological hallmark of established EMF is focal or diffuse endocardial thickening. Right ventricular (RV) EMF is the most common form of presentation,⁹⁹ either in isolation or as part of biventricular disease. Microscopically, there is deposition of dense fibrous tissue underneath the endothelial layer of the endocardium with superimposed thrombosis and calcification in advanced stage.¹⁰⁰ Examination of intramural coronary arteries may show involvement with medial degeneration, deposition of fibrin, and fibrosis.¹⁰¹ Macroscopically, there is cardiomegaly due to severe atrial dilatation that is related to both impedance of ventricular filling and massive atrioventricular valve regurgitation.¹⁰² The LV apex is frequently scarred and thrombosed, but never contracted. The semilunar valves and the great vessels are usually not involved. The pulmonary valve and arteries are spared from the fibrotic process.^{96,103}

The pathophysiology of EMF is associated with the restriction of diastolic filling of the ventricle, caused by endocardial fibrosis, with severe atrioventricular valve regurgitation. The endocardial scarring of the RV wall not only reduces ventricular cavity size and impedes adequate filling but also impairs systolic function to a variable degree.¹⁰⁴ The process usually does not involve the epicardium, and coronary artery obstruction is distinctly uncommon.¹⁰¹ Myocardial fibrosis increases the stiffness of the heart and results in atrial enlargement which is linked to atrial arrhythmias (atrial fibrillation occurs in more than 30% of patients with EMF).¹⁰⁴ Poor vascularization in the apices may result in failure of cardiac cell repair, endomyocardial degeneration, and fibrosis, which lead to thrombosis and thromboembolism. In right-sided cases, patients remain asymptomatic for long periods.¹⁰⁵ There is an increase in pressure inside the right atrium that is transmitted backwards to the systemic veins and is responsible for some characteristic signs of this condition.^{104,106} LV EMF presents with severe pulmonary hypertension and RV EMF presents with very high systemic venous pressure and congestive cardiac failure.^{107,108}

Coronary Microcirculatory Impairment in EMF

There are many studies that have investigated the appearance of the heart, but little is known about the microvasculature in EMF. Some studies have shown that coronary blood flow was normal,¹⁰⁹ whereas other studies reported that generalized tortuosity of the coronary arteries, considered to be a nonspecific change associated with ventricular enlargement and hypertrophy, was seen in 50% of patients.¹¹⁰ The findings of Farrer-Brown et al¹¹¹ suggest that a vascular pathology is unlikely. No significant abnormality was seen in the medium sized or large portions of coronary arteries, only occasionally small abnormal vessels were present, and these were within fibrous tissue in the subendocardial zone or in papillary muscle, where the "straight" type arteries entering the base of the papillary muscles might have been constricted by surrounding endocardial fibrosis. Initially, the endocardial vascularization is dense with an irregular network of

capillary-like vessels, but at a later stage, the fibrous tissue becomes devascularized and relatively few vessels remain.¹¹¹

Due to a lack of conclusive data, more attention should be directed at establishing the condition of the coronary vasculature and its changes in structure, as well as in blood flow, due to EMF.

Systemic Diseases

A number of systemic diseases can lead to RCM, where the infiltration of the heart by abnormal substances is the hallmark of the pathophysiologic process.¹¹² The most relevant diseases include amyloidosis, sarcoidosis, and hemochromatosis/iron overload, but there are also other conditions that can lead to infiltrative CMs, such as systemic sclerosis or the aforementioned Fabry disease (which besides inducing hypertrophy, leads also to RCM because of glycosphingolipid infiltration into the myocardium).^{112,113} Infiltrative processes lead to increased stiffness of the myocardium that causes pressure within the ventricle to rise sharply with only a small increase in volume.¹¹³ There are few data about coronary microvascular changes in RCMs being associated with systemic disease.

Amyloidosis

Amyloidosis, a disorder of protein metabolism in which abnormal extracellular proteins are deposited in organs and tissues, is the most common cause of RCM.¹¹³ Amyloid deposition, which begins in the subendocardium with focal amyloid accumulations and extends within the myocardium between the muscle fibers, can cause both diastolic and systolic LV dysfunction and interstitial infiltration of the atria and ventricles, leading to a firm and "rubbery" consistency of the myocardium in the most advanced cases.¹¹³ The walls of intramural coronary arteries, as well as the conductive system, are also infiltrated,¹¹³ with histochemical and electron microscopic observations showing that light chain deposits can also form layers adjacent to plasma membranes of arteriolar endothelial and smooth muscle cells and neural elements.¹¹⁴ The major types of amyloidosis, defined by their precursor proteins, are (a) primary amyloid light chain amyloidosis where cardiac involvement is common, (b) secondary amyloidosis (amyloid A), (c) hereditary transthyretin-derived amyloidosis, (d) age-related amyloidosis, and (e) isolated atrial amyloidosis.^{112,113,115} Effort angina is common in patients with cardiac amyloidosis, even in the absence of occlusive CAD. Dorbala et al⁷ conducted rest and vasodilator stress N-13 ammonia PET and 2-dimensional echocardiography on cardiac amyloidosis patients without epicardial CAD. Global LV MBF at rest and during peak hyperemia and CFR were determined, with amyloidosis patients showing lower resting MBF, stress MBF, and CFR and higher minimal coronary vascular resistance compared with hypertensive LVH patients. Almost all subjects with amyloidosis (>95%) had significantly reduced peak stress MBF.

Coronary Microcirculatory Impairment in Amyloidosis

The data have shown that CMVD is highly prevalent in subjects with cardiac amyloidosis.⁷ In their experiments on cannulated human adipose arterioles and atrial coronary arterioles, Migrino et al¹¹⁶ found that amyloidosis light chain proteins cause microvascular dysfunction, as well as apoptotic injury of coronary artery endothelial cells as a result of oxidative stress, reduced nitric oxide bioavailability, and increased peroxynitrite production. MCE (useful in the evaluation of flow in the microvasculature, detecting microbubble contrast agents that are solely confined to the intravascular space) suggested a reduction in total MBF and reserve values in biopsy-proven primary cardiac amyloidosis and angiographically-normal coronary arteries.¹¹⁷

Sarcoidosis

Sarcoidosis, a multisystemic granulomatous disease of unknown etiology that may affect organ systems (most often lungs,

eyes, and skin), can lead to infiltrative CM. Sarcoid granulomas may persist, resolve, or lead to fibrosis, causing regional LV dysfunction and/or impaired diastolic function to a variable extent from impaired relaxation to restrictive filling in the most advanced cases. Systolic dysfunction predominates in later stages.^{112,113}

Coronary Microcirculatory Impairment in Sarcoidosis

Data regarding the cardiac microvascular function in sarcoidosis are limited. For example, in addition to inflammation and tissue destruction, endothelial dysfunction and arterial wall properties are also believed to play a role in the pathophysiology of sarcoidosis, including cardiac, ocular, and other manifestations, as suggested by decreased brachial artery FMD and increased arterial stiffness.^{118,119} A significant correlation of serum levels of intercellular ICAM-1 and tumor necrosis factor alpha with augmentation index (as a measure of arterial wave reflections) suggests a correlation between inflammatory processes and vascular function impairment.¹¹⁹ Studies of cytokine expression in cardiac sarcoidosis determined that type 1 helper T-cell cytokines may be involved in the pathogenesis, with enhanced mRNA expression in the myocardium. Immunohistochemistry of the myocardial tissue in sarcoidosis showed positive staining for IL-12 and interferon-gamma. IL-12 was localized in multinucleated giant cells and macrophages of the sarcoid granulomas, whereas interferon-gamma was detected in lymphocytes and vascular endothelial cells.¹²⁰ Rafiq et al¹²¹ presented a case report linking sarcoidosis to microvascular angina in a 41-year-old woman. The patient had a history of anginal symptoms for years, with a normal coronary angiogram, and an electrocardiogram exercise-induced inferior ST segment depression of 2 mm at 6 min was associated with pain (modified Bruce protocol).¹²¹ In a study by Tellier et al,¹²² the significance of anginal pain and myocardial thallium-201 scan defects in cardiac sarcoidosis was investigated. These investigators performed thallium-201 myocardial scintigraphy at rest and after 0.56 mg/kg intravenous dipyridamole at 4 min in 16 patients with sarcoidosis. Thirteen of the 16 patients demonstrated partial or total reversal of their thallium-201 defects on redistribution scanning either at rest or after dipyridamole. They concluded that the reversibility of defects makes the role of scar fibrosis or extensive confluent granulomas as a mechanism for such defects unlikely, and that the effect of dipyridamole suggests the presence of reversible disorders lying at the coronary microvascular level.¹²²

Hemochromatosis

Hereditary hemochromatosis (where mutations in various iron homeostasis signaling genes such as *HFE* cause dysregulation of iron absorption), as well as other states with iron overload (such as increased catabolism of erythrocytes in transfusion iron overload etc.), lead to fibrosis in many tissues. In the heart, this manifests as myocardial fibrosis and impaired ventricular function with either a restrictive type or DCM.¹¹³ In iron overload CMs, deposition of excess iron begins in the epicardium and then progresses into the myocardium and endocardium, with formation of reactive oxygen species, lipid peroxidation, membrane permeability alteration, and myocyte death.¹¹²

Coronary Microcirculatory Impairment in Hemochromatosis

Marques et al¹²³ demonstrated that chronic iron overload is associated with altered vascular reactivity and the loss of endothelial modulation of vascular tone. They used rat aortic rings as an experimental model after the animals were treated with 100 mg/kg/day iron-dextran, 5 days a week for 4 weeks. Iron overload significantly increased the vasoconstrictor response, with reduced influence of endothelial denudation or N-nitroarginine methyl ester (L-NAME) incubation on aortic vascular reactivity. An in vitro assay with 4,5-diaminofluorescein indicated reduced nitric oxide production in the iron overload group, and indicators of oxidative stress were

elevated. Iron overload-induced vascular hyperactivity was reversed by incubation with tiron, catalase, apocynin, allopurinol, and losartan (possibly suggesting an important role of local renin-angiotensin system activation).¹²³ Hereditary hemochromatosis patients were shown to have decreased endothelium-dependent dilation of the brachial artery and increased intima-media thickness of the carotid artery, which was positively correlated with iron overload and indicators of oxidative stress, whereas iron depletion therapy can normalize endothelial function.¹²⁴ Direct experiments investigating endothelial function in the coronary microvascular bed in iron overload have, to our knowledge, not yet been published.

AGING-INDUCED CARDIOMYOPATHY

Age is one of the main risk factors for cardiovascular disease and HF, but the exact mechanisms are not fully understood.¹²⁵ The pathogenesis of cardiovascular diseases share common mechanisms with those of aging. The prevalence of cardiovascular diseases starts to increase at the age of 60.¹²⁶ Two main processes underlie aging mechanisms: limited capacity for regeneration, and genetic determinants of the cardiomyocytes.^{127,128} The changes are due to necrosis and apoptosis with reduced regenerative possibilities of cardiac progenitor cells.¹²⁹

From physiologic and pathophysiologic points of view, oxidative stress, DNA damage, insulin signaling, inflammation, protein homeostasis, and caloric restriction are the key point for understanding molecular pathways related to CM in aging.¹²⁵ At the cellular level, the main findings are myocyte hypertrophy, interstitial fibrosis, microvascular rarefaction, increased stiffness, systemic and myocardial inflammation, and intramyocardial fat deposition.¹³⁰⁻¹³³

Coronary Microcirculatory Impairment in Aging CM

Comorbidities, besides genetic and regenerative predisposition, are the key for a systemic proinflammatory state, microvascular endothelial inflammation, and an impairment in nitric oxide signaling, inflammatory cell infiltration, and profibrotic cytokine production, resulting in altered extracellular matrix, and diminished cardiomyocyte and microvascular function.^{9,134} Hanna et al¹³⁵ reported that arteriolar stiffness and impaired myogenic responsiveness in coronary resistance arteries are advanced with age. At the clinical level, aging heart CM presents with impaired LV relaxation, increased diastolic stiffness, left atrial remodeling, fibrosis of the cardiac conduction system, and valve calcification.^{9,125} Increased LV stiffness is attributable to fibrosis, altered cardiomyocytes, microvascular rarefaction, chronic ischemia, and scarring, resulting in various forms of CMs, with reduced EF or with preserved EF.^{136,137}

DISCUSSION AND CONCLUSION

In clinical practice, physicians encounter patients with chest discomfort symptoms resembling anginal pain, often with elevated cardioselective enzyme concentration, but without clear electrocardiogram changes consistent with acute coronary syndrome. At admission, these patients' coronary angiograms often show normal epicardial coronary artery morphology, or only insignificant atherosclerotic changes (except, of course, in ischemic cardiac disease), whereas echocardiography shows an altered myocardium consistent with various CMs. Because the coronary microcirculation cannot be readily imaged in routine practice, one may ask where the pathophysiological or pathomorphological origin of the disorder is, which manifests as "angina like chest pain." It seems that the answer is in the microcirculation, where a unifying pathophysiology may explain seemingly homogenous clinical presentation across CMs. Figure 2 depicts the potential or hypothetical factors in CMs influencing the most important mechanism that govern coronary microcirculatory homeostasis. The gear wheels represent the normal interactions of

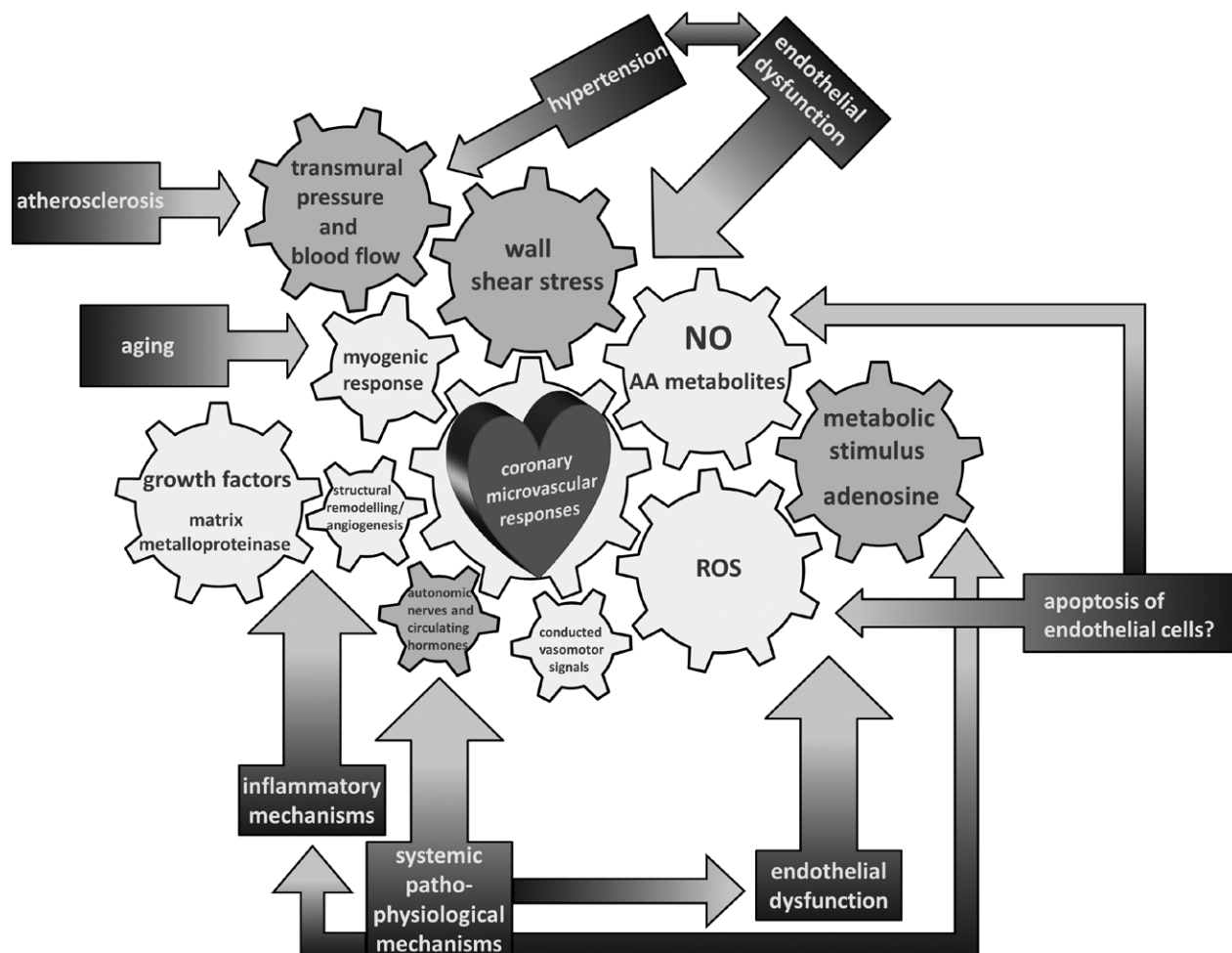


FIGURE 2. The potential or hypothetical factors responsible for the development of cardiomyopathies and influencing the most important mechanisms that govern coronary microcirculatory homeostasis. AA indicates arachidonic acid; NO, nitric oxide; ROS, reactive oxygen species.

physiological stimuli and mediators that govern coronary microvascular responses, maintaining microcirculatory homeostasis in the coronary vascular bed. Endothelial factors, the most important being nitric oxide, arachidonic acid metabolites, and other possible endothelial-derived hyperpolarizing factors (EDHFs) directly affect coronary microvascular responses, but also have effects on each other. Wall shear stress leads to microvascular dilation via nitric oxide, and is itself affected by hemodynamic factors. Metabolic stimuli regulate microvascular responses partly through endothelium-dependent mechanisms such as nitric oxide, but also through other mechanisms (adenosine, which can itself be considered an EDHF). Metabolites produced in proportion to oxidative metabolism, such as reactive oxygen species, can also control coronary microcirculatory blood flow. The blue arrows emphasize processes that disrupt this normal interaction of microcirculatory control mechanisms. For instance, endothelial dysfunction in various CMs disrupts normal nitric oxide control mechanisms (reduced bioavailability etc.) and EDHF and reactive oxygen species functioning. Another example of disruptive processes is inflammation, which can lead to changes in humoral factors, growth factors, etc. which normally control structural remodeling and angiogenesis (resulting, for instance, in vascular rarefaction). Structural changes can in turn cause functional changes.

Table 1 presents a list of coronary microcirculatory impairments described in various types of CMs. Certain common microvascular functional changes, such as an impaired endothelium-dependent response to vasodilators and vasoconstrictors, as well as an increase in microcirculatory resistance and a decrease in flow reserve, are encountered in primary and secondary HCM and DCM, in some forms of RCM and also in aging CM. Furthermore, inflammation is an important component of microcirculatory changes in CMs as a result of systemic diseases (lysosomal storage disease CM or in sarcoidosis with resulting RCM) and also in myocarditis. Changes of hemodynamics (pressure and volume load) caused by a CM can then manifest as clinical symptoms and present a significant challenge in diagnosis and management. Although microvascular function is significantly affected in every type of CM, and contributes to the clinical presentation of patients' symptoms and potential outcome of disease, a current therapeutic approach does not include specific treatments of CMVD in any of the listed CMs (Table 1, third column).

Because CMs may present with common features in relation to microcirculatory function (Fig. 3), an important question is whether the damage of the coronary microcirculation is a cause or a consequence of CM progression and HF development. The answer to this question is still unresolved or a question, which should be answered by future investigations.

TABLE 1. List of Coronary Microcirculatory Impairment Described in Various Types of Cardiomyopathies

Cardiomyopathies	Coronary Microcirculation Impairment	Possibility to Modify Outcome by Therapy Importance in Prognosis of Disease
Hypertrophic		
Primary: idiopathic HCM	<ul style="list-style-type: none"> - Increased vascular resistance due to reduced capillary density caused by hypertrophy and vascular remodeling, and - Extravascular compressive forces caused by elevated LV cavity pressure and wall stress 	<ul style="list-style-type: none"> - Therapy not related to microvascular function: Therapy of adverse HCM complication, including surgical myectomy or selective septal ablation by alcohol to reduce outflow obstruction, catheter-based procedures to control atrial fibrillation, implantable cardioverter-defibrillators for sudden death prevention and heart transplantation in the case of end-stage heart failure¹⁶
Secondary: hypertensive CM	<ul style="list-style-type: none"> - Small artery remodeling and microvascular rarefaction - Cross-sectional medial area of arterioles and the periarteriolar collagen area significantly increased, periarteriolar fibrosis - Impaired endothelium-dependent response to vasodilators and vasoconstrictors - Increased coronary microcirculatory resistance, decreased coronary flow reserve 	<ul style="list-style-type: none"> - Angiotensin converting enzyme inhibitors shown to decrease periarteriolar fibrosis which is associated with a marked improvement in coronary reserve⁴⁵
Secondary: lysosomal storage disease CM (Mb Anderson-Fabry)	<ul style="list-style-type: none"> - Accelerated coronary atherosclerosis; - GL-3 deposits in interstitial capillary endothelial cells - Elevations in markers of endothelial injury and activation, leukocyte activation, and increased coagulation 	<ul style="list-style-type: none"> - Enzyme replacement therapy not successful in microvascular function repair - Necessity of start at the onset of disease?⁵⁰
Dilated		
Primary DCM	<ul style="list-style-type: none"> - Myocardial blood flow severely reduced at rest independently of myocardial fibrosis → functional abnormalities of the coronary microvasculature - Impairment of coronary endothelial function, as part of a systemic alteration of the vascular endothelium, may be responsible of the marked decrease in coronary flow reserve in DCM 	<ul style="list-style-type: none"> - Therapy not related to microvascular function: as with other forms of heart failure, medical therapies, and implantable cardiac device therapy are used to reduce risk of cardiac arrest patients with DCM. - Because coronary microcirculation is involved in the pathogenesis of DCM, it should be considered as a new target in treatment in those cardiac diseases at risk to evolve toward heart failure⁸⁷ - Effective therapies which target low-density lipoprotein reduce coronary events by only 33% - Vasodilators - Anti-ischemic agent (trimetazidine) - Future perspective: cardiac stem cells^{75,81}
Secondary: ischemic CM	<ul style="list-style-type: none"> - Atherosclerosis-abnormally high levels of circulating lipid and circulating cholesterol incorporated into specific lipoproteins - Primary coronary microvascular dysfunction-impairment of endothelium-dependent vasodilation due to reduced nitric oxide release; endothelial progenitor cell abnormalities - Coronary artery spasm-endothelial damage exposes smooth muscle cell to agents that cause vasoconstriction, data on microvessel involvement lacking 	<ul style="list-style-type: none"> - Therapy not related to microvascular function - General concepts of chronic heart failure treatment: pharmacotherapy and implantable cardiac device therapy - Etiological antiviral treatment of inflammatory cardiomyopathies⁸⁷
Secondary: myocarditis	<ul style="list-style-type: none"> - Inflammatory endothelial activation; - Myocardial lymphocyte infiltration and endothelial activation - The vessel wall is involved in the inflammatory process 	<ul style="list-style-type: none"> - Therapy not related to microvascular function - General concepts of chronic heart failure treatment: pharmacotherapy and implantable cardiac device therapy - Etiological antiviral treatment of inflammatory cardiomyopathies⁸⁷
Restrictive		
Systemic disease: amyloidosis	<ul style="list-style-type: none"> - Lower rest myocardial blood flow - Lower stress myocardial blood flow and coronary flows reserve - Higher coronary vascular resistance - Apoptotic injury of coronary artery endothelial cells (oxidative stress, reduced nitric oxide bioavailability, and increased peroxynitrite production), no data on microcirculatory vessels 	<ul style="list-style-type: none"> - Therapy not related to microvascular function - Treating underlying systemic disorder (generally poor prognosis)¹¹³
Sarcoidosis	<ul style="list-style-type: none"> - Reversible microvascular disorders as evidenced by reversible thallium-201 myocardial redistribution defects on scintigraphy at rest and after dipyridamole - Inflammation 	<ul style="list-style-type: none"> - Therapy not related to microvascular function - Treating underlying systemic disorder (corticosteroids/ immunosuppression etc.)¹¹²
Hemochromatosis	<ul style="list-style-type: none"> - Decreased endothelium-dependent dilation in animal vascular models and larger human arteries as a result of iron overload, oxidative stress; direct evidence in coronary microcirculation lacking 	<ul style="list-style-type: none"> - Therapy not related to microvascular function - Treating underlying systemic disorder (mostly iron depletion therapy)¹¹¹
Endomyocardial fibrosis	<ul style="list-style-type: none"> - Little is known about microvasculature in EMF; - Coronary blood flow was normal (in some studies)/no significant abnormality in the medium sized or large portions of the coronary arteries (only occasionally were abnormal small vessels present) - Endocardial vascularization is dense with an irregular network of capillary-like vessels (initially); fibrous tissue becomes devascularized and relatively few vessels remain (later stage) 	<ul style="list-style-type: none"> - Therapy not related to microvascular function - Medical therapy and invasive procedures (for relief of pleural, pericardial and peritoneal effusions); only a few hospitals are able to perform open heart surgery (resecting the fibrous endocardium and correcting the atrioventricular valve abnormalities)^{96,102,104}
Cardiomyopathy as aging consequence	<ul style="list-style-type: none"> - Increased arteriolar stiffness - Impaired myogenic responsiveness - Microvascular rarefaction - Endothelial dysfunction 	<ul style="list-style-type: none"> - Therapy not related to microvascular function - Need for genetic and cardiomyocyte regeneration possibility research - Life-long prevention and comorbidities treatment¹²⁵

DCM indicates dilated cardiomyopathy; EMF, endomyocardial fibrosis; GL-3; globotriaosylceramide; HCM, hypertrophic cardiomyopathy; LV, left ventricle.

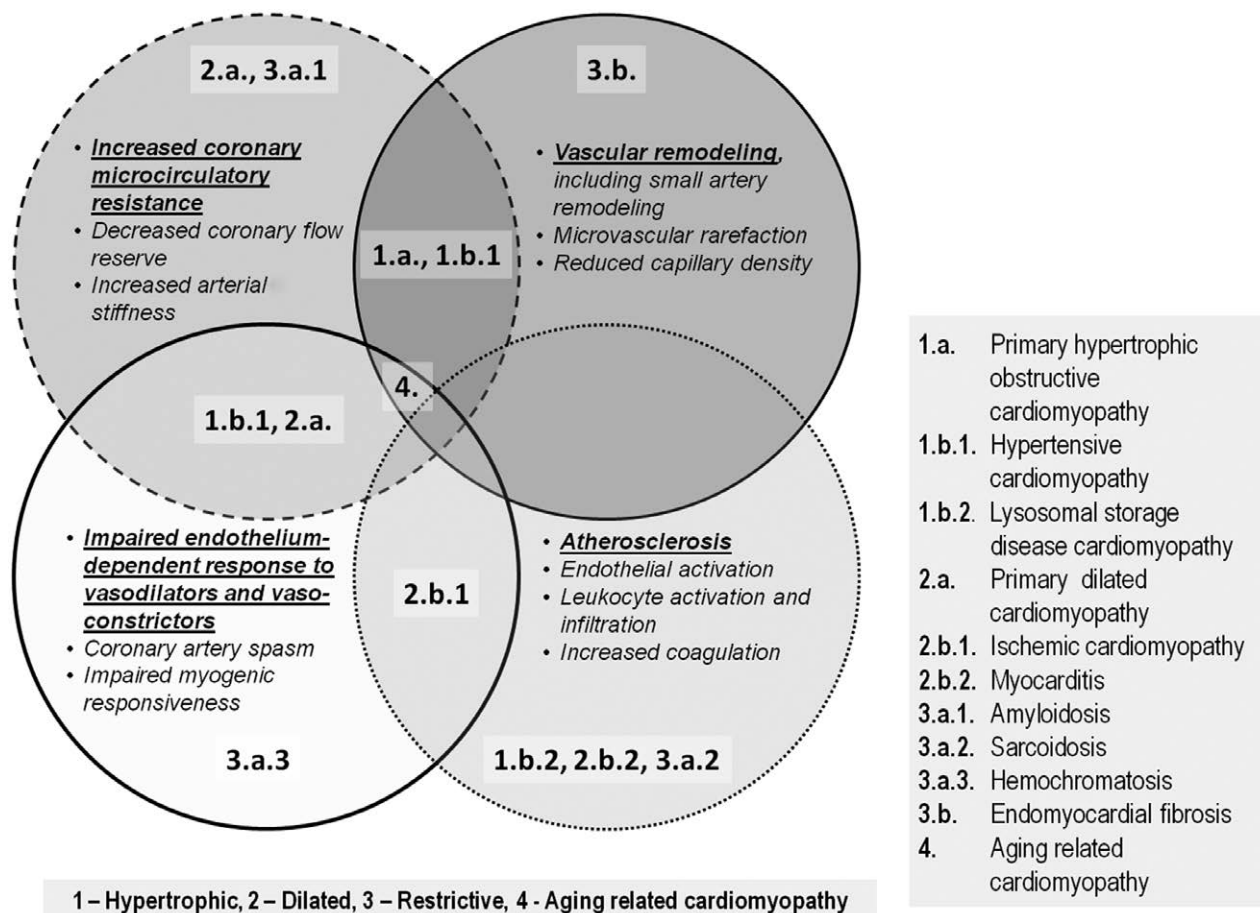


FIGURE 3. Common features of four different groups of cardiomyopathies.

REFERENCES

1. Camici PG, Crea F. Coronary microvascular dysfunction. *N Engl J Med*. 2007;356:830–840.
2. Herrmann J, Kaski JC, Lerman A. Coronary microvascular dysfunction in the clinical setting: from mystery to reality. *Eur Heart J*. 2012;33:2771–2782b.
3. Patel B, Fisher M. Therapeutic advances in myocardial microvascular resistance: unravelling the enigma. *Pharmacol Ther*. 2010;127:131–147.
4. Lanza GA, Crea F. Primary coronary microvascular dysfunction: clinical presentation, pathophysiology, and management. *Circulation*. 2010;121:2317–2325.
5. Takeuchi M, Kuroiwa A. Alteration of coronary flow velocity during spontaneous angina in a patient with microvascular angina. *Catheter Cardiovasc Interv*. 2000;50:63–67.
6. Vecoli C, Caselli C, Caruso R, et al. [Coronary microvascular disease: from experimental models to clinical practice]. *Recenti Prog Med*. 2012;103:288–296.
7. Dorbala S, Vangala D, Bruyere J Jr, et al. Coronary microvascular dysfunction is related to abnormalities in myocardial structure and function in cardiac amyloidosis. *JACC Heart Fail*. 2014;2:358–367.
8. Heffernan KS, Napolitano CA, Maron MS, et al. Peripheral vascular endothelial function in patients with hypertrophic cardiomyopathy. *Am J Cardiol*. 2010;105:112–115.
9. Mohammed SF, Hussain S, Mirzoyev SA, et al. Coronary microvascular rarefaction and myocardial fibrosis in heart failure with preserved ejection fraction. *Circulation*. 2015;131:550–559.
10. O'Rourke MF, Hashimoto J. Mechanical factors in arterial aging: a clinical perspective. *J Am Coll Cardiol*. 2007;50:1–13.
11. Selthofer-Relatić K, Bošnjak I. Myocardial fat as a part of cardiac visceral adipose tissue: physiological and pathophysiological view. *J Endocrinol Invest*. 2015;38:933–939.
12. Xu Y, Chester AH, Hariri B, et al. The indirect alloimmune response causes microvascular endothelial dysfunction—a possible role for alloantibody. *Transplantation*. 2010;90:1157–1164.
13. Gill RM, Jones BD, Corbly AK, et al. Cardiac diastolic dysfunction in conscious dogs with heart failure induced by chronic coronary microembolization. *Am J Physiol Heart Circ Physiol*. 2006;291:H3154–H3158.
14. Yoon YS, Uchida S, Masuo O, et al. Progressive attenuation of myocardial vascular endothelial growth factor expression is a seminal event in diabetic cardiomyopathy: restoration of microvascular homeostasis and recovery of cardiac function in diabetic cardiomyopathy after replenishment of local vascular endothelial growth factor. *Circulation*. 2005;111:2073–2085.
15. Dai Z, Aoki T, Fukumoto Y, et al. Coronary perivascular fibrosis is associated with impairment of coronary blood flow in patients with non-ischemic heart failure. *J Cardiol*. 2012;60:416–421.
16. Maron BJ, Ommen SR, Semsarian C, et al. Hypertrophic cardiomyopathy: present and future, with translation into contemporary cardiovascular medicine. *J Am Coll Cardiol*. 2014;64:83–99.
17. Ho CY. Genetic considerations in hypertrophic cardiomyopathy. *Prog Cardiovasc Dis*. 2012;54:456–460.
18. Olivetto I, Maron MS, Autore C, et al. Assessment and significance of left ventricular mass by cardiovascular magnetic resonance in hypertrophic cardiomyopathy. *J Am Coll Cardiol*. 2008;52:559–566.
19. Kramer CM, Appelbaum E, Desai MY, et al. Hypertrophic cardiomyopathy Registry: the rationale and design of an international, observational study of hypertrophic cardiomyopathy. *Am Heart J*. 2015;170:223–230.
20. Maron BJ, Gardin JM, Flack JM, et al. Prevalence of hypertrophic cardiomyopathy in a general population of young adults. Echocardiographic analysis of 4111 subjects in the CARDIA Study. Coronary Artery Risk Development in (Young) Adults. *Circulation*. 1995;92:785–789.

21. Maron BJ, Maron MS, Semsarian C. Genetics of hypertrophic cardiomyopathy after 20 years: clinical perspectives. *J Am Coll Cardiol*. 2012;60:705–715.
22. Seidman CE, Seidman JG. Identifying sarcomere gene mutations in hypertrophic cardiomyopathy: a personal history. *Circ Res*. 2011;108:743–750.
23. Ho CY. Genetics and clinical destiny: improving care in hypertrophic cardiomyopathy. *Circulation*. 2010;122:2430–2440; discussion 2440.
24. Olivetto I, Cecchi F, Camici PG. Coronary microvascular dysfunction and ischemia in hypertrophic cardiomyopathy. Mechanisms and clinical consequences. *Ital Heart J*. 2004;5:572–580.
25. Cokkinos DV, Krajcer Z, Leachman RD. Coronary artery disease in hypertrophic cardiomyopathy. *Am J Cardiol*. 1985;55:1437–1438.
26. Cokkinos DV, Krajcer Z, Leachman RD. Hypertrophic cardiomyopathy and associated coronary artery disease. *Tex Heart Inst J*. 1985;12:147–151.
27. Maron BJ, Wolfson JK, Epstein SE, et al. Intramural (“small vessel”) coronary artery disease in hypertrophic cardiomyopathy. *J Am Coll Cardiol*. 1986;8:545–557.
28. Cecchi F, Olivetto I, Gistri R, et al. Coronary microvascular dysfunction and prognosis in hypertrophic cardiomyopathy. *N Engl J Med*. 2003;349:1027–1035.
29. Jung WI, Sieverding L, Breuer J, et al. 31P NMR spectroscopy detects metabolic abnormalities in asymptomatic patients with hypertrophic cardiomyopathy. *Circulation*. 1998;97:2536–2542.
30. Camici P, Chiriacchi G, Lorenzoni R, et al. Coronary vasodilation is impaired in both hypertrophied and nonhypertrophied myocardium of patients with hypertrophic cardiomyopathy: a study with nitrogen-13 ammonia and positron emission tomography. *J Am Coll Cardiol*. 1991;17:879–886.
31. Lorenzoni R, Gistri R, Cecchi F, et al. Coronary vasodilator reserve is impaired in patients with hypertrophic cardiomyopathy and left ventricular dysfunction. *Am Heart J*. 1998;136:972–981.
32. Timmer SA, Knaapen P. Coronary microvascular function, myocardial metabolism, and energetics in hypertrophic cardiomyopathy: insights from positron emission tomography. *Eur Heart J Cardiovasc Imaging*. 2013;14:95–101.
33. Knaapen P, Germans T, Camici PG, et al. Determinants of coronary microvascular dysfunction in symptomatic hypertrophic cardiomyopathy. *Am J Physiol Heart Circ Physiol*. 2008;294:H986–H993.
34. Sayin MR, Dogan SM, Karabag T, et al. Systolic compression of intramural coronary arteries in hypertrophic cardiomyopathy. *Case Rep Cardiol*. 2012;2012:629842.
35. Schwartzkopff B, Mundhenke M, Strauer BE. Alterations of the architecture of subendocardial arterioles in patients with hypertrophic cardiomyopathy and impaired coronary vasodilator reserve: a possible cause for myocardial ischemia. *J Am Coll Cardiol*. 1998;31:1089–1096.
36. Drazner MH. The progression of hypertensive heart disease. *Circulation*. 2011;123:327–334.
37. Schwartzkopff B, Motz W, Frenzel H, et al. Structural and functional alterations of the intramyocardial coronary arterioles in patients with arterial hypertension. *Circulation*. 1993;88:993–1003.
38. Indermühle A, Vogel R, Meier P, et al. The relative myocardial blood volume differentiates between hypertensive heart disease and athlete's heart in humans. *Eur Heart J*. 2006;27:1571–1578.
39. Struijker Boudier HA, Cohuet GM, Baumann M, et al. The heart, macrocirculation and microcirculation in hypertension: a unifying hypothesis. *J Hypertens Suppl*. 2003;21:S19–S23.
40. Mundhenke M, Schwartzkopff B, Strauer BE. Structural analysis of arteriolar and myocardial remodeling in the subendocardial region of patients with hypertensive heart disease and hypertrophic cardiomyopathy. *Virchows Arch*. 1997;431:265–273.
41. Hamasaki S, Al Suwaidi J, Higano ST, et al. Attenuated coronary flow reserve and vascular remodeling in patients with hypertension and left ventricular hypertrophy. *J Am Coll Cardiol*. 2000;35:1654–1660.
42. Strauer BE, Schwartzkopff B. Left ventricular hypertrophy and coronary microcirculation in hypertensive heart disease. *Blood Press Suppl*. 1997;2:6–12.
43. Vogt M, Strauer BE. Systolic ventricular dysfunction and heart failure due to coronary microangiopathy in hypertensive heart disease. *Am J Cardiol*. 1995;76:48D–53D.
44. Di Bello V, Giorgi D, Pedrinelli R, et al. Coronary microcirculation into different models of left ventricular hypertrophy-hypertensive and athlete's heart: a contrast echocardiographic study. *J Hum Hypertens*. 2003;17:253–263.
45. Schwartzkopff B, Brehm M, Mundhenke M, et al. Repair of coronary arterioles after treatment with perindopril in hypertensive heart disease. *Hypertension*. 2000;36:220–225.
46. Pantazis A, Vischer AS, Perez-Tome MC, et al. Diagnosis and management of hypertrophic cardiomyopathy. *Echo Res Pract*. 2015;2:R45–R53.
47. Thurberg BL, Fallon JT, Mitchell R, et al. Cardiac microvascular pathology in Fabry disease: evaluation of endomyocardial biopsies before and after enzyme replacement therapy. *Circulation*. 2009;119:2561–2567.
48. DeGraba T, Azhar S, Dignat-George F, et al. Profile of endothelial and leukocyte activation in Fabry patients. *Ann Neurol*. 2000;47:229–233.
49. Sakuraba H, Igarashi T, Shibata T, et al. Effect of vitamin E and ticlopidine on platelet aggregation in Fabry's disease. *Clin Genet*. 1987;31:349–354.
50. Elliott PM, Kindler H, Shah JS, et al. Coronary microvascular dysfunction in male patients with Anderson-Fabry disease and the effect of treatment with alpha galactosidase A. *Heart*. 2006;92:357–360.
51. Lakdawala NK, Winterfield JR, Funke BH. Dilated cardiomyopathy. *Circ Arrhythm Electrophysiol*. 2013;6:228–237.
52. Maron BJ, Towbin JA, Thiene G, et al; American Heart Association; Council on Clinical Cardiology, Heart Failure and Transplantation Committee; Quality of Care and Outcomes Research and Functional Genomics and Translational Biology Interdisciplinary Working Groups; Council on Epidemiology and Prevention. Contemporary definitions and classification of the cardiomyopathies: an American Heart Association Scientific Statement from the Council on Clinical Cardiology, Heart Failure and Transplantation Committee; Quality of Care and Outcomes Research and Functional Genomics and Translational Biology Interdisciplinary Working Groups; and Council on Epidemiology and Prevention. *Circulation*. 2006;113:1807–1816.
53. Lang RM, Bierig M, Devereux RB, et al; Chamber Quantification Writing Group; American Society of Echocardiography's Guidelines and Standards Committee; European Association of Echocardiography. Recommendations for chamber quantification: a report from the American Society of Echocardiography's Guidelines and Standards Committee and the Chamber Quantification Writing Group, developed in conjunction with the European Association of Echocardiography, a branch of the European Society of Cardiology. *J Am Soc Echocardiogr*. 2005;18:1440–1463.
54. Davies MJ, McKenna WJ. Dilated cardiomyopathy: an introduction to pathology and pathogenesis. *Br Heart J*. 1994;72(6 Suppl):S24.
55. Gopal DM, Sam F. New and emerging biomarkers in left ventricular systolic dysfunction—insight into dilated cardiomyopathy. *J Cardiovasc Transl Res*. 2013;6:516–527.
56. Richardson P, McKenna W, Bristow M, et al. Report of the 1995 World Health Organization/International Society and Federation of Cardiology Task Force on the Definition and Classification of cardiomyopathies. *Circulation*. 1996;93:841–842.
57. Neglia D, L'Abbate A. Coronary microvascular dysfunction and idiopathic dilated cardiomyopathy. *Pharmacol Rep*. 2005;57(suppl):151–155.
58. Horwitz LD, Curry GC, Parkey RW, et al. Effect of isoproterenol on coronary blood flow in primary myocardial disease. *Circulation*. 1974;50:560–564.
59. Mohri M, Takeshita A. Coronary microvascular disease in humans. *Jpn Heart J*. 1999;40:97–108.
60. Yamaguchi S, Tsuiki K, Hayasaka M, et al. Segmental wall motion abnormalities in dilated cardiomyopathy: hemodynamic characteristics and comparison with thallium-201 myocardial scintigraphy. *Am Heart J*. 1987;113:1123–1128.
61. Cannon RO 3rd, Cunnion RE, Parrillo JE, et al. Dynamic limitation of coronary vasodilator reserve in patients with dilated cardiomyopathy and chest pain. *J Am Coll Cardiol*. 1987;10:1190–1200.
62. Treasure CB, Vita JA, Cox DA, et al. Endothelium-dependent dilation of the coronary microvasculature is impaired in dilated cardiomyopathy. *Circulation*. 1990;81:772–779.
63. Parodi O, De Maria R, Oltrona L, et al. Myocardial blood flow distribution in patients with ischemic heart disease or dilated cardiomyopathy undergoing heart transplantation. *Circulation*. 1993;88:509–522.
64. Drexler H, Hayoz D, Münzel T, et al. Endothelial function in chronic congestive heart failure. *Am J Cardiol*. 1992;69:1596–1601.
65. Neglia D, Michelassi C, Trivieri MG, et al. Prognostic role of myocardial blood flow impairment in idiopathic left ventricular dysfunction. *Circulation*. 2002;105:186–193.
66. Gil KE, Pawlak A, Frontczak-Baniewicz M, et al. The proposed new classification changes in coronary microcirculation as the predictor of the heart failure progression in idiopathic dilated cardiomyopathy. *Cardiovasc Pathol*. 2015;24:351–358.
67. Miller WL, Behrenbeck TR, McCollough CH, et al. Coronary microcirculation changes in non-ischemic dilated cardiomyopathy identified by novel perfusion CT. *Int J Cardiovasc Imaging*. 2015;31:881–888.
68. Anversa P, Sonnenblick EH. Ischemic cardiomyopathy: pathophysiologic mechanisms. *Prog Cardiovasc Dis*. 1990;33:49–70.

69. Hare JM, Walford GD, Hruban RH, et al. Ischemic cardiomyopathy: endomyocardial biopsy and ventriculographic evaluation of patients with congestive heart failure, dilated cardiomyopathy and coronary artery disease. *J Am Coll Cardiol.* 1992;20:1318–1325.
70. Libby P, Ridker PM, Hansson GK; Leducq Transatlantic Network on Atherothrombosis. Inflammation in atherosclerosis: from pathophysiology to practice. *J Am Coll Cardiol.* 2009;54:2129–2138.
71. Glagov S, Weisenberg E, Zarins CK, et al. Compensatory enlargement of human atherosclerotic coronary arteries. *N Engl J Med.* 1987;316:1371–1375.
72. Hansson GK. Inflammation, atherosclerosis, and coronary artery disease. *N Engl J Med.* 2005;352:1685–1695.
73. Abela GS, Aziz K, Vedre A, et al. Effect of cholesterol crystals on plaques and intima in arteries of patients with acute coronary and cerebrovascular syndromes. *Am J Cardiol.* 2009;103:959–968.
74. Virmani R, Kolodgie FD, Burke AP, et al. Atherosclerotic plaque progression and vulnerability to rupture: angiogenesis as a source of intraplaque hemorrhage. *Arterioscler Thromb Vasc Biol.* 2005;25:2054–2061.
75. Traub O, Berk BC. Laminar shear stress: mechanisms by which endothelial cells transduce an atheroprotective force. *Arterioscler Thromb Vasc Biol.* 1998;18:677–685.
76. Kuo L, Davis MJ, Cannon MS, et al. Pathophysiological consequences of atherosclerosis extend into the coronary microcirculation. Restoration of endothelium-dependent responses by L-arginine. *Circ Res.* 1992;70:465–476.
77. Panza JA. Coronary atherosclerosis: extending to the microcirculation? *Eur Heart J.* 2010;31:905–907.
78. Mosseri M, Yarom R, Gotsman MS, et al. Histologic evidence for small-vessel coronary artery disease in patients with angina pectoris and patent large coronary arteries. *Circulation.* 1986;74:964–972.
79. Opherck D, Zebe H, Weihe E, et al. Reduced coronary dilatory capacity and ultrastructural changes of the myocardium in patients with angina pectoris but normal coronary arteriograms. *Circulation.* 1981;63:817–825.
80. Böttcher M, Botker HE, Sonne H, et al. Endothelium-dependent and -independent perfusion reserve and the effect of L-arginine on myocardial perfusion in patients with syndrome X. *Circulation.* 1999;99:1795–1801.
81. Huang PH, Chen YH, Chen YL, et al. Vascular endothelial function and circulating endothelial progenitor cells in patients with cardiac syndrome X. *Heart.* 2007;93:1064–1070.
82. Desideri G, Gaspardone A, Gentile M, et al. Endothelial activation in patients with cardiac syndrome X. *Circulation.* 2000;102:2359–2364.
83. Panting JR, Gatehouse PD, Yang GZ, et al. Abnormal subendocardial perfusion in cardiac syndrome X detected by cardiovascular magnetic resonance imaging. *N Engl J Med.* 2002;346:1948–1953.
84. Yasue H, Horio Y, Nakamura N, et al. Induction of coronary artery spasm by acetylcholine in patients with variant angina: possible role of the parasympathetic nervous system in the pathogenesis of coronary artery spasm. *Circulation.* 1986;74:955–963.
85. Yasue H, Nakagawa H, Itoh T, et al. Coronary artery spasm—clinical features, diagnosis, pathogenesis, and treatment. *J Cardiol.* 2008;51:2–17.
86. Hung MJ, Hu P, Hung MY. Coronary artery spasm: review and update. *Int J Med Sci.* 2014;11:1161–1171.
87. Sisakian H. Cardiomyopathies: evolution of pathogenesis concepts and potential for new therapies. *World J Cardiol.* 2014;6:478–494.
88. Noutsias M, Seeberg B, Schultheiss HP, et al. Expression of cell adhesion molecules in dilated cardiomyopathy: evidence for endothelial activation in inflammatory cardiomyopathy. *Circulation.* 1999;99:2124–2131.
89. Klein RM, Schwartzkopff B, Gabbert HE, et al. Diminished coronary reserve in patients with biopsy-proven inflammatory infiltrates. *Cardiology.* 2003;100:120–128.
90. Noutsias M, Hohmann C, Pauschinger M, et al. sICAM-1 correlates with myocardial ICAM-1 expression in dilated cardiomyopathy. *Int J Cardiol.* 2003;91:153–161.
91. Vallbracht KB, Schwimbeck PL, Seeberg B, et al. Endothelial dysfunction of peripheral arteries in patients with immunohistologically confirmed myocardial inflammation correlates with endothelial expression of human leukocyte antigens and adhesion molecules in myocardial biopsies. *J Am Coll Cardiol.* 2002;40:515–520.
92. Vallbracht KB, Schwimbeck PL, Kühl U, et al. Differential aspects of endothelial function of the coronary microcirculation considering myocardial virus persistence, endothelial activation, and myocardial leukocyte infiltrates. *Circulation.* 2005;111:1784–1791.
93. Vallbracht KB, Schwimbeck PL, Kühl U, et al. Endothelium-dependent flow-mediated vasodilation of systemic arteries is impaired in patients with myocardial virus persistence. *Circulation.* 2004;110:2938–2945.
94. Liu M, Wang F, Wang Y, et al. Atorvastatin improves endothelial function and cardiac performance in patients with dilated cardiomyopathy: the role of inflammation. *Cardiovasc Drugs Ther.* 2009;23:369–376.
95. Bukhman G, Ziegler J, Parry E. Endomyocardial fibrosis: still a mystery after 60 years. *PLoS Negl Trop Dis.* 2008;2:e97.
96. Mocumbi AO. Endomyocardial fibrosis: a form of endemic restrictive cardiomyopathy. *Glob Cardiol Sci Pract.* 2012;2012:11.
97. Kartha CC. Endomyocardial fibrosis, a case for the tropical doctor. *Cardiovasc Res.* 1995;30:636–643.
98. Mocumbi AO, Latif N, Yacoub MH. Presence of circulating anti-myosin antibodies in endomyocardial fibrosis. *PLoS Negl Trop Dis.* 2010;4:e661.
99. Mocumbi AO: Right ventricular endomyocardial fibrosis (2013 Grover Conference series). *Pulm Circ* 2014; 4:363–9.
100. Iglezias SD, Benvenuti LA, Calabrese F, et al. Endomyocardial fibrosis: pathological and molecular findings of surgically resected ventricular endomyocardium. *Virchows Arch.* 2008;453:233–241.
101. Mann DL, Felker GM. *Heart Failure: A Companion to Braunwald's Heart Disease.* 3rd ed. Philadelphia, PA: Elsevier; 2015:109–126.
102. Mocumbi AO, Yacoub MH, Yokohama H, et al. Right ventricular endomyocardial fibrosis. *Cardiovasc Pathol.* 2009;18:64–65.
103. Somers K: Restrictive cardiomyopathies. In: Pongpanich B, Sueblinvong V, Vongprateep C, eds. *Pediatric Cardiology.* International Congress Series 906. Amsterdam: Excerpta Medica; 1990.
104. Mocumbi AO, Falase AO. Republished: recent advances in the epidemiology, diagnosis and treatment of endomyocardial fibrosis in Africa. *Postgrad Med J.* 2014;90:48–54.
105. Salemi VM, Rochitte CE, Barbosa MM, et al. Images in cardiology. Clinical and echocardiographic dissociation in a patient with right ventricular endomyocardial fibrosis. *Heart.* 2005;91:1399.
106. Jaiyesimi F, Falase AO. Extracardiac manifestations of endomyocardial fibrosis and their psychosocial complications. *Tropical Cardiology* 1976; 2:5–11.
107. Ribeiro PA, Muthusamy R, Duran CM. Right-sided endomyocardial fibrosis with recurrent pulmonary emboli leading to irreversible pulmonary hypertension. *Br Heart J.* 1992;68:326–329.
108. Vijayaraghavan G, Sivasankaran S. Tropical endomyocardial fibrosis in India: a vanishing disease! *Indian J Med Res.* 2012;136:729–738.
109. Hassan WM, Fawzy ME, Al Helaly S, et al. Pitfalls in diagnosis and clinical, echocardiographic, and hemodynamic findings in endomyocardial fibrosis: a 25-year experience. *Chest.* 2005;128:3985–3992.
110. Balakrishnan KG, Sasidharan K, Venkitachalam CG, et al. Coronary angiographic features in endomyocardial fibrosis. *Cardiology.* 1983;70:121–126.
111. Farrer-Brown G, Tarbit MH, Somers K, et al. Microvascular study of hearts with endomyocardial fibrosis. *Br Heart J.* 1972;34:1250–1262.
112. Bejar D, Colombo PC, Latif F, et al. Infiltrative cardiomyopathies. *Clin Med Insights Cardiol.* 2015;9(suppl 2):29–38.
113. Nihoyannopoulos P, Dawson D. Restrictive cardiomyopathies. *Eur J Echocardiogr.* 2009;10:iii23–iii33.
114. McAllister HA Jr, Seger J, Bossart M, et al. Restrictive cardiomyopathy with kappa light chain deposits in myocardium as a complication of multiple myeloma. Histochemical and electron microscopic observations. *Arch Pathol Lab Med.* 1988;112:1151–1154.
115. Guan J, Mishra S, Falk RH, et al. Current perspectives on cardiac amyloidosis. *Am J Physiol Heart Circ Physiol.* 2012;302:H544–H552.
116. Migrino RQ, Truran S, Gutterman DD, et al. Human microvascular dysfunction and apoptotic injury induced by AL amyloidosis light chain proteins. *Am J Physiol Heart Circ Physiol.* 2011;301:H2305–H2312.
117. Abdelmoneim SS, Bernier M, Bellavia D, et al. Myocardial contrast echocardiography in biopsy-proven primary cardiac amyloidosis. *Eur J Echocardiogr.* 2008;9:338–341.
118. Liu D, Birnbaum AD. Update on sarcoidosis. *Curr Opin Ophthalmol.* 2015;26:512–516.
119. Siasos G, Tousoulis D, Gialafos E, et al. Association of sarcoidosis with endothelial function, arterial wall properties, and biomarkers of inflammation. *Medicine (Baltimore)* 2004; 83:315–34.
120. Terasaki F, Ukimura A, Tsukada B, et al. Enhanced expression of type 1 helper T-cell cytokines in the myocardium of active cardiac sarcoidosis. *Circ J.* 2008;72:1303–1307.
121. Rafiq I, Nadig V, Freeman LJ. Sarcoidosis, microvascular angina and aortitis: new dimensions of the 'Takayasu syndrome' - a case report. *Int J Angiol.* 2007;16:113–114.

122. Tellier P, Paycha F, Antony I, et al. Reversibility by dipyridamole of thallium-201 myocardial scan defects in patients with sarcoidosis. *Am J Med.* 1988;85:189–193.
123. Marques VB, Nascimento TB, Ribeiro RF Junior, et al. Chronic iron overload in rats increases vascular reactivity by increasing oxidative stress and reducing nitric oxide bioavailability. *Life Sci.* 2015;15:89–97.
124. Gaenzer H, Marschang P, Sturm W, et al. Association between increased iron stores and impaired endothelial function in patients with hereditary hemochromatosis. *J Am Coll Cardiol.* 2002;40:2189–2194.
125. Shioi T, Inuzuka Y. Aging as a substrate of heart failure. *J Cardiol.* 2012;60:423–428.
126. Lakatta EG, Levy D. Arterial and cardiac aging: major shareholders in cardiovascular disease enterprises: Part II: the aging heart in health: links to heart disease. *Circulation.* 2003;107:346–354.
127. Bernardes de Jesus B, Blasco MA. Assessing cell and organ senescence biomarkers. *Circ Res.* 2012;111:97–109.
128. Kenyon C. The plasticity of aging: insights from long-lived mutants. *Cell.* 2005;120:449–460.
129. Lazzarini V, Mentz RJ, Fiuzat M, et al. Heart failure in elderly patients: distinctive features and unresolved issues. *Eur J Heart Fail.* 2013;15:717–723.
130. Kasner M, Westermann D, Lopez B, et al. Diastolic tissue Doppler indexes correlate with the degree of collagen expression and cross-linking in heart failure and normal ejection fraction. *J Am Coll Cardiol.* 2011;57:977–985.
131. Tansey DK, Aly Z, Sheppard MN. Fat in the right ventricle of the normal heart. *Histopathology.* 2005;46:98–104.
132. van Heerebeek L, Borbély A, Niessen HW, et al. Myocardial structure and function differ in systolic and diastolic heart failure. *Circulation.* 2006;113:1966–1973.
133. Westermann D, Lindner D, Kasner M, et al. Cardiac inflammation contributes to changes in the extracellular matrix in patients with heart failure and normal ejection fraction. *Circ Heart Fail.* 2011;4:44–52.
134. Paulus WJ, Tschöpe C. A novel paradigm for heart failure with preserved ejection fraction: comorbidities drive myocardial dysfunction and remodeling through coronary microvascular endothelial inflammation. *J Am Coll Cardiol.* 2013;62:263–271.
135. Hanna MA, Taylor CR, Chen B, et al. Structural remodeling of coronary resistance arteries: effects of age and exercise training. *J Appl Physiol (1985).* 2014;117:616–623.
136. Cheitlin MD. Cardiovascular physiology-changes with aging. *Am J Geriatr Cardiol.* 2003;12:9–13.
137. Ganz P, Hsue PY. Assessment of structural disease in the coronary microvasculature. *Circulation.* 2009;120:1555–1557.