

A Wound Infiltration as a Method of Postoperative Analgesia

Kvolik, Slavica; Kristek, Jozo; Šakić, Kata; Takač, Ines; Gulam, Danijela

Source / Izvornik: **Periodicum biologorum, 2009, 111, 241 - 246**

Journal article, Published version

Rad u časopisu, Objavljena verzija rada (izdavačev PDF)

Permanent link / Trajna poveznica: <https://um.nsk.hr/um:nbn:hr:239:289654>

Rights / Prava: [In copyright](#)/[Zaštićeno autorskim pravom.](#)

Download date / Datum preuzimanja: **2024-09-01**



Repository / Repozitorij:

[Repository UHC Osijek - Repository University
Hospital Centre Osijek](#)



A wound infiltration as a method of postoperative analgesia

SLAVICA KVOLIK^{1,2}
JOZO KRISTEK^{2,3}
KATA ŠAKIĆ^{2,4}
INES TAKAČ¹
DANIJELA GULAM¹

¹University Clinical Hospital Osijek,
Dept. of Anaesthesiology and ICU,
J. Huttlera 4, 31000 Osijek, Croatia

²University JJ Strossmayer,
School of Medicine, J. Huttlera 4,
31000 Osijek, Croatia

³University Clinical Hospital Osijek,
Dept. of Surgery, J. Huttlera 4,
31000 Osijek, Croatia

⁴General Hospital Sveti duh, Sveti duh 64,
10000 Zagreb, Croatia

Correspondence:

Slavica Kvolik
Dept. of Anaesthesiology and ICU
University Clinical Hospital Osijek,
University JJ Strossmayer,
School of Medicine
J. Huttlera 4, 31000 Osijek, Croatia
E-mail: slavica.kvolik@os.t-com.hr

Abbreviations:

LA – local anaesthetics
GA – general anaesthesia

Key words: Local anaesthetics; Infiltration anaesthesia; Postoperative care; Analgesia, Patient controlled

Received April 25, 2009

Abstract

A wound infiltration is a method of postoperative analgesia efficient in the various surgical subdisciplines. This technique resulted from the observation that patients whose surgical procedures were performed under regional anaesthesia techniques have reduced postoperative analgesic consumption. Owing to the advances in the drug discovery and to the introduction of local anaesthetics with prolonged effects, this technique has less adverse reactions and considerable analgesic effects. New local anaesthetics with long duration of action and low toxicity like levobupivacaine and ropivacaine are currently available at the market. Such drugs with lower potential for systemic toxicity provided additional safety dimension to local infiltration techniques. A variety of methods were developed to achieve painless recovery period, better patient comfort and to improve patient outcome. Probably the most common technique is a field block at the end of the surgery that can be performed both during regional anaesthesia techniques and in the general anaesthesia. The use of wound infiltration techniques was facilitated by important technical improvements in the multilumen catheters and by construction of special drug delivery devices. Numerous disposable elastomeric devices and patient controlled pumps are suitable for prolonged periods of analgesia in the clinical and outpatient setting. Although it can be used alone for less painful procedures, infiltration analgesia is now important part of multimodal pain treatment. This complex approach to the postoperative pain treatment is characterized by the use of different analgesic drugs and techniques, like wound infiltration and intravenous opioid or nonsteroidal anti-inflammatory drugs. Multimodal postoperative pain treatment is acceptable after painful procedures i.e. hip and knee replacement, where it improves pain control and patient outcome.

INTRODUCTION

A wound infiltration is a method of postoperative analgesia commonly used alone or with other analgesic regimens. It was developed to improve postoperative analgesia, reduce opioid consumption and hasten patient recovery. The use of local anaesthetics (LAs) instead of opioid minimizes opioid adverse reactions, reduces nursing work, decreases resting pain, pain on motion, and thus allows better patient mobility. Therefore some of wound infiltration methods can be used in the ambulatory surgery (1). Although numerous methods of infiltration analgesia were proven as useful and effective, each of them has some limitations. In the recent years, wound infiltration analgesia has become an important part of multimodal analgesia. That combination of various postoperative analgesic techniques utilizes benefits of each method and minimises adverse reactions. This article is aimed to review indications, drugs used and wound infiltration techniques appropriate for the postoperative analgesia.

INDICATIONS

Numerous clinical studies have confirmed wound infiltration as safe and effective postoperative analgesia technique after surgical procedures performed in the general or regional anaesthesia. In the less extensive surgical procedures, i.e. open inguinal hernia repair or breast cancer operations, it significantly reduces opioid consumption, and in the remarkable proportion of patient it may be sufficient as single method of postoperative analgesia (2, 3). It is widely used in the moderate invasive general surgery, in the plastic surgery, and in the gynaecologic-urologic surgical procedures (4–7). Wound infiltration is also accepted

method of postoperative analgesia in the invasive and painful procedures i.e. caesarean delivery (8). In the orthopaedic procedures, in the lumbar spine surgery, after hip and knee replacement, after shoulder surgery and after cardiothoracic surgical procedures it is currently an important part of multimodal pain treatment (9–11).

METHODS

A simple and effective method of postoperative wound infiltration is single shot infiltration analgesia (Figure 1). It is usually performed by surgeon at the end of operation, during regional or general anaesthesia (Table 1) (1,

TABLE 1
Wound infiltration techniques.

A method of LA application	Type of surgery (anesthesia)	Postoperative analgesia groups	Concentration (rescue analgesic)	Significance (VAS)	Author (ref.)
Single shot	Haemorrhoidectomy (in SA with lidocaine 3%)	(All: CEA 90 mg eptazocine in normal saline /48 hr) Adjuvant lidocaine infiltration vs, saline	15 vml lidocaine 1% vs saline (NSAIDS <i>laxoprofen</i> or <i>indomethacin</i> , <i>Eptazocine 15 mg</i>)	4.42 vs 3.14 P < 0.05	Morisaki et al. (13)
PCA wound instillation Epidural catheter	Thoracotomy (GA)	Catheter bolus doses bupivacaine vs intercostal blockade (12h)	20 mL bupivacaine twice daily vs. 3x15 mL/ in the each intercostal space	P < 0.05	Kristek et al. (16)
2 wound catheters	Major intraabdominal surgery (in GA)	Bupivacaine vs. saline	9 ml 0.25% bupivacaine vs equal volume NaCl (<i>morphine 2 mg IV/6h</i> , and <i>meperidine 1 mg/kg IM</i>)	NS	Fredman et al. (8)
PCA wound instillation	Posterior lumbar arthrodesis (in GA)	Ropivacaine vs morphine	Ropivacaine 0.2% 5 mL/h for 55 h vs. morphine at 0.5 mg/h plus ketorolac 3.7 mg/h for 24 h	P < 0.0001	Bianconi et al. (15)
PCA wound instillation (Epidural catheter)	Total abdominal hysterectomy and bilateral salpingo-oophorectomy (in GA)	Bupivacaine vs. saline	Postoperative infusion 9 mL 0.25% bupivacaine over 24 h vs. saline (<i>morphine 2 mg IV</i>)	(P < 0.001)	Zohar et al. (18)
PCA wound instillation (Epidural catheter)	Total abdominal hysterectomy and bilateral salpingo-oophorectomy (in GA)	Varying the concentration of ropivacaine	Ropivacaine 0.1% or ropivacaine 0.2% (<i>morphine 2 mg IV</i>)	Ns.	Zohar J C A 2004
PCA wound instillation (2 catheters)	Transverse rectus abdominis musculocutaneous flap surgery (GA)	Ropivacaine vs. saline	0.2% ropivacaine 10 mL/h or saline (<i>IV opioid PCA</i>)	P=0.007	Dagtekin et al. (4)
ON-Q elastomeric device with 2 catheters	Transverse rectus abdominis musculocutaneous flap donor sites	Bupivacaine vs saline	Bupivacaine 0.375% continuous infusion vs saline (rescue PCA IV morphine or hydromorphone)	p = 0.019	Heller et al. (5)
LA irrigation through the axillary drain	Mastectomy with complete axillary node clearance (GA)	Bupivacaine vs saline	Bupivacaine 0,5% irrigation 4-hourly for 24 h (<i>PCA morphine</i>)	Ns.	Talbot et al. (30)
Elastomeric balloon pump	Mastectomy and axillary lymph node dissection (GA)	Continuous infusion of bupivacaine vs. saline	Bupivacaine 0.5% infusion at a 2 mL/h rate (<i>oral opioid analgesics</i>)	P < 0.001	Schell et al. (31)
Elastomeric balloon pump 2 catheters	Anterior cruciate ligament reconstruction (femoral-sciatic nerve block anesthesia)	Continuous femoral nerve block or continuous LA wound and intra-articular infusions	CFNB: 0.2% of ropivacaine at 7 mL/hr, Vs. 2 mg/mL at 2 mL/hr for each catheter in the wound (<i>morphine</i>)	P < 0.001	Dauri et al. (24)
ON-Q elastomeric device	Open hernia repair (ambulatory)	0.5% bupivacaine or saline	Continuous 48 hours infusion at 2 mL/hour (<i>opioid narcotics</i>)	p < 0.05	LeBlanc et al. (2)
Multimodal analgesia + disposable infusion pump (ON-Q)	Inguinal herniorrhaphy (in GA)	Bupivacaine vs. saline (10 mL of 0.25% bupivacaine for infiltration of the ilio-inguinal nerve in all patients)	Bupivacaine 0,5% at 2 mL/h (<i>hydrocodone 5 mg/acetaminophen 500 mg tablets</i>)	P=.002 only on the 1 st POD	Schurr et al. (1)
Elastomeric infusion pump device	Hip/knee arthroplasty (SA with 15-20 mg bupivacaine)	Ropivacaine vs. morphine	Ropivacaine 0.2% 5 mL/h vs saline (<i>diclofenac 75 mg or tramadol 100 mg</i>)	P<0.01	Bianconi et al. (9)
Bolus doses, epidural catheter (end of surgery, next morning)	Hip replacement (SA)	Ropivacaine vs. saline through the multi-hole epidural catheter All patients: 4x1 g paracetamol	Ropivacaine 300 (+150), ketorolac 30 mg, and adrenaline 0.5 mg vs. saline (<i>Oxycodon</i>)	Rescue drugs: p < 0.02; pain: < 0.04	Andersen L J et al. (22)
Multimodal analgesia	Hip/knee arthroplasty (SA)	Wound infiltration vs. continuous epidural	Local and intraarticular infiltration vs. epidural ropivacaine 2 mg/mL with morphine 5 ig/mL, 4 mL/h (All patients: 1 g paracetamol orally 4X + oxycodonhydrochlorid 10-20 mg 2X daily)	p = 0.004	Andersen K V et al. (17)

Notes: CEA continuous epidural analgesia; CFNB continuous femoral nerve block; GA general anaesthesia; LA local anaesthetic; NS non-significant; POD postoperative day; *PVB (paravertebral block) was more efficient up to 4 hours, thereafter ropivacaine group have lower pain scores; SA spinal anaesthesia, Significance was registered in the terms of effective analgesia and/or reduced postoperative rescue drugs consumption.

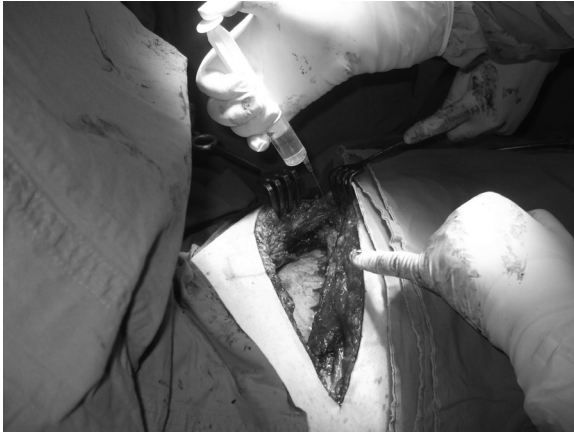

Figure 1. Intraoperative intercostal block. Intercostal nerve in the thoracotomy wound and nerves below and above thoracotomy wound were infiltrated using 5 mL bupivacaine 0.5% per intercostal space.

12). Such early suppression of pain stimuli effectively reduces an occurrence of acute postoperative pain (12) and significantly reduces postoperative analgesic drug consumption (13, 14).

Although long acting local anaesthetics can be applied, and effects may be even prolonged with the addition of vasoconstrictors, this method is limited by the relatively short duration of action of local anaesthetics and the inability to easily repeat the procedure after wound closure. In recent years, significant improvements in this technique were achieved by introduction of systems that continuously infuse a local anaesthetic through catheters implanted in the wound (5, 7, 9, 15).

Combinations with other techniques such as preoperative or intraoperative nerve blocks have made wound infiltration analgesia more efficient and acceptable for painful procedures. Well known combination technique used in the patients undergoing thoracotomy is intraoperative intercostal blockade that enables early onset of analgesia, and catheter wound infiltration that provides prolonged analgesia (16).

Combination of two infiltration methods, nerve blocks and parenteral nonopioid or opioid adjuncts may be useful alternative to postoperative PCA opioid analgesia in painful procedures. This technique is commonly referred as multimodal analgesia. A combination of spinal anaesthesia, intraoperative or postoperative nerve block, wound infiltration and postoperative local anaesthetic infusion through catheter represents a method of multimodal postoperative analgesia (10, 17).

Multimodal postoperative analgesia is especially acceptable for painful orthopaedic procedures like hip/knee arthroplasty, where early mobilization is required. It must enable prolonged analgesia but not motor blockade, and must provide analgesia for painful periods of movement. A typical multimodal approach to the postoperative pain treatment was recently described by Andersen and co-workers. In the patients undergoing hip arthroplasty in spinal anaesthesia, usually two-step procedure is required to infiltrate the deeper soft pericapsular tissue layer

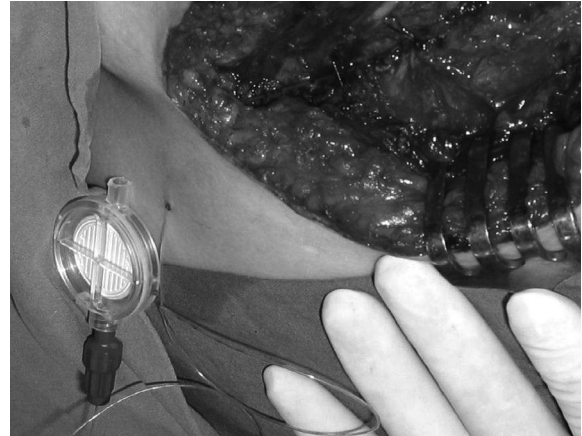


Figure 2. A placement of intercostal catheter for wound infiltration. The catheter was placed by physician on the completion of surgery, such that the tip was within the surgical wound. Antibacterial filter is a part of each drug delivery system.

and for infiltration around the entire wound (10, 17). After wound infiltration, the surgeon places a multihole catheter under direct visualization into the gluteus maximus muscle, with the catheter tip sited intraarticularly. All patients receive nonsteroidal antiinflammatory drugs, and oxycodonehydrochloride twice daily. Insufficient analgesia or breakthrough pain can be relieved by giving immediate-release oxycodonehydrochloride orally, or rescue drug nicomorphin intravenously (17).

Type of catheters and anaesthetic delivering devices

Local anaesthetic solution with epinephrine given at the end of surgery may provide sufficient postoperative analgesia lasting for 16 to 20 h (10). This period is usually quite short, and continuous infusion of local anaesthetics offers more efficient early postoperative analgesia, especially during postoperative mobilization. Different types of catheters were used for the postoperative wound infiltration. Some authors successfully used standard epidural catheters (7, 16, 18). The others used special multichannel soaker catheters designed to infuse local anaesthetic over a wider area (from 2.5 up to 25 cm in length). Such soaker catheters deliver the same dose through each perforation hole, and can be used for post-operative pain relief in large incisions. Special devices are supplied with one or two catheters with tips at the opposite sides of operative wound (8, 19).

Recently, new methods and devices were developed to allow application of LAs in the hospital and ambulatory patients. Different types of disposable elastomeric continuous infusion pumps were efficiently used to deliver local anaesthetic infusion (1, 2). The major disadvantage of such devices is their inability to provide sufficient analgesia for painful periods of patient mobilization. Continuous infusion pumps specially designed for postoperative patient controlled analgesia (PCA) are more flexible, and they allow in-process dose adjustment. PCA pumps allow delivery of continuous drug doses that provide suf-

ficient analgesia for resting periods, and supplemental drug doses for the periods of daily activities.

Several studies evaluating administration of local anaesthetics with continuous infusion pump systems for cardiothoracic, orthopaedic, general, and gynaecologic-urologic surgical procedures found a reduction in pain scores and an improvement in patient satisfaction (5).

Drugs, doses and concentrations

Almost all LAs can be effectively used for wound infiltration, but long acting and less toxic LAs are preferred. Levobupivacaine and ropivacaine have a clinical profile similar to that of bupivacaine, and minimal differences reported between the three anaesthetics are mainly related to the slightly different anaesthetic potency, with racemic bupivacaine > levobupivacaine > ropivacaine (20). However, bupivacaine is capable to result in the most severe muscle damage after serial or continuous intramuscular administration (20). Also, the reduced toxic potential of the two left-isomers suggests their use in the situations in which the risk of systemic toxicity related to either overdosing or unintended intravascular injection is high. Situations possibly increasing risk of systemic toxicity are continuous wound infiltration or peripheral nerve blocks, which are commonly constitutive elements of postoperative multimodal analgesic regimens (20). Assuming relative potencies, ropivacaine dose must be increased by 25–40% to achieve equipotency, and it is to be investigated whether ropivacaine really is less cardiotoxic.

Ropivacaine in the concentrations 0.1% and 0.2% respectively, had almost equal analgesic efficacy when used for wound instillation in the patients undergoing total abdominal hysterectomy (7). In that patient group both 220 and 440 mg ropivacaine in the continuous infusion over 24 hours produced satisfactory analgesia without toxic symptoms during the first 24 postoperative hours. Moreover, Stringer reported that ropivacaine 2.5% up to the daily dose of 800 mg, produced no toxic symptoms in none of 45 patients after total hip or joint arthroplasty (10). Some of concentrations and drug regimens used for postoperative wound infiltration are shown on Table 1.

Although more toxic in the preclinical studies, bupivacaine 0.25 - 0.5% was confirmed as safe and effective in the continuous infusion of 2 mL h⁻¹ through one or two catheters for the postoperative pain management (2, 16, 17, 19).

Other drugs used for wound infiltration

Other agents that can be efficiently used with LAs are epinephrine, ketorolac and nonsteroidal anti-inflammatory drugs (6, 17, 22). Epinephrine is well known adjuvant to LAs. It may prolong the effects of local anaesthetics, delaying their peak plasma concentration for several hours and reducing toxic effects (21). The addition of ketorolac significantly reduces morphine consumption, increases pain relief, and reduces duration of nausea compared to the use of intravenous morphine (17, 19, 22). Nonsteroidal anti-inflammatory drugs (NSAIDs) may be valuable supplement for the infiltration analgesia in painful areas, where anti-inflammatory affects were sup-

posed to decrease fibrous tissue proliferation. In the Lavand'homme's study continuous local diclofenac infusion significantly reduced postoperative morphine consumption in comparison with saline infusion and systemic diclofenac without adverse effects. Postoperative analgesia produced by diclofenac infusion was as effective as local ropivacaine infusion with systemic diclofenac in the patients after elective caesarean delivery (6).

EFFECTIVENESS

The effectiveness of wound infiltration is usually shown in the terms of decreased VAS scores and narcotic consumption, but also in the terms of earlier patient mobilization. The majority of wound infiltration protocols presented in Table 1 are more efficient than infusion of saline and standard opioid or nonsteroidal analgesic postoperative pain treatment (1). Even single shot intraoperative wound infiltration reduces the median time to first analgesic, the VAS scores, the use of analgesic medication on the first postoperative day, and increases number of patients using no analgesic. The effects were significant in the first postoperative day, but not thereafter (12). After that period analgesia was the same as in the control group (12). A study of Hariharan failed to confirm that wound infiltration before and/or after surgical incision may significantly decrease the incidence of postoperative pain after total abdominal hysterectomy (23).

Continuous wound infiltration is better alternative to single shot wound infiltration and postoperative opioid for prolonged analgesia. But, its usefulness for the postoperative analgesia strongly depends on the type of surgery.

In the several studies continuous wound infiltration was efficient for the postoperative analgesia in the breast



Figure 3. A breast cancer patient after quadreantectomy with axillary lymph node dissection carrying PCA pump delivering local anaesthetic levobupivacaine. PCA pump allows dose adjustment which is usually required in the obese or underweight patients.

cancer patients and after inguinal herniorrhaphy (1, 3). In the breast cancer patients paravertebral block showed a significant reduction in postoperative pain and reduced painful restricted movement four hours after surgery, whereas the wound infiltration was more efficient 16 and 24 h after surgery (3).

It was therefore used for postoperative analgesia in ambulatory surgical procedures in that patient category. Wound infiltration was more effective than systemic analgesic therapy in the patients undergoing gynaecological operations and elective caesarean delivery (6, 7, 18). However, in the major abdominal surgery it demonstrated no benefits over saline and systemic opioid (8).

Wound infiltration efficiently controlled pain in the thoracotomy patients, providing good analgesia along the intercostal wound (Figure 1, 2.). A recent study conducted by Forastiere and co-workers confirmed that wound infiltration as a part of multimodal approach was efficient in the patients undergoing open nephrectomy with intercostal incision (19). Authors examined the effects of 0.5% ropivacaine using an elastomeric pump which delivered 4 ml h⁻¹ over 48 h through two multihole catheters placed between the transverse and the internal oblique muscles and the subcostal space. All patients received PCA and ketorolac. Wound infiltration with ropivacaine improved pain relief and accelerated recovery and discharge (19).

Continuous wound infiltration is useful for postoperative analgesia in orthopaedic surgery too. The continuous infiltration and wound perfusion with ropivacaine was more effective in controlling pain than systemic analgesia after posterior lumbar arthrodesis (15) and after major joint replacement surgery. Despite more effective in controlling postoperative pain than systemic analgesia (9), local infiltration with ropivacaine 0.2% was less efficient in the several studies comparing this method with nerve blocks in the orthopaedic surgery. Dauri and co-workers demonstrated that continuous femoral nerve block provides better analgesia than the continuous patellar tendon wound and intra-articular infusions after anterior cruciate ligament reconstruction with patellar tendon (24).

Therefore, postoperative infiltration analgesia technique for hip or knee replacement is usually a part of multimodal analgesic regimens (22). Although different drugs are used in the same patient, opioid sparing effects can be registered versus postoperative epidural analgesia (22). Andersen and colleagues supplemented local and intra-articular infiltration after hip arthroplasty with 1 g paracetamol orally 4 times a day, starting in the post-anaesthesia care unit. From 20 h postoperatively oxycodone hydrochlorid 10–20 mg was given twice daily as analgesic treatment to all patients (22). Stringer and co-workers prescribed regular oral anti-inflammatory medication: ibuprofen 400 mg 4 times with omeprazole 20 mg twice daily, and supplementary paracetamol, codeine, oxycodone, or tramadol rescue analgesia as necessary, to all patients (10). In the patients undergoing total joint arthroplasty multimodal perioperative analgesic regimen combined with early mobilization improves outcome by short-

ening length of hospital stay, improving pain control, and accomplishing therapy goals sooner with less narcotic consumption versus PCA through intravenous morphine or hydromorphone (25).

Vallejo and co-workers confirmed that both preincisional and postoperative wound bupivacaine infiltration lacks preemptive analgesic effects for segmental mastectomy (14). Consequently, a meta-analysis carried by Ong and colleagues confirmed that preemptive local anaesthetic wound infiltration improved analgesic consumption and time to first rescue analgesic request, but not postoperative pain scores (26).

The effects on chronic pain

The significantly reduced pain scores, earlier mobilization and reduced hospital stay were observed in the wound infiltration group versus epidural infusion group of the orthopaedic patients after hip arthroplasty (17). Both preincisional and postincisional wound infiltration can significantly reduce acute postoperative pain, although preemptive analgesic effect on the early postoperative pain was not confirmed (14, 23). Until now there are no well controlled studies that could confirm whether wound infiltration is capable to decrease the occurrence of chronic postoperative pain.

COMPLICATIONS

Among numerous papers investigating the effects of the wound infiltration technique on pain control and outcome, only few of them report complications and disadvantages of this method. Systemic toxic effects and plasma concentrations of local anaesthetics were investigated in the most of the studies.

Horn and co-workers evaluated the effects of 30 mL of 7.5 mg mL⁻¹ (or 225 mg) ropivacaine given as single dose for wound infiltration (27). They observed no toxic effects, whereas plasma concentrations of ropivacaine were fairly below the unbound toxic threshold, which is 0.6 µg mL⁻¹ for ropivacaine (27, 28). Doses used for continuous wound instillation presented in the Table 1 are lower than 225 mg, and consequently no one author reported toxic drug effects.

Wound infection, postoperative haematoma, and reactions to the foreign body are in the focus of the interests of surgeons and anaesthesiologist involved in the acute pain services. Although only a few authors presented the data on the postoperative surgical complications, no one of them confirmed significant positive correlation between wound instillation and infections. Vendittoli and co-workers observed no complications related to the infiltration of the local anaesthetic after an intra-articular catheter was in place for 72 h. No increased incidence of infection and delayed wound healing were observed.

Kristek and colleagues reported no difference in the occurrence of local wound infection, haematoma and pneumonia in the groups of patients with postoperative intercostal nerve blockade and post-thoracotomy catheter analgesia after catheter was in place for 72 h (16).

Cost of treatment

A cost of treatment, which seems to be considerably higher in the wound infiltration technique, may become an important disadvantage of this method from the health care officers' point of view. Schurr reported that additional costs associated with this technique may limit its widespread use in clinical practice (1). Contrary, Forastiere and co-workers reported that postoperative wound infiltration improved pain relief, decreased hospital stay and resulted in the overall savings of approximately 273 Euros per patient (19). To confirm or reject this observation more detailed cost-benefit studies have to be undertaken to calculate real costs of this method as compared to other analgesic regimens. Such studies should consider not only effects on the pain control, but also the cost of complications, the cost of hospital stay, patient recovery and functional outcome.

REFERENCES

- SCHURR M J, GORDON D B, PELLINO T A, SCANLON T A 2004 Continuous local anaesthetic infusion for pain management after outpatient inguinal herniorrhaphy. *Surgery* 136: 761–769
- LEBLANC K A, BELLANGER D, RHYNES V K, HAUSMANN M 2005 Evaluation of continuous infusion of 0.5% bupivacaine by elastomeric pump for postoperative pain management after open inguinal hernia repair. *J Am Coll Surg* 200: 198–202
- SIDIROPOULOU T, BUONOMO O, FABBI E, SILVI M B, KOSTOPANAGIOTOU G, SABATO A F, DAURI M 2008 A prospective comparison of continuous wound infiltration with ropivacaine versus single-injection paravertebral block after modified radical mastectomy. *Anesth Analg* 106: 997–1001
- DAGTEKIN O, HOTZ A, KAMPE S, AUWEILER M, WARM M 2008 Postoperative analgesia and flap perfusion after pedicled TRAM flap reconstruction – continuous wound instillation with ropivacaine 0.2%. A pilot study. *Exp Neurol* 214: 301–308
- HELLER L, KOWALSKI A M, WEI C, BUTLER CE 2008 Prospective, randomized, double-blind trial of local anaesthetic infusion and intravenous narcotic patient-controlled anesthesia pump for pain management after free TRAM flap breast reconstruction. *Plast Reconstr Surg* 122: 1010–1018
- LAVAND'HOMME P M, ROELANTS F, WATERLOOS H, DE KOCK M F 2007 Postoperative analgesic effects of continuous wound infiltration with diclofenac after elective cesarean delivery. *Anesthesiology* 106: 1220–1225
- ZOHAR E, SHAPIRO A, PHILLIPOV A, HOPPENSTEIN D, KLEIN Z, FREDMAN B 2004 The postoperative analgesic efficacy of wound instillation with ropivacaine 0.1% versus ropivacaine 0.2%. *J Clin Anesth* 16: 399–404
- FREDMAN B, ZOHAR E, TARABYKIN A, SHAPIRO A, MAYO A, KLEIN E, JEDEIKIN R 2001 Bupivacaine wound instillation via an electronic patient-controlled analgesia device and a double-catheter system does not decrease postoperative pain or opioid requirements after major abdominal surgery. *Anesth Analg* 92: 189–193
- BIANCONI M, FERRARO L, TRAINA G C, ZANOLI G, ANTONELLI T, GUBERTI A, RICCI R, MASSARI L 2003 Pharmacokinetics and efficacy of ropivacaine continuous wound instillation after joint replacement surgery. *Br J Anaesth* 91: 830–835
- STRINGER B W, SINGHANIA A K, SUDHAKAR J E, BRINK R B 2007 Serum and wound drain ropivacaine concentrations after wound infiltration in joint arthroplasty. *Arthroplasty* 22: 884–892
- RAWAL N 2008 Postdischarge complications and rehabilitation after ambulatory surgery. *Curr Opin Anaesthesiol* 21: 736–42
- AUSEMS M E, HULSEWÉ K W, HOOYMANS P M, HOOFWIJK A G 2007 Postoperative analgesia requirements at home after inguinal hernia repair: effects of wound infiltration on postoperative pain. *Anaesthesia* 62: 325–331
- MORISAKI H, MASUDA J, FUKUSHIMA K, IWAO Y, SUZUKI K, MATSUSHIMA M 1996 Wound infiltration with lidocaine prolongs postoperative analgesia after haemorrhoidectomy with spinal anaesthesia. *Can J Anaesth* 43: 914–918
- VALLEJO M C, PHELPS A L, SAH N, ROMEO R C, FALK J S, JOHNSON R R, KEENAN D M, BONAVENTURA M A, EDINGTON H D 2006 Preemptive analgesia with bupivacaine for segmental mastectomy. *Reg Anesth Pain Med* 31: 227–232
- BIANCONI M, FERRARO L, RICCI R, ZANOLI G, ANTONELLI T, GIULIA B, GUBERTI A, MASSARI L 2004 The pharmacokinetics and efficacy of ropivacaine continuous wound instillation after spine fusion surgery. *Anesth Analg* 98: 166–172
- KRISTEK J, KVOLIK S, ŠAKIĆ K, HAS B, PRLIĆ L 2007 Intercostal catheter analgesia is more efficient vs. intercostal nerve blockade for post-thoracotomy pain relief. *Coll Antropol* 31: 561–566
- ANDERSEN K V, PFEIFFER-JENSEN M, HARALDSTED V, SØBALLE K 2007 Reduced hospital stay and narcotic consumption, and improved mobilization with local and intraarticular infiltration after hip arthroplasty: a randomized clinical trial of an intra-articular technique versus epidural infusion in 80 patients. *Acta Orthop* 78: 180–186
- ZOHAR E, FREDMAN B, PHILLIPOV A, JEDEIKIN R, SHAPIRO A 2001 The analgesic efficacy of patient-controlled bupivacaine wound instillation after total abdominal hysterectomy with bilateral salpingo-oophorectomy. *Anesth Analg* 93: 482–487
- FORASTIERE E, SOFRA M, GIANNARELLI D, FABRIZI L, SIMONE G 2008 Effectiveness of continuous wound infusion of 0.5% ropivacaine by On-Q pain relief system for postoperative pain management after open nephrectomy. *Br J Anaesth* 101: 841–847
- ZINK W, GRAF B M 2008 The toxicity of local anaesthetics: the place of ropivacaine and levobupivacaine. *Curr Opin Anaesthesiol* 21: 645–650
- RUBIN J P, BIERMAN C, ROSOW C E, ARTHUR G R, CHANG Y, COURTISS E H, MAY J W JR 1999 The tumescent technique: the effect of high tissue pressure and dilute epinephrine on absorption of lidocaine. *Plast Reconstr Surg* 103: 990–996
- ANDERSEN L J, POULSEN T, KROGH B, NIELSEN T 2007 Postoperative analgesia in total hip arthroplasty: a randomized double-blinded, placebo-controlled study on perioperative and postoperative ropivacaine, ketorolac, and adrenaline wound infiltration. *Acta Orthop* 78: 187–192
- HARIHARAN S, MOSELEY H, KUMAR A, RAJU S 2009 The effect of preemptive analgesia in postoperative pain relief – a prospective double-blind randomized study. *Pain Med* 10: 49–53
- DAURI M, FABBI E, MARIANI P, FARIA S, CARPENEDO R, SIDIROPOULOU T, CONIGLIONE F, SILVI M B, SABATO A F 2009 Continuous femoral nerve block provides superior analgesia compared with continuous intra-articular and wound infusion after anterior cruciate ligament reconstruction. *Reg Anesth Pain Med* 34: 95–99
- PETERS C L, SHIRLEY B, ERICKSON J 2006 The effect of a new multimodal perioperative anaesthetic regimen on postoperative pain, side effects, rehabilitation, and length of hospital stay after total joint arthroplasty. *J Arthroplasty* 21 (Suppl 2): 132–138
- ONG C K, LIRK P, SEYMOUR R A, JENKINS B J 2005 The efficacy of preemptive analgesia for acute postoperative pain management: a meta-analysis. *Anesth Analg* 100: 757–773
- HORN E P, SCHROEDER F, WILHELM S, WAPPLER F, SESSLER D I, UEBE B, STANDL T, SCHULTE A M, ESCH J 1999 Wound infiltration and drain lavage with ropivacaine after major shoulder surgery. *Anesth Analg* 89: 1461–1466
- KNUDSEN K, BECKMAN SUURKULA M, BLOMBERG S, SJÖVALL J, EDVARDSSON N 1997 Central nervous and cardiovascular effects of i.v. infusions of ropivacaine, bupivacaine and placebo in volunteers. *Br J Anaesth* 78: 507–514
- VENDITTOLI P A, MAKINEN P, DROLET P, LAVIGNE M, FALLAHA M, GUERTIN M C, VARIN F 2006 A multimodal analgesia protocol for total knee arthroplasty. A randomised controlled study. *J Bone Joint Surg Am* 88: 282–289
- TALBOT H, HUTCHINSON S P, EDBROOKE D L, WRENCH I, KOHLHARDT S R 2004 Evaluation of a local anaesthesia regimen following mastectomy. *Anaesthesia* 59: 664–667
- SCHELL S R 2006 Patient outcomes after axillary lymph node dissection for breast cancer: use of postoperative continuous local anaesthesia infusion. *J Surg Res* 134: 124–132