

# The Positioning of the c-arm and the Patient During the Minimally Invasive pain Treatment

---

**Radoš, Ivan**

*Source / Izvornik:* **Periodicum biologorum, 2011, 113, 283 - 289**

**Journal article, Published version**

**Rad u časopisu, Objavljena verzija rada (izdavačev PDF)**

*Permanent link / Trajna poveznica:* <https://um.nsk.hr/um:nbn:hr:239:389165>

*Rights / Prava:* [In copyright](#)/[Zaštićeno autorskim pravom.](#)

*Download date / Datum preuzimanja:* **2025-03-10**



*Repository / Repozitorij:*

[Repository UHC Osijek - Repository University  
Hospital Centre Osijek](#)



## The positioning of the c-arm and the patient during the minimally invasive pain treatment

IVAN RADOŠ

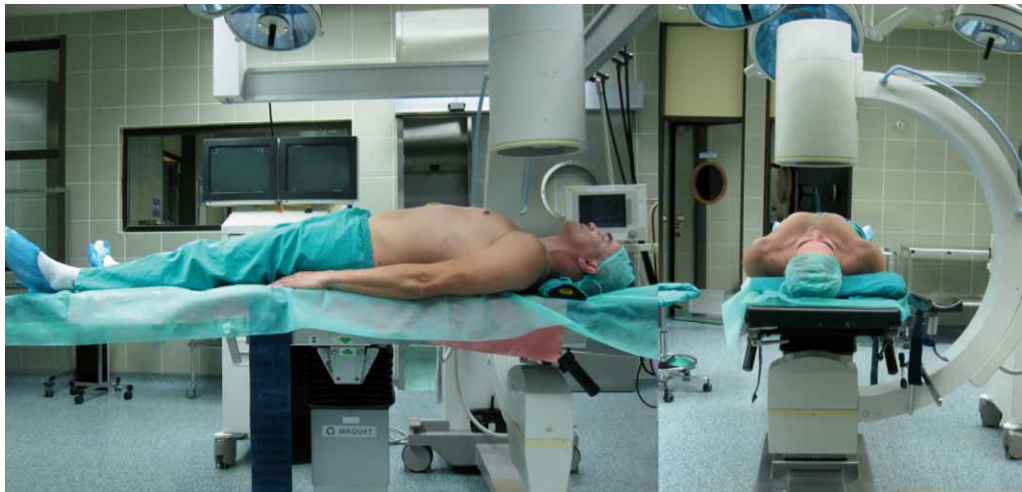University Hospital Centre Osijek, Croatia  
Department of Anaesthesiology and Intensive  
Care, J. Huttlera 4, 31 000 Osijek, Croatia  
Email: ivan.rados@os.t-com.hr

**Key words:** c-arm, invasive pain  
management, patient positioning

### Abstract

*Minimally invasive procedures in pain treatment are an important supplement to conservative pain treatments, to pharmacotherapy as well as to non-pharmacological procedures when these are insufficient as pain treatments. The level of success depends on a careful pick of patients, as well as on the skill and proficiency of the doctor performing the minimally invasive procedures. Up to this point the results of many studies on minimally invasive procedures in pain treatment have been opposed, with the epidural placement of the syringe being unsuccessful in 40% of the cases, even with an experienced anaesthesiologist performing the procedure. Not using the fluoroscope is certainly one of the reasons to such a high level of set-back. The fluoroscope, which has become a standard part of many invasive procedures, is held responsible for the greater efficiency and fewer complications during invasive procedures, all resulting in the increase of minimally invasive pain treatment procedures over all.*

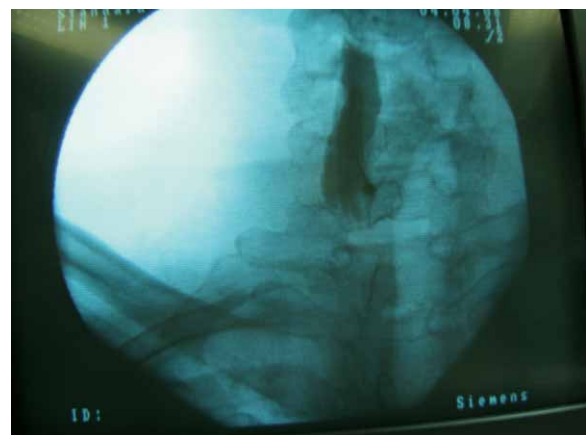Minimally invasive procedures in pain treatment are an important supplement to conservative pain treatments, to pharmacotherapy as well as to non-pharmacological procedures when these are insufficient as pain treatments. The level of success depends on a careful pick of patients, as well as on the skill and proficiency of the doctor performing the minimally invasive procedures. Just until recently, many minimally invasive procedures were performed without fluoroscopic control, with the precise of the procedure depending on the doctor's skill, and also of the pathoanatomic characteristics of the patient. Many regional blockades are possible to perform with the scrutiny of the nerve stimulator or ultrasound, but despite the diagnostic progress, the fluoroscope together with CT has remained the option of choice in many spinal procedures. The use of fluoroscopy has revolutionized interventional pain management. These procedures include interventions for back pain such as epidural steroid injections, facet joint injection, facet nerve block and rhizotomy, sacroiliac joint injection, discography, placement of spinal cord stimulator, and the intradiscal electrothermal coagulation procedure, and vertebroplasty. Fluoroscopy is required in the more difficult procedures where precise needle placement is required. In clinical practice the fluoroscope is used more often than the CT, the reason probably being easy accessibility and use in the case of minimally invasive procedures. Up to this point the results of many studies on minimally invasive procedures in pain treatment have



**Figure 1.** Position for stellate ganglion block.

been opposed, with the epidural placement of the syringe being unsuccessful in 40% of the cases, even with an experienced anaesthesiologist performing the procedure (1, 2). Not using the fluoroscope is certainly one of the reasons to such a high level of set-back. The fluoroscope enables us to monitor the needle, and the use of contrast confirms the diffusion of the injected fluid into the correct area, thus excluding the possibility of intravascular injections of the contrast fluid. The fluoroscope, which has become a standard part of many invasive procedures, is held responsible for the greater efficiency and fewer complications during invasive procedures, all resulting in the increase of minimally invasive pain treatment procedures over all (3). Before the invasive procedure the patient is comprehensively informed about the benefits and possible risks of each specific procedure, and then signs the informed consent form for the said procedure. The procedure is performed in a sterile operation room, with a team formed by a doctor, a nurse and a radiology technician. The patient is monitored during the procedure, blood pressure, heart frequency and blood saturation, and also having an intravascular approach. The doctor performing the procedure need to be protected with a lead apron, security collar and radiation protection glasses. The patient approach the scheduled procedure on an empty stomach and after the procedure the patient remains monitored for a period of time, after which they are released unless hospitalization is needed.

Nerve damage may occur during the supine position, most often due to pressure on the brachial plexus and ulnar nerve. It's therefore crucial to avoid hyperextension of the arm at the shoulder juncture when positioning the patient in the supine position and also check for any pressure to the elbow against the edge of the operation table, or to the upper arm of the security frame. The supine position of the patient with the head thrown back demands particular attention due to the relatively frequent and long-lasting post-interventional cervical neuropathy that are the results of insufficient positioning on the operation table (4-8).



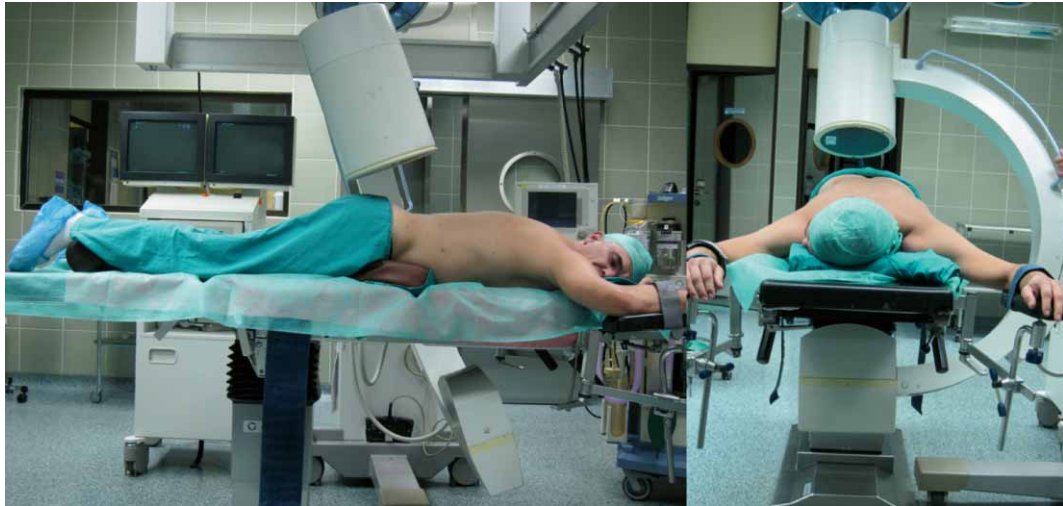**Figure 2.** The spreading of the radiographic contrast during stellate ganglion block.

The stellate ganglion is the lowest of the three ganglia of the cervical sympathetic nervous system. The three ganglia and the sympathetic chain lie on the prevertebral fascia in the neck. Stellate ganglion block is useful in treatment of a variety of painful conditions, including Raynaud's disease, arterial embolism in the area of the arm, accidental intraarterial injection of drugs, Meniere's syndrome, and acute herpes zoster of the face and lower cervical and upper thoracic dermatomes.

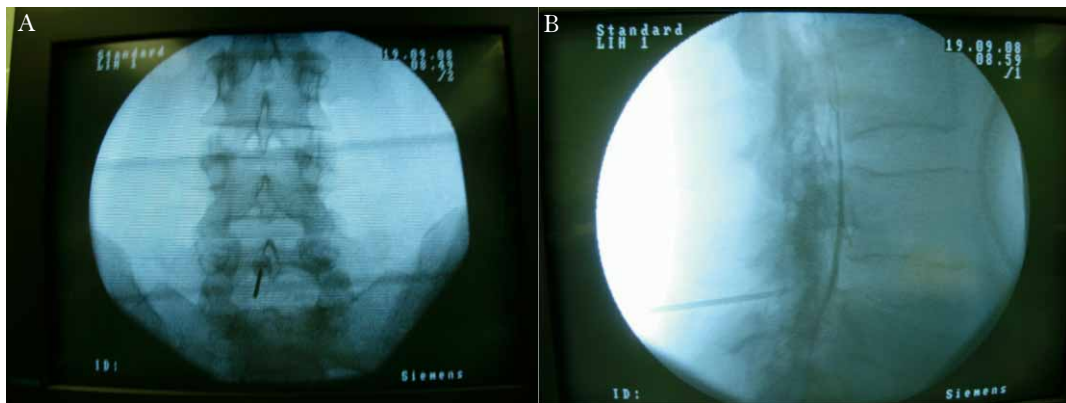
The patient is in a supine position with the head raised and extended, as for endotracheal intubation. A pillow beneath the upper back and lower neck. The c-arm is positioned in a direct anterior-posterior plane during the full duration of the procedure. (Figure 1, 2).

The administration of local anaesthetics or steroids via the lumbar approach to the epidural space is useful in a variety of chronic benign pain syndromes, including lumbar radiculopathy, and low back pain syndromes (9-11).

The patient is positioned prone during the procedure. To reduce the lumbar lordosis and facilitate the proce-



**Figure 3.** The positioning of the patient during lumbar interlaminar epidural injection.



**Figure 4.** A. Anterior-Posterior radiograph of the lumbar spine during interlaminar lumbar epidural injection. B. Lateral radiograph of the lumbar spine during interlaminar lumbar epidural injection.

ture, a pillow is placed under the abdomen. A pillow is placed under the patient's foot for greater comfort. The arms are stretched out in front of the body. During the initial phase of the procedure the C-arm is angled 15 to 20 degrees caudally from the axial plane, later the positioning of the syringe and the spreading of the injection is monitored with lateral radiographical recording with the C-arm. (Figure 3, 4). With the prone position the patient's head is placed lower than the heart, thus causing venous congestion in the head and neck area. Due to the pressure on the visceral organs, the cranial diaphragm is suppressed which leads to a deterioration of the pulmonary elasticity, thus with the position of reduced extrusion of the thoracic wall, the act of breathing is additionally augmented and demands larger inhalation pressure. Possible damages to the eye, brachial plexus and ulnar nerve are thus results of insufficient positioning of the patient (4-8).

The patient is for lumbar transforaminal and selective nerve root injection positioned supine with c-arm axis

rotated obliquely 20 to 30 degrees (Figure 5, 6). To reduce the lumbar lordosis and increase the distance between spinous process, a pillow is placed under the abdomen. This also mitigates perform the procedure.

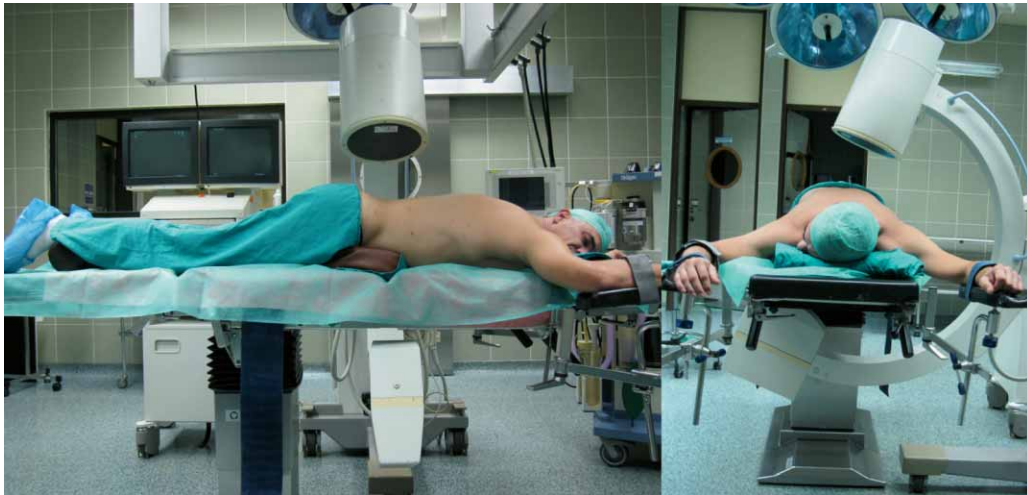Caudal epidural nerve block is carried out with the patient in either the prone or lateral position. Each position has its advantages and disadvantages. The prone position is easier for the pain management physician, but it may not be an option if the patient cannot rest comfortably on the abdomen or wears an ostomy appliance, such as colostomy or ileostomy bag. The prone position limits easy access to the airway, which might be needed if problems occur during the procedure. The lateral position affords access to the airway but makes the approach technically more demanding.

The patient is placed prone with the head turned to one side, with a pillow placed under the pubic area. The c-arm is angled 20 to 30 degrees caudally from the axial plane (Figure 7). A caudal block may be used for any indication that recommends lumbar epidural block.

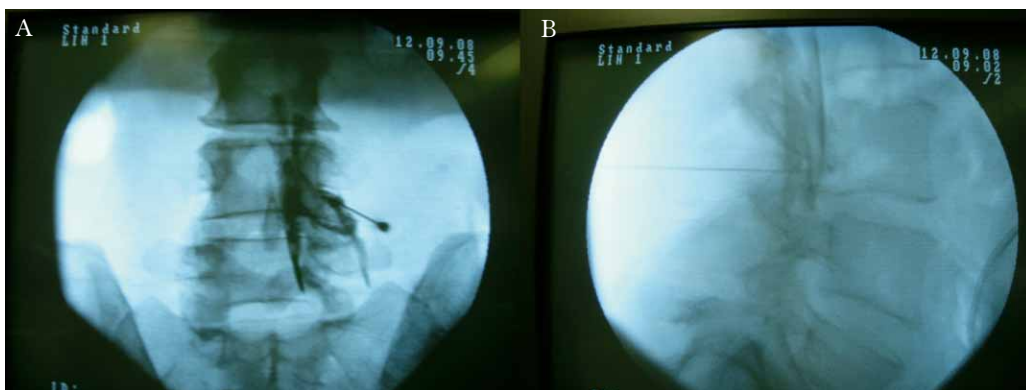


The spine is made up of seven cervical, twelve thoracic, and five lumbar vertebrae. The vertebrae articulate anteriorly through the disc and posteriorly through two facet joints (one right and one left). The facet joints are

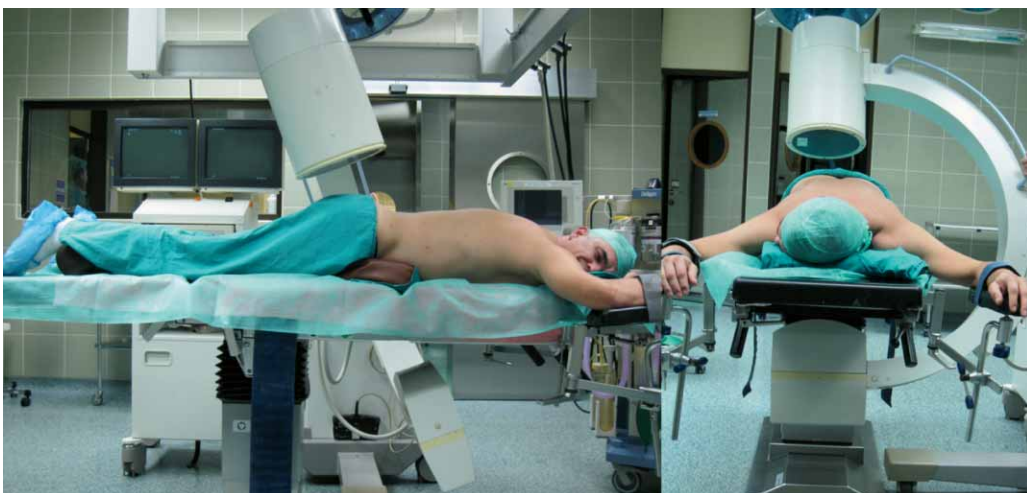
paired diarthroidal synovial joints formed by the inferior articular process of one vertebra and the superior articular process of the subjacent vertebra (12-15).



**Figure 5.** Patient position for lumbar transforaminal and selective nerve root injection.



**Figure 6.** A. Anterior-Posterior radiograph of the lumbar spine following lumbar transforaminal injection. B. Lateral radiograph of the lumbar spine following lumbar transforaminal injection.



**Figure 7.** Position for caudal epidural injection.

The patient is placed prone with a small headrest under the forehead to allow for air flow between the table and the patient's nose and mouth. The c-arm is angled 25 to 35 degrees caudally from the axial plane (Figure 8).

The patient is placed prone with the head turned to one side, with arms stretched out forward and over the head. The c-arm is angled 50 to 60 degrees caudally (Figure 9).

With the lateral „on the side“ position a pillow is placed between the legs, with the lower leg flexed at the knee and upper leg in a neutral position. The upper arm may be allowed to hang freely above the head or placed in an arm support (4-8).

The patient is placed on lateral side with a pillow under the head. The pillow should keep the cervical spina in alignment without lateral flexion to either side. The c-arm is placed directly over the patient's neck in the axial plane without angulation (Figure 10). Patient is placed prone with the head turned to one side. The

c-arm is positioned over the thoracic spine in a direct anterior-posterior plane without angulation (Figure 11).

The superior hypogastric plexus is a bilateral retroperitoneal structure situated at the level of the lower third of the L5 vertebral body and the upper third of the S1 vertebral body, at the sacral promontory and close to the bifurcation of the common iliac vessels (16-19). Superior hypogastric plexus block has proven utility for cancer related pelvic pain that is refractory to more conservative management.

The patient lies prone, with the head turned to one side. A pillow is placed under the lower abdomen, above the iliac crest, in an effort to reduce the lumbar lordosis. The c-arm is rotated 25 to 35 degrees obliquely and centered on the the lumbosacral junction. The c-arm is then angled in a cephalad direction, and the L5/S1 disc is brought into view with 25 to 35 degrees of angulation (Figure 12).

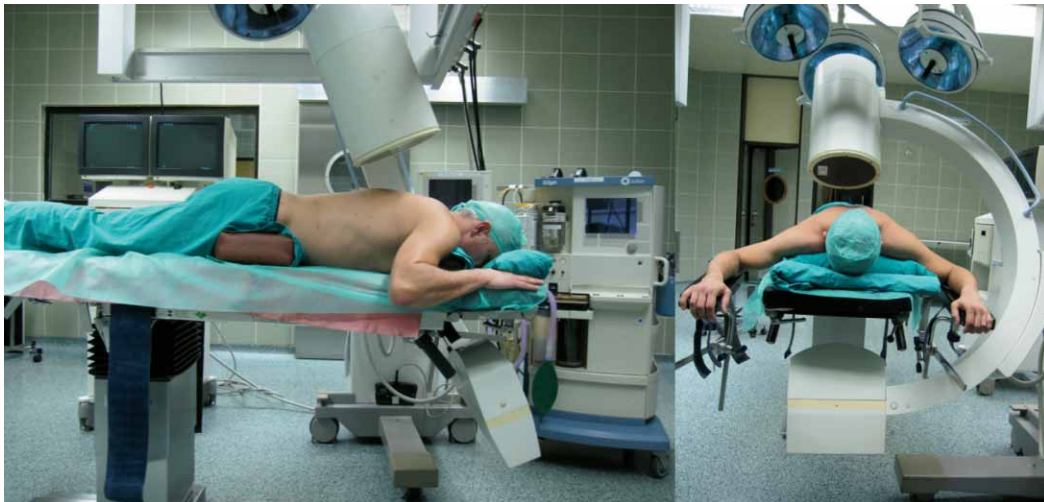


Figure 8. Position for intra-articular cervical facet joint injection.

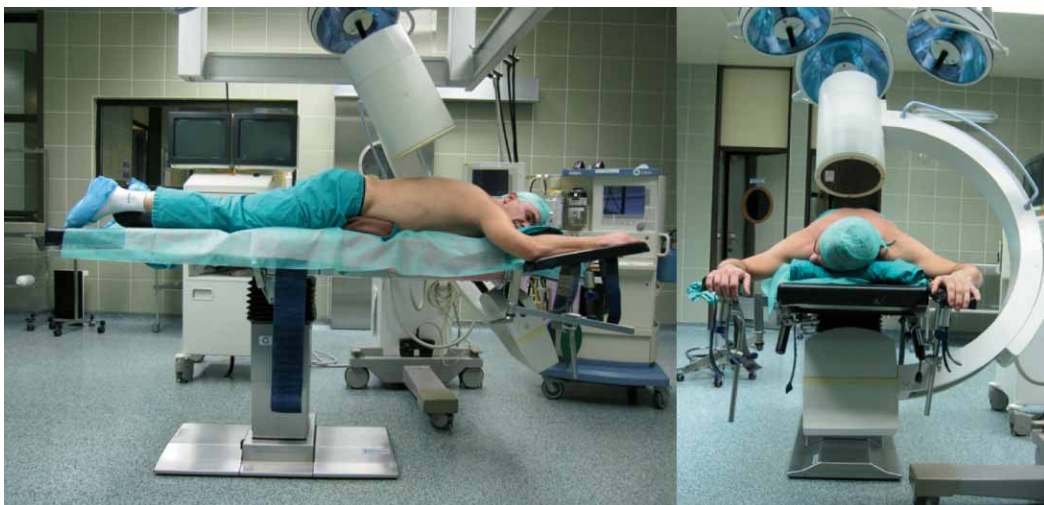
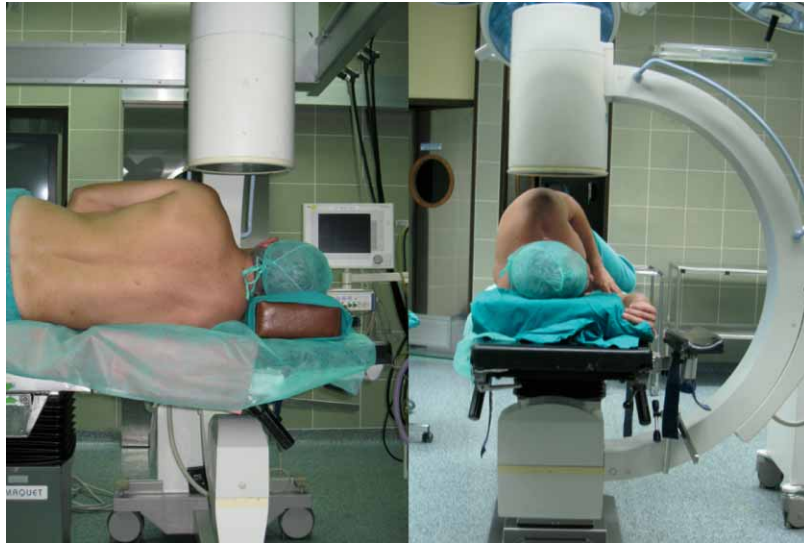
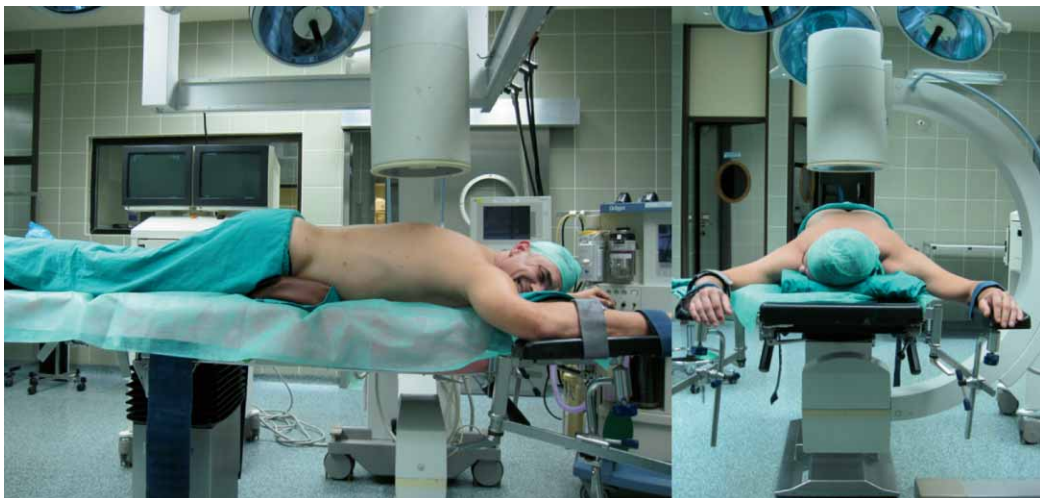


Figure 9. Position for intra-articular thoracic facet joint injection.

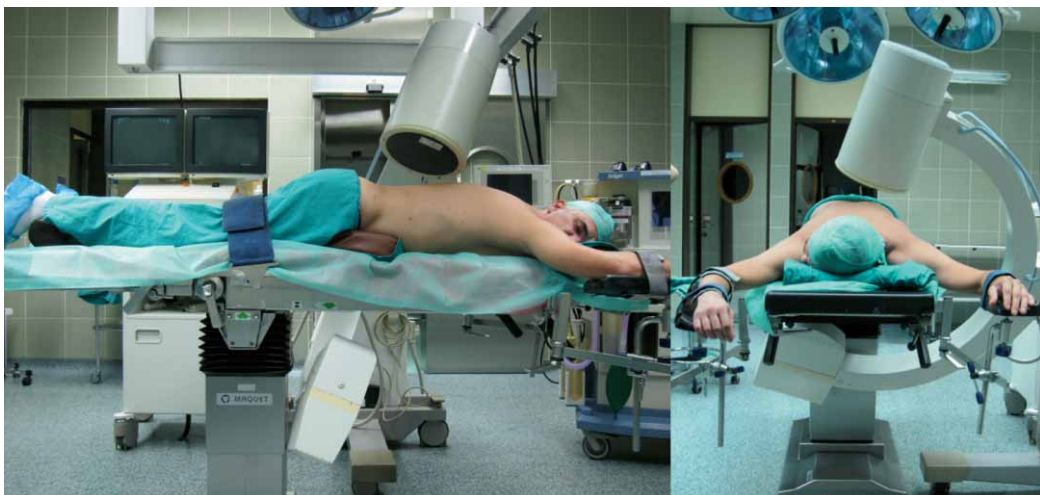




**Figure 10.** Position for cervical medial branch block and radiofrequency treatment (lateral approach).



**Figure 11.** Position for thoracic medial branch blocks and radiofrequency treatment.



**Figure 12.** Patient position for superior hypogastric plexus block.

## REFERENCES

1. WENSTEIN S M, HERRING S A, DERBY R 1995 Contemporary concepts in spine care. Epidural steroid injections. *Spine* 20: 1842-6.
2. LUTZ G E, VAD V, WISNESKY R J 1998 Fluoroscopic tranforaminal lumbar epidural steroids: An outcome study. *Arch Phys Med Rehab* 79: 1362-6
3. DEER T, RANSON M, KAPURAL L, DIWAN S 2009 Guidelines for the proper use of epidural steroid injections for the chronic pain. *Techniques in Regional Anesthesia and Pain Medicine* 13(4): 288-295
4. MARTIN T J 1994 Patient positioning. In: Barash P G, Cullen B F, Stoelting R K (ed) Clinical anesthesia. Lippincott-Raven interactive anesthesia library, CD-ROM 89434-89801
5. MILLER R D 1986 The immediate preinduction period In: Miller R D (ed) Anesthesia. Churchill Livingstone, p 399-408
6. BRODSKY J B 2002 Positioning the morbidly obese patients for anesthesia. *Obesity & Surgery* 12: 751-8
7. COPPIETERS M W, VAN DE VELDE M, STAPPAERTS K H 2002 Positioning in anesthesiology: toward a better understanding of stretch-induced perioperative neuropathies. *Anesthesiology* 97: 75-81
8. ŠUSTIĆ N I, ŠUSTIĆ V 1978 Operaciona dvorana i uvod u tehniku instrumentiranja. Otakar Keršovani, p 136-40
9. WALDMAN S D 1998 Lumbar epidural block. In: Waldman S D (ed) Atlas of Interventional Pain Management Techniques. WB Saunders, Philadelphia, p 308-317
10. WALDMAN S D, GREEK C R, GREENFIELD M A 1998 The caudal administration of steroid in combination with local anesthetics in the palliation of pain secondary to radiographically documented lumbar herniated disc—a prospective outcome study with six-month follow-up. *Pain Clinic* 11: 43
11. WILSON W L, WALDMAN S D 1992 Role of the administration of steroids and local anesthetics in the palliation of the pain secondary to vertebral compression fractures. *Pain Digest* 1: 294-295
12. STEIN M, ELLIOTT D, GLEN J, MORARA PROTZNER I 1993 Percutaneous facet joint fusion: Preliminary experiences. *Vasc Interv Radiol* 4: 69-74
13. DESTOUET J M, GILULA L A, MURPHY W A, MOUSEES B 1982 Lumbar facet joint injection: Indication, technique, clinical correlation, and preliminary results. *Radiology* 145: 321-325
14. SELBY D K, PARIS S V 1981 Anatomy of facet joint and its clinical correlation with low back pain. *Contemp Orthop* 3:1097-1103
15. MALDAGUE B, MATHURIEN P, MALGHERN J 1981 Facet joint arthrography in lumbar spondylolysis. *Radiology* 140: 9-36
16. PITKIN G 1953 Nervous System. In: Southworth J L, Hingson R A, Pitkin W M (eds) Conduction Anesthesia (ed 2). JB Lippincott, Philadelphia.
17. SNELL R S, KATZ J 1988 Clinical Anatomy for Anesthesiologists. Norwalk, Conn., Appleton and Lange, p 271
18. BRASS A 1983 Anatomy and physiology: Autonomic nerve and ganglia in pelvis. In: Netter F H (ed) The Ciba Collection of Medical Illustration, vol 1. Nervous System. Summit, NJ., Ciba Pharmaceutical, p 85
19. WOODBURN R T, BURKEL W E 1988 Essential of Human Anatomy. Oxford Press, New York, p 552