

Management and Prognosis of Primary Cerebral Melanocytic Tumors. A Case Report and Systematic Review

Splavski, Bruno; Mužević, Dario; Kovačević, Marko; Bajek, Goran

Source / Izvornik: **Journal of Neurological Surgery Part A: Central European Neurosurgery, 2015, 76, 144 - 148**

Journal article, Published version

Rad u časopisu, Objavljena verzija rada (izdavačev PDF)

<https://doi.org/10.1055/s-0034-1371514>

Permanent link / Trajna poveznica: <https://um.nsk.hr/um:nbn:hr:239:934298>

Rights / Prava: [In copyright](#) / [Zaštićeno autorskim pravom](#).

Download date / Datum preuzimanja: **2025-02-23**



Repository / Repozitorij:

[Repository UHC Osijek - Repository University Hospital Centre Osijek](#)

Management and Prognosis of Primary Cerebral Melanocytic Tumors. A Case Report and Systematic Review

Bruno Splavski¹ Dario Muzevic¹ Marko Kovacevic¹ Brano Splavski Jr.² Goran Bajek³

¹ Department of Neurosurgery, Osijek Clinical Hospital Centre, Osijek, Croatia

² Division of Ophthalmology, Osijek Clinical Hospital Centre, Osijek, Croatia

³ Department of Neurosurgery, Rijeka Clinical Hospital Centre, Rijeka, Croatia

Address for correspondence Dario Muzevic, MD, Department of Neurosurgery, Osijek Clinical Hospital Centre, Josipa Huttlera 4 Osijek 31000, Croatia (e-mail: dario.muzevic@me.com).

J Neurol Surg A 2015;76:144–148.

Abstract

Keywords

- ▶ primary melanocytic cerebral tumor
- ▶ management protocol
- ▶ prognosis
- ▶ systematic review

Primary melanocytic cerebral tumors form a spectrum of different lesions that range from benign to extremely malignant, such as an intracranial melanoma. This article points out some characteristics of primary melanocytic cerebral tumors and discusses their management and prognosis, based on a systematic literature review and a case of primary cerebral malignant melanoma.

Because the biological characteristics of primary melanocytic cerebral tumors remain unclear, it appears that total surgical resection of the tumor followed by oncologic treatment is the mainstay of the management. The prognosis still depends on the degree of malignancy.

Introduction

Primary melanocytic lesions of the central nervous system represent a set of various entities ranging from benign to highly malignant. These lesions include diffuse melanocytosis, melanocytoma, meningeal melanomatosis, and malignant melanoma.¹

Contrary to metastatic melanoma, which is the third most frequent tumor metastasizing to the brain,² primary melanocytic cerebral tumors are scarce, originating from melanocytes within the leptomeninges, which are pigment-producing cells of neural crest origin.^{3,4} In certain circumstances, these cells may assume neoplastic patterns.

Distinctive diagnostic tools are helpful in searching the source of the tumor and defining its biological performance. Accordingly, a variety of imaging modalities and pathohistologic techniques may be used to define the dignity of these considerably diverse lesions. However, the management for

the entire spectrum of such lesions are the same, consisting of gross tumor resection and oncologic treatment. Nonetheless, it seems that the prognosis is highly dependent on the degree of malignancy.

This article describes clinical, imaging, and pathohistologic features of primary melanocytic cerebral tumors, and discusses management strategies and prognosis, based on a systematic literature review and a case illustration of primary cerebral malignant melanoma.

Case Illustration

The presenting symptom of a 59-year-old man was right-side homonymous hemianopsia along with a headache. A computerized tomography (CT) of the brain with contrast enhancement and T1/T2-weighted magnetic resonance imaging (MRI) showed a parasagittal consistent mass lesion of the left occipital lobe with no meningeal dissemination. (▶ **Figs. 1** and **2A, B**) A clinical, dermatologic and ophthalmologic examination

received

April 17, 2013

accepted after revision

January 3, 2014

published online

July 21, 2014

© 2015 Georg Thieme Verlag KG
Stuttgart · New York

DOI <http://dx.doi.org/10.1055/s-0034-1371514>.
ISSN 2193-6315.

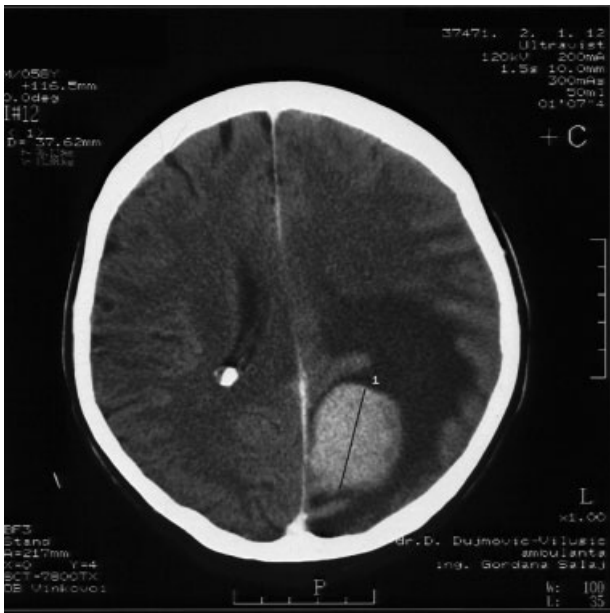

Fig. 1 Preoperative contrast-enhanced axial computerized tomography (CT) scan demonstrated a well-defined supratentorial homogeneous mass lesion located parasagittally in the left occipital lobe with perifocal edema and no leptomeningeal involvement.

ruled out the existence of extracranial, cutaneous, and/or chorioretinal melanoma.

The patient underwent a left-side occipital osteoplastic craniotomy and the tumor was removed. Light microscopy of tissue samples disclosed a pathohistologic feature similar to melanoma with highly cellular anaplastic tissue consisting of polymorphic, partly epithelioid, and spindle atypical melanocytes with hyperchromatic nuclei and sporadic mitoses (► **Fig. 3A, B**). Immunohistochemistry confirmed that the cells are diffusely positive for Melan A (► **Fig. 4A**), S-100 protein (► **Fig. 4B**), and vimentin, focally positive for Human Melanoma Black (HMB-45) antibody, and negative for glial fibrillary acidic protein (GFAP), epithelial membrane antigen (EMA), and pancytokeratin. Melanin pigment was detected in the tumor tissue.

The pathohistologic findings, together with the negative dermatologic and ophthalmologic examinations, suggested a primary cerebral melanoma.

Postoperative control contrast-enhanced axial CT showed no remaining tumor, and the patient's recovery was complete. At a 1-year clinical and neuroradiologic follow-up, the patient was without signs of recurrent disease.

Review of the Literature

Medline literature database was selected for the search. The search time frame was set from January 1983 to January 2013. All studies describing the treatment of central nervous system melanocytic lesions, irrespective of language, publication status and level of evidence, were included in the preliminary analysis. Then, articles describing secondary or spinal disease were excluded, leaving the articles describing the treatment

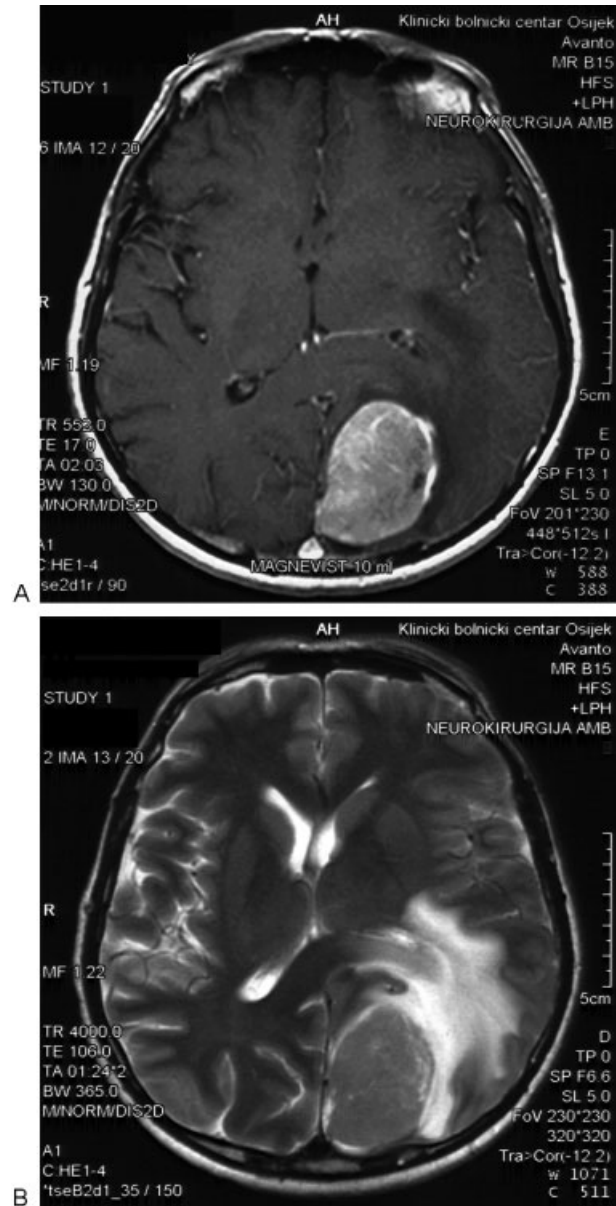


Fig. 2 (A) Preoperative T1-weighted axial magnetic resonance imaging (MRI) showed a well-delineated hyperintense, intensively contrast-enhancing tumor adjacent to the superior sagittal sinus and with a compressive effect onto surrounding brain parenchyma resembling a meningioma or a melanin-infested tumor. (B) Preoperative T2-weighted MRI revealed a homogeneous hypointense tumor localized in the left occipital lobe.

of primary central nervous system melanocytic lesions. Two of the authors analyzed the search results independently.

The preliminary search yielded 129 results. Based on title, abstract, and keywords, 38 articles were selected as potentially relevant, and these were obtained in a full text. After excluding intracranial secondary neoplasm and spinal localization of the disease, 14 articles remained for further analysis^{3,5-17} (► **Table 1**),

The following data were extracted: age, sex, treatment (surgery, irradiation, chemotherapy), pathohistologic diagnosis, and outcome.

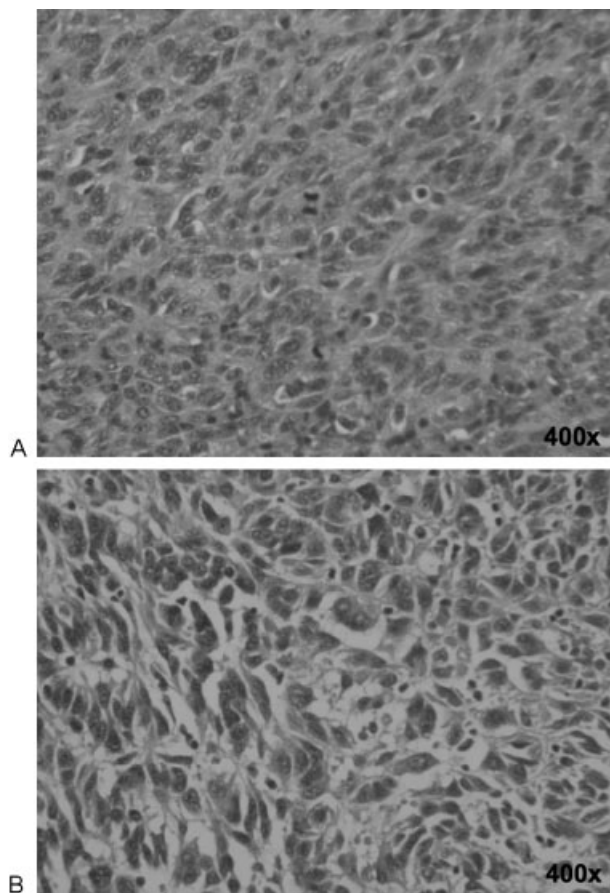


Fig. 3 (A) Light microscopic pathohistologic analysis (original magnification $\times 400$; hematoxylin-eosin stain) showed anaplastic tumor cells (atypical melanocytes) with a spindle cell appearance, pleomorphic nuclei, and typical mitotic forms. (B) Light microscopic pathohistologic analysis (original magnification $\times 400$; hematoxylin-eosin stain) depicted polymorphic variably pigmented, cytologically atypical melanocytic tumor cells arranged in loose nests.

A total of 37 patients from 14 studies were found. The median age was 36 years (range: 11–74 years). There were 20 male and 17 female patients. Pathohistologic diagnosis was melanoma in 26 patients, intermediate-grade melanocytoma in 3 patients, melanocytoma in 7 patients, and meningeal melanomatosis in 1 patient. All patients were surgically treated. Total resection was achieved in 23, subtotal resection in 10 patients, and 4 patients had tumor biopsy only. Twelve patients received radiotherapy, with doses ranging from 20 Gy to 60 Gy. Chemotherapy was performed in 3 patients. The combination of procarbazine, lomustine, and vincristine; nimustine, teniposide, temozolomide; and cis-platinum, dacarbazine, and bischloronitrosourea with carmustine, was applied in 1 patient each. The median disease-free survival was 20 months for patients with melanocytoma, and 13 months for patients with melanoma. **►Table 1** summarizes the data.

Discussion

No current evidence-based guidelines for diagnosis and management of primary cerebral melanocytic tumors exist.

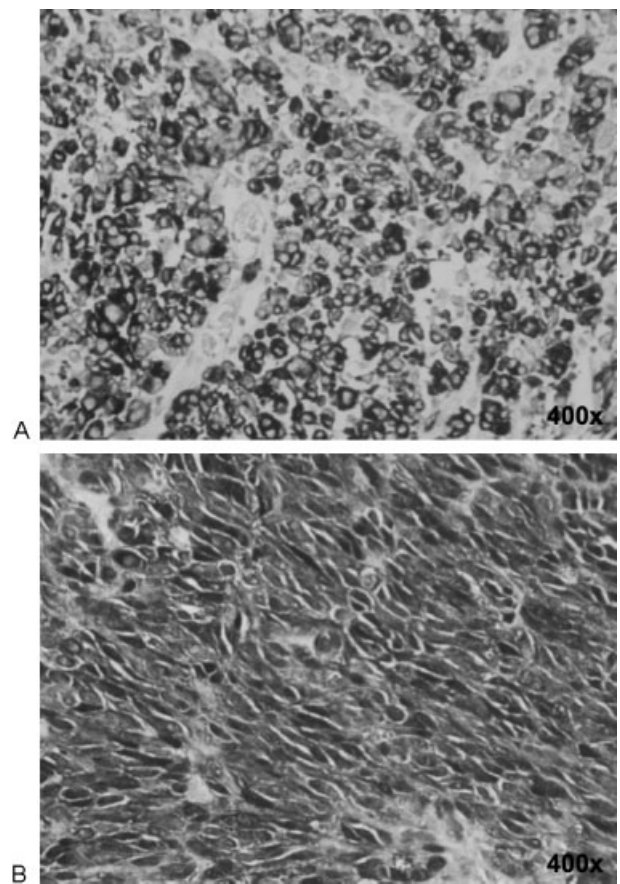


Fig. 4 (A) Immunohistochemistry (original magnification $\times 400$; Melan A) revealed that tumor cells were diffusely positive for Melan A protein. (B) Immunohistochemistry (original magnification $\times 400$; S-100) showed that tumor cells were expressing S-100 protein.

Therefore, we performed a systematic review of the literature that predominantly identified case reports and small case series (**►Table 1**).

There are several diverse types of cerebral melanocytic tumors including meningeal melanomatosis, melanocytoma, and primary malignant melanoma that is extremely rare and lacking any correlation with family history, sun-initiated skin damage, or precursor nevi. The dignity of these tumors varies considerably.

A variety of these tumors may present as solid intra- or extraaxial mass lesions with or without leptomeningeal extent.³ The clinical signs and symptoms are usually similar to those of other intracranial tumors, most frequently consisting of intracranial hypertension and focal neurologic deficit; our patient presented with homonymous hemianopsia. It is impossible to differentiate the different types of primary cerebral melanocytic tumor, and to estimate its dignity by neuroradiologic diagnostics only. To eliminate an extracerebral primary lesion, as well as a metastatic tumor, a meticulous clinical examination of the skin and eyes is necessary.¹⁸

Distinctive pathohistologic aspects are supportive in determining the tumor origin and in assessing its biological characteristics.¹⁷ Pigmented tumor cells arranged in tight

Table 1 Literature review: patients, therapeutic modalities, and outcome

Study	Patient age (yrs)/sex	Surgical resection	Radiotherapy	Chemotherapy	Histology	Disease-free survival, mo
Greco Crasto et al ³	74/M	Total	–	–	M	> 24
Bhandari et al ⁵	29/M	Subtotal	52.2 Gy	–	M	12
Jaiswal et al ⁶	23/M	Total	+	–	M	< 12
	22/M	Total	+	–	M	NA
	34/M	Total	+	–	MC	> 12
Gempt et al ⁷	71/F	Total	+	–	M	18
Navas et al ⁸	25/M	Total	NA	–	IM	< 1
Freudenstein et al ⁹	42/M	Total	55.2 Gy	–	M	> 96
	62/F	Total	20 Gy	+	M	< 4
	33/M	Subtotal	59.4 Gy	+	M	27
Rosenthal et al ¹⁰	30/M	Subtotal	–	–	M	< 1
	11/M	Biopsy	–	+	M	16
Pirinet et al ¹¹	68/F	Biopsy	–	–	MM	36
Whinney et al ¹²	29/F	Total	–	–	M	> 18
Amarti et al ¹³	22/F	Total	NA	–	M	< 1
	48/M	Total	NA	–	M	NA
	51/M	Biopsy	NA	–	M	NA
	65/F	Total	NA	–	M	NA
Fish et al ¹⁴	44/M	Biopsy	NA	–	M	12
Braga et al ¹⁵	72/F	Total	–	–	M	< 1
Golubicić et al ¹⁶	12/M	Subtotal	60 Gy	–	M	12
Brat et al ¹⁷	46/M	Total	–	–	M	> 14
	36/M	Total	NA	–	M	22
	41/F	Total	50.4 Gy	–	M	36
	31/F	Subtotal	–	–	M	34
	48/F	Subtotal	–	–	M	9
	36/M	Subtotal	+	–	M	< 1
	25/F	Subtotal	+	–	M	> 76
	15/F	Subtotal	–	–	M	> 12
	17/F	Total	–	–	MC	> 20
	40/F	Total	–	–	MC	> 56
	16/F	Total	–	–	MC	> 6
	41/F	Total	–	–	MC	> 19
	66 F	Total	–	–	MC	> 36
	31 M	Total	–	–	MC	> 31
	53/M	Total	–	–	IM	> 17
68/M	Subtotal	–	–	IM	> 5	

Abbreviations: IM, intermediate-grade melanocytoma; M, melanoma; MC, melanocytoma; MM, meningeal melanomatosis; NA, data not available.

sheets encompassing regular nuclei together with the absence of mitotic activity are typical for melanocytoma.¹⁹ Cerebral malignant melanoma is often suspected when cytologically atypical and mitotically active melanin-pigmented pleomorphic cells, rising in loose-fitting shells encircling eosinophilic hyperchromatic nuclei, are found (►Fig. 2A, B). Moreover, immunoreactivity indicates expression of melanocytic marker proteins (S-100, Melan A, and HMB-45) (►Figs. 2A, B and 3A, B). In our patient, the diagnosis of a malignant cerebral melanoma was made.

According to the literature review, a complete tumor resection appears as the best treatment modality and is highly associated with a better prognosis. Because the biological behavior of a primary cerebral melanoma is unpredictable and recurrence may occur following incomplete resection, some authors also suggest postoperative whole brain radiation therapy to improve the outcome.⁹ Regarding the prognosis, the data in the literature are inconsistent, which prevents well-reasoned conclusions. However, some authors assume a better long-term outcome of primary melanocytic cerebral tumors in comparison with metastatic melanoma.³ Others even reported a 12-year survival after the diagnosis of primary malignant melanoma.^{3,20,21} Regardless of the tumor dignity, radical tumor resection is the mainstay of the management.

Radiotherapy, chemotherapy, and immunotherapy may be considered as nonsurgical options, but their efficacy is not yet proven.³

Conclusion

Reviewing the literature, it seems that the prognosis of primary cerebral melanocytic tumors remains highly dependent on their dignity with more malignant lesions having a poorer outcome. Complete surgical resection, if possible, seems to be the main treatment option.

References

- 1 Brat DJ, Perry A. Melanocytic lesions. In: Louis DN, Ohaki H, Wiestler OD, Cavenee WK, eds. WHO Classification of Tumours of the Central Nervous System. 4th ed. Lyon, France: IARC Press; 2007:181–183
- 2 Isiklar I, Leeds NE, Fuller GN, Kumar AJ. Intracranial metastatic melanoma: correlation between MR imaging characteristics and melanin content. *AJR Am J Roentgenol* 1995;165(6):1503–1512
- 3 Greco Crasto S, Soffietti R, Bradac GB, Boldorini R. Primitive cerebral melanoma: case report and review of the literature. *Surg Neurol* 2001;55(3):163–168; discussion 168
- 4 Liubinas SV, Maartens N, Drummond KJ. Primary melanocytic neoplasms of the central nervous system. *J Clin Neurosci* 2010;17(10):1227–1232
- 5 Bhandari L, Alapatt J, Govindan A, Sreekumar T. Primary cerebellopontine angle melanoma: a case report and review. *Turk Neurosurg* 2012;22(4):469–474
- 6 Jaiswal S, Vij M, Tungria A, Jaiswal AK, Srivastava AK, Behari S. Primary melanocytic tumors of the central nervous system: a neuroradiological and clinicopathological study of five cases and brief review of literature. *Neurol India* 2011;59(3):413–419
- 7 Gempt J, Buchmann N, Grams AE, et al. Black brain: transformation of a melanocytoma with diffuse melanocytosis into a primary cerebral melanoma. *J Neurooncol* 2011;102(2):323–328
- 8 Navas M, Pascual JM, Fraga J, et al. Intracranial intermediate-grade meningeal melanocytoma with increased cellular proliferative index: an illustrative case associated with a nevus of Ota. *J Neurooncol* 2009;95(1):105–115
- 9 Freudenstein D, Wagner A, Bornemann A, Ernemann U, Bauer T, Duffner F. Primary melanocytic lesions of the CNS: report of five cases. *Zentralbl Neurochir* 2004;65(3):146–153
- 10 Rosenthal G, Gomori JM, Tobias S, Diment J, Shoshan Y. Unusual cases involving the CNS and nasal sinuses: Case 1. Primary leptomeningeal melanoma. *J Clin Oncol* 2003;21(20):3875–3877
- 11 Pirini MG, Mascalchi M, Salvi F, et al. Primary diffuse meningeal melanomatosis: radiologic-pathologic correlation. *AJNR Am J Neuroradiol* 2003;24(1):115–118
- 12 Whinney D, Kitchen N, Revesz T, Brookes G. Primary malignant melanoma of the cerebellopontine angle. *Otol Neurotol* 2001;22(2):218–222
- 13 Amarti A, Bernoussi Z, Aghzadi A, Khamlichi A, Saidi A. Intracranial malignant melanoma. Report of 4 cases [in French]. *Arch Anat Cytol Pathol* 1998;46(3):188–192
- 14 Fish LA, Friedman DI, Sadun AA. Progressive cranial polyneuropathy caused by primary central nervous system melanoma. *J Clin Neuroophthalmol* 1990;10(1):41–44
- 15 Braga FM, Tella Júnior OI, Ferreira A, Jordy CF. Malignant melanoma of the cerebello-pontine angle region. *Arq Neuropsiquiatr* 1989;47(4):496–500
- 16 Golubčić I, Sobić V, Vlajić M, Barjaktarević Z. Intracranial malignant melanoma in childhood [in Serbian]. *Srp Arh Celok Lek* 1989;117(11–12):855–862
- 17 Brat DJ, Giannini C, Scheithauer BW, Burger PC. Primary melanocytic neoplasms of the central nervous systems. *Am J Surg Pathol* 1999;23(7):745–754
- 18 Salame K, Merimsky O, Yosipov J, Reider-Groswasser I, Chaitchik S, Ouaknine GE. Primary intramedullary spinal melanoma: diagnostic and treatment problems. *J Neurooncol* 1998;36(1):79–83
- 19 Painter TJ, Chaljub G, Sethi R, Singh H, Gelman B. Intracranial and intraspinal meningeal melanocytosis. *AJNR Am J Neuroradiol* 2000;21(7):1349–1353
- 20 Czarnecki EJ, Silbergleit R, Gutierrez JA. MR of spinal meningeal melanocytoma. *AJNR Am J Neuroradiol* 1997;18(1):180–182
- 21 Kashiwagi N, Hirabuki N, Morino H, Taki T, Yoshida W, Nakamura H. Primary solitary intracranial melanoma in the sylvian fissure: MR demonstration. *Eur Radiol* 2002;12(Suppl 3):S7–S10

Copyright of Journal of Neurological Surgery. Part A. Central European Neurosurgery is the property of Georg Thieme Verlag Stuttgart and its content may not be copied or emailed to multiple sites or posted to a listserv without the copyright holder's express written permission. However, users may print, download, or email articles for individual use.