

# Ventricular Diastolic Dimension over Maximal Myocardial Thickness is Robust Landmark of Systolic Impairment in Patients with Hypertrophic Cardiomyopathy

---

**Boban, Marko; Peša, Vladimir; Kauzlarić-Antić, Helena; Brusich, Sandro; Rotim, Ante; Madžar, Tomislav; Žulj, Marko; Včev, Aleksandar**

*Source / Izvornik:* **Medical Science Monitor, 2018, 24, 1880 - 1886**

**Journal article, Published version**

**Rad u časopisu, Objavljena verzija rada (izdavačev PDF)**

<https://doi.org/10.12659/MSM.906111>

*Permanent link / Trajna poveznica:* <https://um.nsk.hr/um:nbn:hr:239:980426>

*Rights / Prava:* [Attribution-NonCommercial-NoDerivatives 4.0 International/Imenovanje-Nekomercijalno-Bez prerada 4.0 međunarodna](#)

*Download date / Datum preuzimanja:* **2024-11-06**



*Repository / Repozitorij:*

[Repository UHC Osijek - Repository University Hospital Centre Osijek](#)

Received: 2017.07.08  
Accepted: 2017.08.30  
Published: 2018.03.31

# Ventricular Diastolic Dimension over Maximal Myocardial Thickness is Robust Landmark of Systolic Impairment in Patients with Hypertrophic Cardiomyopathy

Authors' Contribution:  
Study Design A  
Data Collection B  
Statistical Analysis C  
Data Interpretation D  
Manuscript Preparation E  
Literature Search F  
Funds Collection G

**ABDE 1,2** **Marko Boban**  
**B 1** **Vladimir Pesa**  
**D 1** **Helena Antic Kauzlaric**  
**E 3** **Sandro Brusich**  
**B 1** **Ante Rotim**  
**EF 2** **Tomislav Madzar**  
**BC 2** **Marinko Zulj**  
**EF 2** **Aleksandar Vcev**

1 Department of Cardiology, University Hospital "Thalassotherapia Opatija", Medical Faculty University of Rijeka, Rijeka, Croatia  
2 Department of Internal Medicine, Medical Faculty "J.J. Strossmayer" University of Osijek, Osijek, Croatia  
3 Department of Cardiology, University Hospital Centre Rijeka, Medical Faculty University of Rijeka, Rijeka, Croatia

**Corresponding Author:** Marko Boban, e-mail: [marcoboban@yahoo.com](mailto:marcoboban@yahoo.com)  
**Source of support:** Departmental sources

**Background:** The effects of focal hypertrophy on geometry of the left ventricle and systolic function have not been studied in patients with hypertrophic cardiomyopathy (HCM), despite the fact that the former is the most prominent disease characteristic. The aim of our study was to analyze systolic function over ventricle geometry, generating a functional index made from left ventricle end diastolic dimension (LVEDD) divided by end diastolic thickness of the region with maximal extent of hypertrophy and interventricular septum.

**Material/Methods:** Our hospital database of cardiac magnetic resonance was screened for HCM. Geometric functional index (GFI) was calculated for LVEDD over maximal end diastolic thickness (MaxEDT) giving GFI-M, while LVEDD over interventricular septum was expressed as GFI-I. There were 55 consecutive patients with HCM.

**Results:** There were 43 males (78.2%) and 12 females (21.8%). The mean age was 52.3±16.7 years (range: 15.5–76.4 years). A significant difference of GFI was found for preserved versus impaired systolic function of the left ventricle (preserved systolic function); GFI-M 2.28±0.60 versus 3.66±0.50 ( $p<0.001$ ), and GFI-I 2.75±0.88 versus 3.81±0.87 ( $p<0.001$ ), respectively. Diagnostic value was tested using receiver operating curve (ROC) analyzes, with GFI-M area under curve (AUC)=0.959 (95% CI: 0.868–0.994); ( $p<0.001$ ) and GFI-I-AUC=0.847 (0.724–0.930); ( $p<0.001$ ). GFI-M was superior to GFI-I for appraisal of left ventricle systolic dysfunction in HCM;  $\Delta$ AUC=0.112 (0.018–0.207); ( $p=0.020$ ).

**Conclusions:** GFI is a simple tool, with high sensitivity and specificity for detecting impairment of systolic function in patients with HCM. Further studies would be necessary to investigate its clinical and prognostic impacts, as well as reproducibility with prospective validation.

**MeSH Keywords:** **Cardiomyopathy, Hypertrophic • Heart Ventricles • Magnetic Resonance Imaging, Cine**

**Full-text PDF:** <https://www.medscimonit.com/abstract/index/idArt/906111>

 2642  1  4  35



## Background

Hypertrophic cardiomyopathy (HCM) is the most common among all cardiomyopathies with prevalence of 1 per 200–500 of the general population, or 0.2–3% in imaging studies [1]. Myocardial hypertrophy commonly develops as result of mutations to the contractile proteins, causing plethora of phenotypic appearances, clinical presentations, as well as variable set of prognostic courses [2]. Histopathology reveals hypertrophy and disarray of cardiomyocytes, interstitial fibrosis and changes to the intramural coronary arterioles [3]. Cardiac magnetic resonance (CMR) brought significant advances to clinical diagnosis of HCM [4]. This is particularly important for marginal cases and differential diagnosis to physiological changes of the competitively trained athletes [5]. Hypertrophy of the wall, not caused by secondary reason as valvular stenosis or hypertension, which extends over 15 mm, or 13–15 mm in first degree siblings of people with HCM are among the most important diagnostic parameters on imaging studies [6]. Certain types of hypertrophy cause left ventricular outflow gradient, which was shown to be in correlation with clinical presentation and prognosis of patients [7]. By the virtue of tissue characterization and recognition of fibrosis using late gadolinium enhancement further advances were made in the field of risk stratification, especially about sudden cardiac death and heart failure [8,9]. Hypertrophic changes to myocardial wall are dominantly segmental, however, circumferential hypertrophy could be found as well [10]. Structural changes in HCM lead to decrease of end systolic volume (ESV) and consequential rise of ejection fraction and impaired relaxation, which frequently is out of correlation with patients' symptoms and prognosis [11,12]. Due to difficulties in volumetric assessment of systolic function with HCM, which is frequently classified as hyperdynamic and shows discrepancy regarding prognostic value, supplementary diagnostic tools that could offer reproducible insight on pump function independently on three dimensional volumetric would be worthwhile. Studies with regard to non-pharmacologic treatments of left ventricle outflow tract obstruction and their prognosis generally had focus on peak velocity flow and interventricular septal thickness, which were used both as diagnostic and prognostic parameters [13,14]. Interestingly, studies only rarely showed interest for dedicated region with most hypertrophied myocardium outside interventricular septum, although other localizations are common in HCM [15-17]. Furthermore, CMR imaging currently lacks the tools that would be able to analyze function in manner comparable with echocardiographic flow, tissue Doppler and strain characteristics [18].

Effects of ventricle geometry for functional analyzes in patients with HCM were not studied systematically. Currently, there are no cardiac magnetic resonance imaging (CMRI) studies available on connection existing between the segmental hypertrophy and myocardial functionality, considering former as the

most prominent sign of HCM. The aim of our study was to analyze availability to appraise systolic impairment over the left ventricle geometry, generating functional index made from left ventricle end diastolic dimension (LVEDD) divided by end diastolic thickness of the region with maximal extent of hypertrophy. Secondly, we tested whether the diagnostic utility of geometric ratio based on maximal myocardial thickness would be superior to geometric ratio based on interventricular septal thickness using cardiac magnetic resonance imaging.

## Material and Methods

Consecutive sample of patients with diagnosis of hypertrophic cardiomyopathy were recruited from our CMR database for 1.5 year period. Diagnosis was established in accordance with guidelines of the cardiovascular societies [19,20]. Patients with significant valvular disease, uncontrolled hypertension, heart surgery, cardiac tumors, significant pericardial effusion, and known ischemic heart disease, including ischemic types of late gadolinium enhancement, were excluded.

Imaging of patients was executed on 1.5 T Magnetom Avanto, Siemens® (Erlangen, Germany, EU), using ECG gating and breath hold after two respiratory cycles, using Body Matrix chest and spine coils. Routine protocol included setting of localizers, half-Fourier acquisition single-shot turbo spin echo (HASTE) sequences, steady state free precession (SSFP) of standardized heart 2, 4, 3, chamber planes and 6 mm stack of short axial slices (8–12 slices through ventricle). In particular cases short tau inversion recovery (STIR) or turbo spin echo (TSE) T1 and T2 sequences dark blood, and fat saturation were performed, which was indicated prior or during exam on a case based indications. Gadolinium contrast was used, in dose 0.2 mL/kg (0.1 mmol/kg). Intravenous bolus of Omniscan® (Gadodiamide) or Dotarem® (gadoterate meglumine), was followed by inversion time recovery scout, with acquisition of phase-sensitive inversion-recovery (PSIR) and STIR late gadolinium enhancement (LGE) sequences 20–30 minutes following contrast application.

Post processing studies were done on Siemens AG- NUMARIS/4, Syngo MR B17® software package (Erlangen, Germany, EU), whilst volumetric analyzes were done using Siemens AG-Syngo Console Argus®, by two CMR high throughput cardiologists (over 300–450 exams per year), one cardiologist experienced in echocardiography and radiologist. Standard reporting included clinical question from referring cardiologist, previous medical history, interpretation of studied planes, sequences, tissue sequences, volumetrics, dedicated measurements of myocardial thickness in standard and dedicated regions, visual analyzes of valvular function, late gadolinium enhancement and conclusion of exam, with final interpretation of results within standardized 17-myocardial segmentation. Maximal end

diastolic wall thickness (MaxEDT) was estimated from 6-mm stack of short axis planes and interventricular septum (IVS) end diastolic thickness was recorded in 4-chamber view. GFI was calculated for LVEDD over MaxEDT i.e., GFIM, as well as GFII of LVEDD over IVS.

Patients were included subsequently to signing of informed consent. Study was performed in accordance with the "Declaration of Helsinki and good clinical practice" principles. Approval was given by ethical board of our hospital. There were no stipends or grants, study was not financed and there were no relations with the medical industry. There were no benefits or other reimbursements for patients, as well as study personnel.

Population and studied groups were analyzed using descriptive statistic and presented as means combined with standard deviations or numbers with percentages. Data on numeric variables were tested for differences with Mann-Whitney U test or Kruskal Wallis. Analyses of group data were done with chi square. Connections of studied CMR parameters and GFI were done by Spearman Rho, as well as for GFI to systolic function in partial correlation, controlled for age. bi-nominal regression model analyzed studied CMR parameters and left ventricle ejection fraction (LVEF) impairment. Diagnostic value of GFIs and left ventricular systolic function in HCM was calculated separately and in head to head settings using receiver operating curve analyzes (ROC). A *p* value less than 0.05 was considered significant. Statistical analyses were done by experienced statistician using IBM-SPSS12® v 20 (IBM co, Chicago, IL, USA), MedCalc v. 12.2® for Windows (MedCalc Software Co., Belgium, EU) and Statistica 10® for Windows (StatSoft Inc., Tulsa, OK, USA).

## Results

### Studied sample

This study included 55 consecutive patients with hypertrophic cardiomyopathy (HCM). There were 43 male (78.2%) and 12 females (21.8%). The mean age was 52.3±16.7 years (range: 15.5–76.4 years); LVEDD in 4-chamber view 5.25±0.83 cm; IVS in 4-chamber view 1.97±0.57 cm (0.75–3.41); right ventricle in 4-chamber view, end diastole (RV) 3.54±0.62 cm; left atrium square dimension at end-systole (LA) 27.6±6.9 cm<sup>2</sup>; right atrium (RA) 24.9±5.7 cm<sup>2</sup>; end-diastolic-volume (EDV) 146.8±46.3 mL; end-systolic-volume (ESV) 60.8±47.4 mL; stroke-volume (SV) 85.7±26.0 mL and myocardial mass estimated at end-diastole 159.4±51.0 gr (84.7–334.0). Left ventricle mean systolic function was 61.1±16.9% (18.1–86.8) and 12 (21.8%) had systolic impairment i.e., LVEF <50%. Baseline differences of patients with preserved and impaired LVEF are shown in Table 1.

Maximal-end-diastolic-thickness (MaxEDT) of LV was 2.18±0.58 cm (1.50–3.60 cm). Localizations and extent of the MaxEDT were as follows: only septal 9 (16.4%); bi-localational 22 (40.0%) and affecting ≥3 regions (septum, anterior, inferior, lateral) and circumferential 24 (43.6%). When LV was analyzed in stack of short axis planes, MaxEDT was found in basal region 47 (85.5%); medial 49 (89.1%) and apical 16 (29.1%). Systolic anterior motion (SAM) of mitral valve was found in 10 (18.2%). Late gadolinium enhancement was existing in 38 (69.1%), of which 34 (61.8%) were focal midventricular, 4 (7.3%) linear midventricular and further 10 (18.2%) of patients had non-formed, diffuse light-scattered enhancements (diagnostically less specific, due to technical characteristics of inversion recovery annulation process) [21].

### Geometry functional index (GFI)

Geometry functional index (GFI) was expressed as LVEDD/MaxEDT(GFI-M) or LVEDD/IVS(GFI-I), Figure 1. GFIM was 2.58±0.81 (0.99–4.68) and GFI-I 2.98±0.97 (0.96–5.73). Significant difference of GFI was found for preserved versus impaired systolic function of left ventricle (preserved systolic function); GFI-M 2.28±0.60 versus 3.66±0.50 (*p* < 0.001), and GFI-I 2.75±0.88 versus 3.81±0.87 (*p* < 0.001), respectively; data are shown in Figures 2 and 3. Spearman's rank correlation of GFIM was found for LVEF (Rho-correlation coefficient [CC]=−0.575; *p* < 0.001) and group of systolic impairment (Rho-CC=0.657; *p* < 0.001); as well as of the GFI for LVEF (Rho-CC=−0.472; *p* < 0.001) and group of systolic impairment (Rho-CC=0.496; *p* < 0.001). Although GFIs did not show significant Rho-correlations with age of patients (both *p* > 0.05), partial correlations controlled for age were significant; GFI-M to systolic impairment (CC=0.706; *p* < 0.001) and GFI-I to systolic impairment (CC=0.443; *p* = 0.001). Diagnostic value of GFIs was tested using ROC-analyzes as follows; impairment of systolic function was detected by GFI-M > 2.98 with sensitivity of 100 (95% CI: 73.5–100.0), specificity 86.1 (72.1–94.7), positive likelihood ratio (+LR) of 7.2 and negative (−LR) of 0; area under curve (AUC) ROC=0.959 (0.868–0.994); (*p* < 0.001). On the other hand, impairment of systolic function was detected with GFI-I > 3.26 with sensitivity of 83.3 (51.6–97.9); specificity 76.7 (61.4–88.2); +LR 3.58; −LR 0.22; AUC=0.847 (0.724–0.930); (*p* < 0.001), Figure 4. In same manner, difference of ROC-AUCs was significantly in favor of GFI-M superiority over GFI-I; ΔAUC=0.112 (0.018–0.207); *p* = 0.020. There also was high grade of correlation between GFI-M and GFI-I (Rho-CC=0.768; *p* < 0.001).

GFIs (GFI-M and GFI-I) did not correlate significantly with age of patients (*p* = 0.060; *p* = 0.168, respectively); LA (*p* = 0.923; *p* = 801, respectively); RA (*p* = 0.219; *p* = 113, respectively); LGE (*p* = 0.517; *p* = 102, respectively); localizations of hypertrophy (*p* = 0.767; *p* = 920, respectively); systolic anterior motion of mitral valve (*p* = 0.217; *p* = 979, respectively) and LV-myocardial mass (*p* = 0.363; *p* = 347, respectively).

**Table 1.** Principal characteristics and differences of patients based on preservation of systolic function.

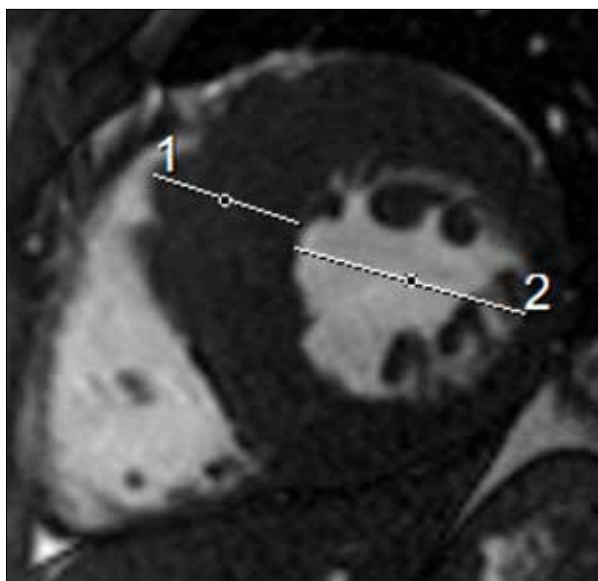
	Preserved LVEF (n=43)		Impaired LVEF (n=12)		Chi-square
	n (%)		n (%)		
Male	33	(76.7%)	10	(83.3%)	0.625
Female	10	(23.3%)	2	(16.7%)	
SAM	6	(14.0%)	0	(0.0%)	
Existence of LGE	28	(65.1%)	10	(83.3%)	
Localizations of hypertrophy*	n (%)		n (%)		Kruskal-Wallis
Interventricular septum	4	(9.3%)	5	(41.7%)	
Three regions or circumferential	24	(55.8%)	0	(0.0%)	
Bi-localational	15	(34.9%)	7	(58.3%)	
	Preserved LVEF (n=43)		Impaired LVEF (n=12)		Mann-Whitney
	Mean ±SD		Mean ±SD		
Age (years)	51.3±17.5		55.7±13.5		0.488
LVEDD (cm)	5.03±0.66		6.07±0.89		<b>0.001</b>
IVS (cm)	1.99±0.61		1.63±0.24		0.068
RV (cm)	3.54±0.62		3.54±0.65		0.992
LA (cm <sup>2</sup> )	26.8±6.8		30.3±6.8		0.119
RA (cm <sup>2</sup> )	24.2±5.4		27.2±6.1		0.328
MaxEDT (cm)	2.33±0.57		1.66±0.16		<b>&lt;0.001</b>
EDV (mL)	133.4±33.6		194.7±54.9		<b>&lt;0.001</b>
ESV (mL)	41.6±18.9		129.5±56.2		<b>&lt;0.001</b>
SV (mL)	91.4±25.0		65.1±18.5		<b>0.001</b>
MM (gram)	157.0±54.2		168.1±37.8		0.285

LVEF – left ventricular ejection fraction; LVEDD (cm) – left ventricle end diastolic dimension in 4 chamber view; IVS (cm) interventricular septum thickness in 4 chamber view; RV (cm) – right ventricle end diastolic dimension in 4 chamber view; LA & RA (cm<sup>2</sup>) – left and right atrial area in square centimeters in 4 chamber view; MaxEDT – maximal hypertrophied region end diastolic thickness; EDV (mL) – end diastolic volume; ESV (mL) – end systolic volume; SV (mL) – stroke volume; MM (gram) – myocardial mass in end-diastole; \* localizations: interventricular septum, anterior, inferior, lateral. Significant values outlined in bolded text.

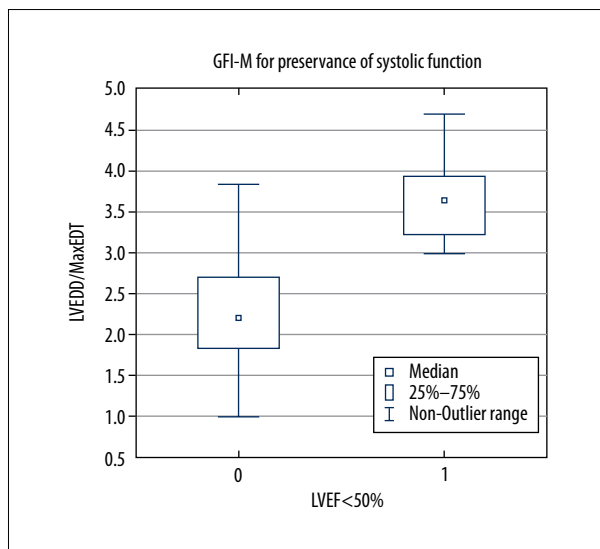
## Discussion

Our study analyzed two novel geometric parameters in connection with systolic function of the left ventricle in patients with hypertrophic cardiomyopathy (HCM). Ratio of LVEDD and myocardial thickness at region with maximal hypertrophy or interventricular septum thickness made the geometric functional index (GFI). It was shown that GFI is connected with systolic function of the left ventricle on several levels. There was significant difference of GFI in patients with impaired systolic function and controls. Furthermore, difference was further proven with intermediate to high grade of correlations. Interestingly, although there was no correlation of GFI with age of patients, adding age as control in partial correlations

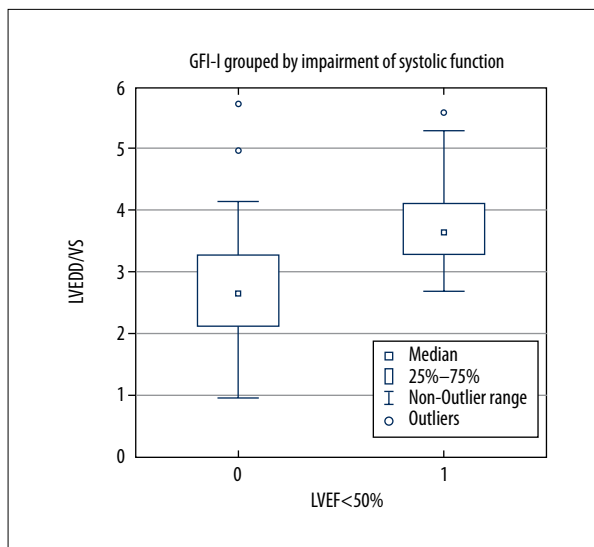
of GFI and systolic function has yielded additional synergistic power. This could be explained with effects of age on the hypertrophied heart, and potential loss of contractile function, which might not be represented best through volumetric appraisal of systolic function [22]. The latter is exceedingly challenging point, since ESV is commonly decreased in HCM and makes false overshoot, which does not correlate with prognosis of patients and loses one of the important supplementary values of ejection fraction [23]. On the other hand, impairment of the systolic function in hypertrophic cardiomyopathy below cutoff point set at 50% was previously shown to have important impact on the adverse prognosis of patients in terms of major adverse events rates [24]. This critical value of systolic function was also setoff point excellently recognized using



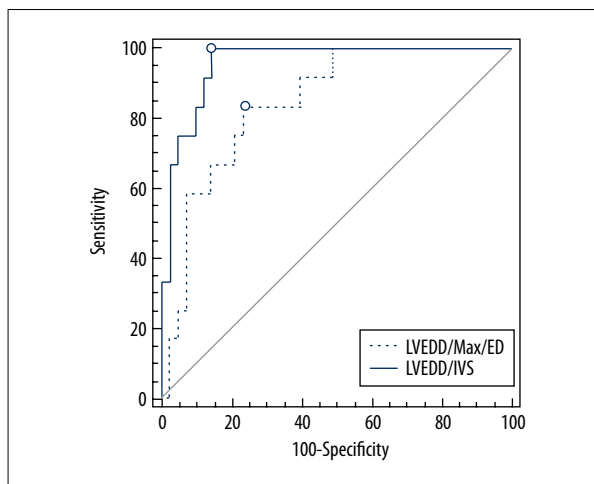
**Figure 1.** Illustration of geometrical functional index (GFI). Cine steady free precession at end diastole, short axis plane: 27.7-year-old male patient with hypertrophic cardiomyopathy, preserved systolic function: 1) maximal end diastolic myocardial thickness of 3.38 cm; 2) left ventricle end diastolic dimension of 5.26 cm, giving geometric functional index over maximal end diastolic thickness (GFI-M) of 1.56.



**Figure 2.** Geometric functional index (GFI) for maximal end diastolic ventricular thickness. Box plot of GFI-M in regard to preservation of systolic function. Data labels: GFI-M-geometry functional index for maximal myocardial end diastolic thickness (MaxEDT); LVEDD – left ventricle end diastolic dimension; LVEF – left ventricle ejection fraction.



**Figure 3.** Geometric functional index (GFI) for maximal interventricular septal thickness. Box plot of GFI-I regarding the preservation of systolic function. Data labels: GFI-I-geometry functional index for interventricular septum end diastolic thickness (IVS); LVEDD – left ventricle end diastolic dimension; LVEF – left ventricle ejection fraction.



**Figure 4.** Comparison of receiver operating curves (ROC) analyzes for studied geometric indexes.  $\circ$ -value with highest Youden index. Geometric functional indexes (GFIs): 1) GFI-M = Left ventricle end diastolic dimension (LVEDD)/MaxED (maximal end diastolic thickness), showed as blue line and 2) GFI-I = left ventricle end diastolic dimension (LVEDD)/interventricular septal thickness (IVS), presented as dashed blue line.

our novel geometry function index of dedicated region with most pronounced hypertrophy, revealing its further clinical potential. Patients with HCM and preserved ejection fraction experience dyspnea, physiological activities limitation, angina-like chest pain, and experience inconspicuous risk of sudden cardiac death, which is diagnostically difficult to characterize using cardiovascular imaging [25]. The latter is among the most important reasons on necessity of novel studies that would yield innovative diagnostic parameters, with sufficient reproducibility and convenience of use in wide number of centers [26,27]. In the context of given arguments our preliminary findings are in part inspiring since tests for diagnostic potential of GFI reported on very high sensitivity and specificity of left ventricle diastolic dimension over maximal thickness of hypertrophied myocardium for recognizing systolic dysfunction [28]. Region with most pronounced hypertrophy was superior diagnostic parameter than interventricular septal thickness in ROC analyzes, which could easily be explained by the fact that septal region in some share of patients is not the region of most pronounced functional changes of cardiomyocytes, outlining segmental characteristics of HCM to be essential parameter that affects clinical course and prognosis, in addition to its elucidative value as diagnostic parameter [10,29]. Further potential of maximal myocardial thickness GFI on therapeutic indications or follow-up of interventional treatments would have to be examined in prospective controlled settings [13,14]. Confirming of superiority for GFI that included maximal hypertrophy thickness over interventricular septal dimension in statistical tests has indirectly underscored clinical value of our hypothesis on having diagnostic potential and showing different power of correlations, which depended on the contribution of wall thickness to the LVEDD [30]. Since LVEDD is known to change in relation with function of the left ventricle, alternations of GFI in case of LV-dilatation would extreme cases cause downslope, with potential to go towards pseudo-normalization of functional index [31]. However, extent of change when severe systolic dysfunction develops hardly ever goes beyond 1–2 cm, which is relatively minor contribution, whilst hypertrophied myocardium due to stable basic characteristics (difficulties in potential to significantly change size over time), hence, has relatively smaller potential to significantly deviate index. The latter was also presented in general lack of overlapping values, whilst more powerful changes in solid manner correlated with changes of systolic function. Lack of connections existing between GFIs and late gadolinium enhancement lays in the fact that deposition of gadolinium in patients with HCM has little or none effects on myocardial wall thickness, as well as symptoms of heart failure [32,33]. Furthermore, patients with and without late enhancements could have similar systolic function, although greater volume of fibrosis is underprivileged for clinical prognosis and rate of major adverse cardiac events [34].

Further improvements on recognizing diffuse fibrosis and its clinical impact might be solved using novel CMR technologies for tissue mapping, which were also only partially identified in our study by late contrast sequences, however, burdened with technical inability to quantify those [21]. These as well might be points of potential for supplementary value of the GFI, since it was shown to act independently of conventional left ventricle volumetrics, where the latter has effects on causing falsely hyperdynamic function and consequential loss of prognostic value [35].

Important disadvantages of our study are contained by retrospective settings and lacking of ability to add further parameters in to modeling. Due to necessity to have relatively short time constant relations in order to appraise actual systolic function our study is further limited by lack of follow-up, especially one which would include clinical parameters like NYHA grade, quality of life, and prevalence rate of major adverse cardiovascular events. It is not withstanding to point out relative limitation of population number. However, initial power tests pointed that even a two-fold smaller population than we used would be sufficient to test applicability of GFIs for estimation of systolic dysfunction. Results of our study could be considered as preliminary, due to necessity to include prospective validation with inclusion different groups of controls and standardization in multicentric settings, with greater number of population, in order to gain greater reproducibility.

## Conclusions

Our study tested diagnostic utility of an index made from LVEDD over myocardial thickness in dedicated region with most pronounced hypertrophy or interventricular septal thickness. We found significant discriminative difference based on preservation of systolic function, which were confirmed by high grade of correlations and satisfactory levels of sensitivity and specificity in patients with hypertrophic cardiomyopathy. GFI of maximal hypertrophy was superior to one that included interventricular septum, pointing out that segmental disease characteristics as its prominent diagnostic parameter also have functional implications. Further studies would be necessary in order to gain reproducibility and correlations with clinical endpoints.

## Acknowledgements

Authors would thank Viktor Persic for technical assistance with MR exams.

## Conflict of interest

None.

## References:

- Morita H, Larson MG, Barr SC et al: Single-gene mutations and increased left ventricular wall thickness in the community: The Framingham Heart Study. *Circulation*, 2006; 113: 2697-705
- Wigle ED, Rakowski H, Kimball BP, Williams WG: Hypertrophic cardiomyopathy. Clinical spectrum and treatment. *Circulation*, 1995; 92: 1680-92
- Mundhenke M, Schwartzkopff B, Strauer BE: Structural analysis of arteriolar and myocardial remodelling in the subendocardial region of patients with hypertensive heart disease and hypertrophic cardiomyopathy. *Virchows Archiv*, 1997; 431: 265-73
- Marchesini M, Ugucioni L, Parisi R et al: The role of cardiac magnetic resonance imaging in hypertrophic cardiomyopathy. *Rev Cardiovasc Med*, 2016; 17: 57-64
- Wasfy MM, Weiner RB: Differentiating the athlete's heart from hypertrophic cardiomyopathy. *Curr Opin Cardiol*, 2015; 30: 500-5
- American College of Cardiology Foundation/American Heart Association Task Force on P, American Association for Thoracic S, American Society of E, et al: 2011 ACCF/AHA guideline for the diagnosis and treatment of hypertrophic cardiomyopathy: a report of the American College of Cardiology Foundation/American Heart Association Task Force on Practice Guidelines. *J Thorac Cardiovasc Surg*, 2011; 142: e153-203
- Hoey ET, Elassaly M, Ganeshan A et al: The role of magnetic resonance imaging in hypertrophic cardiomyopathy. *Quant Imaging Med Surg*, 2014; 4: 397-406
- Reichek N: Imaging cardiac morphology in hypertrophic cardiomyopathy: Recent advances. *Curr Opin Cardiol*, 2015; 30: 461-67
- Briasoulis A, Mallikethi-Reddy S, Palla M et al: Myocardial fibrosis on cardiac magnetic resonance and cardiac outcomes in hypertrophic cardiomyopathy: A meta-analysis. *Heart*, 2015; 101: 1406-11
- Maron MS, Maron BJ, Harrigan C et al: Hypertrophic cardiomyopathy phenotype revisited after 50 years with cardiovascular magnetic resonance. *Am Coll Cardiol*, 2009; 54: 220-28
- Reant P, Captur G, Mirabel M et al: Abnormal septal convexity into the left ventricle occurs in subclinical hypertrophic cardiomyopathy. *J Cardiovasc Magn Reson*, 2015; 17: 64
- Urbano Moral JA, Arias Godinez JA, Maron MS et al: Left ventricular twist mechanics in hypertrophic cardiomyopathy assessed by three-dimensional speckle tracking echocardiography. *Am J Cardiol*, 2011; 108: 1788-95
- Jensen MK, Jacobsson L, Almaas V et al: Influence of septal thickness on the clinical outcome after alcohol septal ablation in hypertrophic cardiomyopathy. *Circ Cardiovasc Interv*, 2016; 9(6): pii: e003214
- Nagueh SF, Groves BM, Schwartz L et al: Alcohol septal ablation for the treatment of hypertrophic obstructive cardiomyopathy. A multicenter North American registry. *J Am Coll Cardiol*, 2011; 58: 2322-28
- Seggewiss H, Rigopoulos A, Welge D et al: Long-term follow-up after percutaneous septal ablation in hypertrophic obstructive cardiomyopathy. *Clin Res Cardiol*, 2007; 96: 856-63
- Veselka J, Jensen MK, Liebrechts M et al: Long-term clinical outcome after alcohol septal ablation for obstructive hypertrophic cardiomyopathy: Results from the Euro-ASA registry. *Eur Heart J*, 2016; 37: 1517-23
- Liebrechts M, Vriesendorp PA, Mahmoodi BK et al: A systematic review and meta-analysis of long-term outcomes after septal reduction therapy in patients with hypertrophic cardiomyopathy. *JACC Heart Fail*, 2015; 3: 896-905
- Abozguia K, Nallur-Shivu G, Phan TT et al: Left ventricular strain and untwist in hypertrophic cardiomyopathy: relation to exercise capacity. *Am Heart J*, 2010; 159: 825-32
- Gersh BJ, Maron BJ, Bonow RO et al: 2011 ACCF/AHA guideline for the diagnosis and treatment of hypertrophic cardiomyopathy: A report of the American College of Cardiology Foundation/American Heart Association Task Force on Practice Guidelines. *Circulation*, 2011; 124: e783-831
- Authors/Task Force members, Elliott PM, Anastakis A, Borger MA et al: 2014 ESC Guidelines on diagnosis and management of hypertrophic cardiomyopathy: the Task Force for the Diagnosis and Management of Hypertrophic Cardiomyopathy of the European Society of Cardiology (ESC). *Eur Heart J*, 2014; 35: 2733-79
- Everett RJ, Stirrat CG, Semple SI et al: Assessment of myocardial fibrosis with T1 mapping MRI. *Clin Radiol*, 2016; 71: 768-78
- Voilliot D, Huttin O, Hammache N et al: Impact of global and segmental hypertrophy on two-dimensional strain derived from three-dimensional echocardiography in hypertrophic cardiomyopathy: Comparison with healthy subjects. *J Am Soc Echocardiogr*, 2015; 28: 1093-102
- Ong KC, Geske JB, Hebl VB et al: Pulmonary hypertension is associated with worse survival in hypertrophic cardiomyopathy. *Eur Heart J Cardiovasc Imaging*, 2016; 17: 604-10
- Biagini E, Pazzi C, Olivetto I et al: Usefulness of electrocardiographic patterns at presentation to predict long-term risk of cardiac death in patients with hypertrophic cardiomyopathy. *Am J Cardiol*, 2016; 118: 432-39
- Rowin EJ, Maron BJ, Kiernan MS et al: Advanced heart failure with preserved systolic function in nonobstructive hypertrophic cardiomyopathy: Under-recognized subset of candidates for heart transplant. *Circ Heart Fail*, 2014; 7: 967-75
- Olivetto I, Hellawell JL, Farzaneh-Far R et al: Novel approach targeting the complex pathophysiology of hypertrophic cardiomyopathy: The impact of late sodium current inhibition on exercise capacity in subjects with symptomatic hypertrophic cardiomyopathy (LIBERTY-HCM) Trial. *Circ Heart Fail*, 2016; 9: e002764
- Hiremath P, Lawler PR, Ho JE et al: Ultrasonic assessment of myocardial microstructure in hypertrophic cardiomyopathy sarcomere mutation carriers with and without left ventricular hypertrophy. *Circ Heart Fail*, 2016; 9(9): pii: e003026
- Doumas A, Draper TS Jr, Schick EC, Gaasch WH: Prevalence and clinical characteristics of nondilated cardiomyopathy and the effect of atrial fibrillation. *Am J Cardiol*, 2010; 105: 884-87
- Parato VM, Antoncicchi V, Sozzi F et al: Echocardiographic diagnosis of the different phenotypes of hypertrophic cardiomyopathy. *Cardiovasc Ultrasound*, 2016; 14: 30
- Frielingdorf J, Franke A, Kuhl HP et al: Evaluation of regional systolic function in hypertrophic cardiomyopathy and hypertensive heart disease: a three-dimensional echocardiographic study. *J Am Soc Echocardiogr*, 1998; 11: 778-86
- Zhang S, Yang ZG, Sun JY et al: Assessing right ventricular function in patients with hypertrophic cardiomyopathy with cardiac MRI: Correlation with the New York Heart Function Assessment (NYHA) classification. *PLoS One*, 2014; 9: e104312
- Spinner JA, Noel CV, Denfield SW et al: Association of late gadolinium enhancement and degree of left ventricular hypertrophy assessed on cardiac magnetic resonance imaging with ventricular tachycardia in children with hypertrophic cardiomyopathy. *Am J Cardiol*, 2016; 117: 1342-48
- Maron MS, Appelbaum E, Harrigan CJ et al: Clinical profile and significance of delayed enhancement in hypertrophic cardiomyopathy. *Circ Heart Fail*, 2008; 1: 184-91
- Appelbaum E, Maron BJ, Adabag S et al: Intermediate-signal-intensity late gadolinium enhancement predicts ventricular tachyarrhythmias in patients with hypertrophic cardiomyopathy. *Circ Cardiovasc Imaging*, 2012; 5: 78-85
- An S, Fan C, Yan L et al: Comparison of long-term outcome between apical and asymmetric septal hypertrophic cardiomyopathy. *Cardiology*, 2016; 136: 108-14