

Primary Central Nervous System Anaplastic Large T-cell Lymphoma

Splavski, Bruno; Mužević, Dario; Ladenhauser-Palijan, Tatjana; Splavski Jr, Brano

Source / Izvornik: **Medical Archives, 2016, 70, 311 - 313**

Journal article, Published version

Rad u časopisu, Objavljena verzija rada (izdavačev PDF)

<https://doi.org/10.5455/medarh.2016.70.311-313>

Permanent link / Trajna poveznica: <https://urn.nsk.hr/urn:nbn:hr:239:881803>

Rights / Prava: [Attribution-NonCommercial 4.0 International/Imenovanje-Nekomercijalno 4.0 međunarodna](#)

Download date / Datum preuzimanja: **2024-07-13**



Repository / Repozitorij:

[Repository UHC Osijek - Repository University Hospital Centre Osijek](#)

CASE REPORT

doi: 10.5455/medarh.2016.70.311-313

Med Arch. 2016 Aug; 70(4): 311-313

Received: JUN 05, 2016 | Accepted: JUL 15, 2016

© 2016 Bruno Splavski, Dario Muzevic, Tatjana Ladenhauser-Palijan, and Brano Splavski Jr

This is an Open Access article distributed under the terms of the Creative Commons Attribution Non-Commercial License (<http://creativecommons.org/licenses/by-nc/4.0/>) which permits unrestricted non-commercial use, distribution, and reproduction in any medium, provided the original work is properly cited.

Primary Central Nervous System Anaplastic Large T-cell Lymphoma

Bruno Splavski¹, Dario Muzevic¹, Tatjana Ladenhauser-Palijan², and Brano Splavski Jr³

¹Department of Neurosurgery, "J. J. Strossmayer" University of Osijek School of Medicine, Osijek, Croatia

²Division of Hematology, Department of Internal Medicine, "J. J. Strossmayer" University of Osijek School of Medicine, Osijek, Croatia

³Division of Ophthalmology, Osijek Clinical Hospital Center, Osijek, Croatia

Corresponding author: Prof. Bruno Splavski, MD, PhD, Department of Neurosurgery, Osijek University School of Medicine, Clinical Hospital Center, Osijek, Croatia. Phone: +385 31 511380. E-mail: splavuno@gmail.com

ABSTRACT

Introduction: Primary central nervous system lymphoma (PCNSL) of T-cell origin is an exceptionally rare, highly malignant intracranial neoplasm. Although such a tumor typically presents with a focal mass lesion. **Case report:** Past medical history of a 26-year-old male patient with a PCNS lymphoma of T-cell origin was not suggestive of intracranial pathology or any disorder of other organs and organic systems. To achieve a gross total tumor resection, surgery was performed via osteoplastic craniotomy using the left frontal transcortical transventricular approach. Histological and immunohistochemical analyses of the tissue removed described tumor as anaplastic large cell lymphoma of T-cells (T-ALCL). Postoperative and neurological recovery was complete, while control imaging of the brain showed no signs of residual tumor at a six-month follow-up. The patient, who did not appear immunocompromised, was referred to a hematologist and an oncologist where corticosteroids, the particular chemotherapeutic protocol and irradiation therapy were applied. **Conclusion:** Since PCNS lymphoma is a potentially curable brain tumor, we believe that proper selection of the management options, including early radical tumor resection for solitary PCNS lymphoma, may be proposed as a major treatment of such a tumor in selected patients, resulting in a satisfactory outcome.

Key words: Primary central nervous system lymphoma of T-cell origin; Radical Surgery; Protocol Options; Outcome.

1. INTRODUCTION

Primary central nervous system lymphoma (PCNSL) of T-cell origin is an exceptionally rare, highly malignant cerebral tumor affecting every fraction of the neural axis (1).

The incidence of PCNSL is 1:100,000, which accounts for 3-6% of all primary brain tumors (2, 3). The B-cell lymphomas are much more frequent than T-cell lymphomas, both in systemic and CNS presentation (2-4). Out of all cases of PCNSL reported, only 2% are T-cell lymphomas (4, 5), hence its overall incidence is roughly 1:5,000,000.

Such a tumor characteristically appears with a focal mass lesion. The majority among immunocompetent patients may have neuropsychiatric signs and increased intracranial

pressure (ICP), while seizures and ocular symptoms are less frequent (6).

Since there are no distinctive clinical or radiographic findings for T-cell PCNSL, tumor tissue biopsy remains the gold standard in diagnostics. The ordinary treatment options include corticosteroids, chemotherapy and irradiation.

Although primary CNS lymphoma is a potentially curable brain tumor, the prognosis of T-cell PCNSL still remains uncertain (3, 7-9).

Hereby, we present a case report of the T-cell origin PCNSL patient together with the literature review.

2. CASE REPORT

A 26-year-old male presented after mild head injury sustained in a

sport activity. Past medical history was not suggestive of intracranial pathology. No neurological deficit was recorded at the hospital admission, except short term diplopia and left ptosis.

Brain computed tomography (CT) and magnetic resonance imaging (MRI) demonstrated solitary, contrast-enhancing, lobular, partially cystic intraventricular tumor up to 35 mm in diameter, located in the frontal horn of the left lateral ventricle, with abundant perifocal edema and subependymal intraaxial spread (Figures 1, 2).

Gross tumor total resection was achieved via osteoplastic craniotomy, using the left frontal transcortical transventricular approach.

Histological tissue analysis described tumor as densely cellular, consisting of polymorphous cells with hyperchromatic nuclei and sporadic mitoses. However, the characteristic pattern of angiocentric tumor growth usually found in lymphomas was absent.

Immunohistochemical stains were performed on paraffin-embedded tissue using antibodies to cytokeratin AE1/AE3, cytokeratin MNF116, vimentin, CD45LCA, TTF-1, EMA, PLAP, HMB45, GFAP, keratin 7, keratin 20, CD20, CD10, CD3, CD4, CD30, CD99, CD8, CD20, ALK, bcl2, bcl6, MUM-1, NSE, Tdt, and Ki-67. Tumor cells reacted positively to vimentin, CD45LCA, EMA, CD3, CD4, CD30, CD99, and MUM-1.

Histological and immunohistochemical tissue samples described tumor as anaplastic large cell lymphoma of T-cells (T-ALCL). Prognostically important anaplastic lymphoma kinase (ALK) was positive, and Ki-67 proliferation index was 75%.

Postoperative neurological recovery was complete, while brain MRI regular check-ups showed no signs of residual tumor. Following surgery, the patient was referred to a hematologist and an ophthalmologist. The lymph nodes palpation and testicular inspection did not reveal any signs of dissemination. No intraocular spread of the disease was found as well. Enhanced CT scans of the chest, abdomen and pelvis, and ultrasonography of peripheral lymph nodes showed no extracranial signs of the disease. Bone marrow biopsy was negative, while serum lactate dehydrogenase levels were normal. Serology performed for the presence of the human immunodeficiency virus (HIV), cytomegalovirus (CMV), Epstein-Barr virus (EBV), hepatitis B and C (HBV, HCV) viruses was negative. Prednisone 0.25 mg/kg was administered in an early postoperative period. Chemotherapy was applied during a 12-week period in four cycles by the following protocol: high-dose methotrexate (MTX, 3.5 g/msq) delivered intravenously on day 1, high-dose cytarabine (1 g/msq) on days 2 and 3. Methotrexate serum levels were monitored at 12, 24, 36 and 48 hours after its administration, and folinic acid (Leucovorin) was administered when necessary. Granulocyte colony stimulating factor (GCSF) was applied from day 7 until white blood cell count improved.

Additionally, fractionated low-dose whole-brain irradiation (36 Gy separated in 18 fractions of 2 Gy each) was given during a 24-day period.

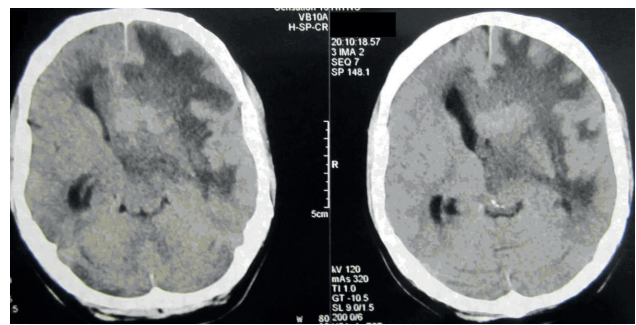


Figure 1. Preoperative CT brain scan revealing intraventricular tumor mass with abundant perifocal edema.

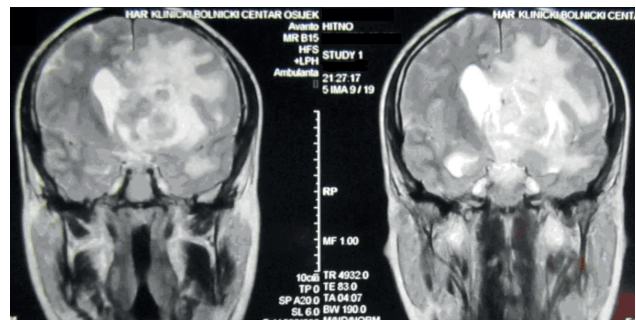


Figure 2. Preoperative brain MRI (T2-weighted image, coronal reconstruction) demonstrating solitary, lobular, partially cystic intraventricular tumor.

The patient was regularly followed-up every 6 months. At a 2-year follow-up he was doing well with no radiological and clinical signs of the tumor recurrence.

3. DISCUSSION

The majority of PCNSL are of B-cell origin, while T-cell PCNSL represents below 5% of cases (8, 10-12).

The prognosis of T-cell PCNSL has been controversial without a consensus in the literature. Several reports point out poor outcome in comparison to other CNS lymphomas, while some indicate better overall survival (9, 13, 14).

The diagnosis of PCNSL is most commonly achieved via stereotactic brain biopsy. Current imaging techniques of the brain fail to reliably differentiate primary or secondary CNSL, metastases and inflammatory processes. A cerebrospinal fluid (CSF) test can only imply evidence of PCNSL in the existence of leptomeningeal dissemination (15). Elevated lactate dehydrogenase and CSF protein levels have been reported as potentially poor prognostic indicators too (3). However, no CSF tests were performed in our patient preoperatively due to the abundant cerebral edema implying increased ICP.

Physical assessment should consist of the enlarged lymph nodes palpation, and testicular inspection and ultrasonography in males, due to testicular lymphoma tendency to propagate to the brain. Since lymphoma may not be limited to the CNS alone, looking for occult systemic disease has become even more essential (1).

While MTX monotherapy is the most successful and commonly administered medication associated with better survival (16), the individual treatment regimens remain diverse. The majority of patients are likely to necessitate combined-modality protocols to reach a

long-lasting effect. In due course, chemotherapy has revealed the most excellent effect comparing to other therapeutic modalities (17). The combined method of corticosteroid therapy and irradiation have been also reported to accomplish comprehensive reaction (7), while the combination of chemotherapy and irradiation was used in uncommon cases of primary peripheral nervous system lymphoma with CNS metastasis (18). Whole-brain irradiation alone is associated with a radiographic response in majority of patients with recurrent or intractable PCNSL but it generates delayed neurotoxic effects, particularly in older patients. The median after irradiation survival is up to 16 months, with younger patients faring better (1).

Since it is unclear whether additional combined-modality protocols can improve survival and diminish postponed neurotoxic effects (19), it seems feasible to perform irradiation in younger patients, in those harboring residual or recurring tumor, and/or whose response to chemotherapy was inadequate. For these reasons our patient has received corticosteroids, combined chemotherapy, and irradiation as well.

The disease has been demanding to study due to the scarcity of PCNSL cases and lack of an efficient standard management protocol. Although durable remissions may be achieved, the tumor is prone to recur in most cases. However, our patient has not shown any signs of the tumor recurrence at a 2-year follow-up.

The obtainable treatment preferences for PCNSL consist of corticosteroids, chemotherapy and irradiation, while radical surgical resection seems scarcely possible and not practical, apart from patients sustaining a brain herniation due to mass effect (1). Hence, median survival subsequent to surgery alone is usually short. Accordingly, it appears that once the diagnosis is accomplished by a stereotactic biopsy, additional surgical treatment may not be helpful. However, the best possible management protocol has not been defined yet. Reviewing the literature, it is obvious that detailed understanding of this disease is limited. Current diagnostic imaging techniques of the brain are insufficient in differentiating PCNSL from other neoplastic or inflammatory processes, and histology remains sine qua non for establishing the diagnosis. Tumor specimens are usually obtained by stereotactic brain biopsy. However, tumor localization and patient preoperative condition permitting, it seems feasible to perform radical surgical resection. Surgery delivers sufficient material for histological and immunohistochemical analysis, avoids complications and false negative results inherent to stereotactic brain biopsy and promptly reduces tumor mass effect and perilesional edema which may significantly influence the outcome. Remembering this, we suggest that proper selection of the management alternatives including radical surgery may be proposed as a treatment option for solitary T-cell PCNSL in selected patients, resulting in a satisfactory outcome. Obviously, further studies on a larger material are needed to support this statement.

4. CONCLUSION

The scarcity of T-cell origin PCNSL has restricted particular understanding of the disease. Its appropriate assessment requires evaluation of the brain, eyes, CSF, spinal cord, and whole body. There is still no therapeutic agreement concerning the best possible management approach for PCNSL patients.

Having all that in mind, and considering our patient's history, we believe that early radical resection is a treatment option for solitary primary CNS T-cell lymphoma bringing a satisfactory outcome.

- Author's contribution: All co-authors were included in substantial contribution to conception and design and final approval of the version to be published.
- Conflict of interest: The authors report no conflict of interest regarding this paper.

REFERENCES

1. Gerstner ER, Batchelor TT. Primary Central Nervous System Lymphoma. *Arch Neurol.* 2010; 67(3): 291-7.
2. Choi JS, Nam DH, Ko YH, et al. Primary central nervous system lymphoma in Korea: comparison of B- and T-cell lymphomas. *Am J Surg Pathol.* 2003; 27: 919-28.
3. Shenker TN, Blay JY, O'Neill BP, et al. Primary CNS lymphoma of T-cell origin: a descriptive analysis from the international primary CNS lymphoma collaborative group. *J Clin Oncol.* 2005; 23(10): 2233-2339.
4. Harder A, Dudel C, Anagnostopoulos I, et al. Molecular genetic diagnosis of a primary central nervous system T cell lymphoma. *Acta Neuropathol.* 2003; 105: 65-8.
5. Dulai MS, Park CY, Howell WD, et al. CNS T-cell lymphoma: an under-recognized entity? *Acta Neuropathol.* 2008; 115: 345-56.
6. Bataille B, Delwail V, Menet E, et al. Primary intracerebral malignant lymphoma: report of 248 cases. *J Neurosurg.* 2000; 92(2): 261-6.
7. Latta S, Myint ZW, Jallad B. Primary central nervous system T-cell lymphoma in AIDS patients: case report and literature review. *Curr Oncol.* 2010; 17(5): 63-6.
8. Gijtenbeek JM, Rosenblum MK, DeAngelis LM. Primary central nervous system T-cell lymphoma. *Neurology.* 2001; 57: 716-8.
9. Mineura K, Sawataishi J, Sasajima T, et al. Primary central nervous system involvement of the so called "peripheral T-cell lymphoma": report of a case and review of the literature. *J Neurooncol.* 1993; 16: 235-42.
10. Pfreundschuh M, Trumper L, Kloess M, et al. Two-weekly or 3-weekly CHOrchemotherapy with or without etoposide for the treatment of elderly patients with aggressive lymphomas: results of the NHL-B2 trial of the DSHNHL. *Blood.* 2004; 104(3): 634-41.
11. Escalon MP, Liu NS, Yang Y, et al. Prognostic factors and treatment of patients with T-cell non-Hodgkin lymphoma. *Cancer.* 2005; 103(10): 2091-8.
12. Levin N, Soffer D, Grissaru S, et al. Primary T-cell CNS lymphoma presenting with leptomeningeal spread and neurolymphomatosis. *J Neurooncol.* 2008; 90: 77-83.
13. Soussain C, Hoang-Xuan K. Primary central nervous system lymphoma: an update. *Curr Opin Oncol.* 2009; 6: 550-8.
14. Ponce J, Segura A, Gimenez A, et al. Primary meningeal lymphoma of T-cell origin: a rare presentation of primary central nervous system lymphomas. *Clin Lymphoma Myeloma.* 2007; 7(8): 546-9.
15. Chamberlain MC. Neoplastic meningitis: a guide to diagnosis and treatment. *Curr Opin Neurol.* 2000; 13(6): 641-8.
16. Behbahani M, Lyons MK. Primary central nervous system T-cell lymphoma of the brain. *Open Neurosurg J.* 2011; 4: 62-5.
17. Pulsoni A, Gubitosi G, Rocchi L, et al. Primary T-cell lymphoma of central nervous system (PTCLCNS): a case with unusual presentation and review of the literature. *Ann Oncol.* 1999; 10(12): 1519-23.
18. Goldbrunner R, Warmuth-Metz M, Tonn JC, et al. Primary Ki-1- positive T-cell lymphoma of the brain—an aggressive subtype of lymphoma: case report and review of the literature. *Surg Neurol.* 1996; 46:37-41.
19. Gerstner ER, Carson KA, Grossman SA, Batchelor TT. Long-term outcome in PCNSL patients treated with high-dose methotrexate and deferred radiation. *Neurology.* 2008; 70: 401-2.