

Extremely Well-differentiated Gastric Adenocarcinoma Arising in Pylorus with Minor Diffuse Adenocarcinoma Component

Jukić, Zoran; Bacalja, Jasna; Kristek, Jozo; Bekavac-Bešlin, Miroslav; Krušlin, Božo

Source / Izvornik: **Journal of Gastrointestinal Cancer, 2018, 49, 75 - 77**

Journal article, Published version

Rad u časopisu, Objavljena verzija rada (izdavačev PDF)

<https://doi.org/10.1007/s12029-016-9851-3>

Permanent link / Trajna poveznica: <https://um.nsk.hr/um:nbn:hr:239:912871>

Rights / Prava: [Attribution 4.0 International](#)/[Imenovanje 4.0 međunarodna](#)

Download date / Datum preuzimanja: **2024-07-13**



Repository / Repozitorij:

[Repository UHC Osijek - Repository University Hospital Centre Osijek](#)

CASE REPORT

Extremely Well-Differentiated Gastric Adenocarcinoma Arising in Pylorus with Minor Diffuse Adenocarcinoma Component

Zoran Jukić¹ · Jasna Bacalja² · Jozo Kristek³ · Miroslav Bekavac-Bešlin⁴ · Božo Krušlin^{5,6}

Published online: 5 July 2016
© Springer Science+Business Media New York 2016

Purpose

Gastric adenocarcinoma is generally a disease of the middle-aged and elderly with a peak incidence in patients over 65 years. The highest rates in the world are reported in

A part of the article was presented as poster presentation named Extremely well-differentiated gastric adenocarcinoma in a 40-year-old patient by authors Z. Jukić, Z. Marušić, J. Kristek and M. Bekavac-Bešlin at a scientific meeting, 1st IASGO (International Association of Surgeons, Gastroenterologists and Oncologists) Croatia Course, the Red Island, Rovinj, Croatia, April 26th–28th 2013.

✉ Jasna Bacalja
jasnabacalja@yahoo.com

Zoran Jukić
zoran_jukic@yahoo.com

Jozo Kristek
kristek.jozo@kbo.hr

Miroslav Bekavac-Bešlin
miroslav.bekavac@kbcsm.hr

Božo Krušlin
bozo.kruslin@kbcsm.hr

- ¹ Department of Surgery, General Hospital Nova Gradiška, Nova Gradiška, Croatia
- ² Clinical Department of Pathology and Cytology, University Hospital Dubrava, Zagreb, Croatia
- ³ Department of Surgery, Clinical Hospital Center Osijek, Osijek, Croatia
- ⁴ Department of Surgery, Sestre Milosrdnice Clinical Hospital Center, Zagreb, Croatia
- ⁵ School of Medicine, University of Zagreb, Zagreb, Croatia
- ⁶ Ljudevit Jurak Department of Pathology, Sestre Milosrdnice Clinical Hospital Center, Zagreb, Croatia

Eastern Asia [1]. Based on Lauren classification, gastric adenocarcinomas have been classified into two types, intestinal and diffuse types [2].

A subset of gastric adenocarcinomas has been described under the name of “extremely well-differentiated gastric adenocarcinoma” (EWDGA) [3]. It is defined as a neoplastic lesion composed of highly differentiated neoplastic epithelium which mimics the normal gastric mucosa or intestinal metaplastic mucosa with mild nuclear atypia. It is considered a low-grade carcinoma [4] accounting for around 0.1 % of all gastric tumours [4, 5]. We report a case of EWDGA that differs from previously described cases in order that there was a presence of a minor intramucosal diffuse adenocarcinoma component, which has not been reported up to date in patients with EWDGA.

Methods and Results

A 40-year-old male suffered from the episodes of heartburn, nausea with vomiting, lack of appetite and weight loss of 2-month duration. He smoked 20 cigarettes a day. Tumour family history was negative. The patient had gastroscopy which revealed severe pyloric stenosis. During the gastroscopy, mucosal biopsy from the pylorus was taken. Histologically, there were irregular glands with epithelium that showed signs of high-grade dysplasia and incomplete intestinal metaplasia. Due to the pathohistological finding of high-grade epithelial dysplasia and severe pyloric stenosis, the lesion was suspected to be carcinoma. The patient underwent operation. Intraoperatively, the stenosing lesion of the pylorus was found and partial gastrectomy was performed (Billroth II). Gross examination of the biopsy specimen revealed partially ulcerated pyloric tumour measuring 2.5 cm in the largest diameter (Fig. 1.).

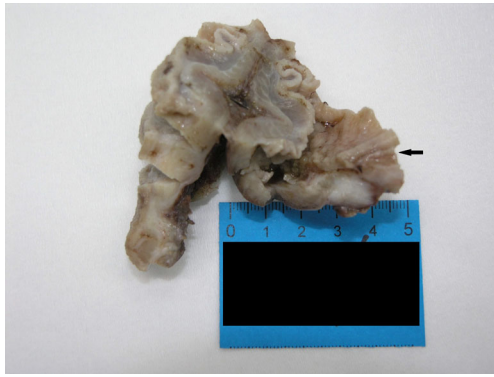


Fig. 1 Gross examination of the biopsy specimen reveals partially ulcerated tumour (*arrow*)

Microscopically, the tumour was composed of a minor component (constituting around 5 % of the tumour burden) of diffuse adenocarcinoma limited to the mucosa, highlighted by immunohistochemical stain (CKAE1/AE3) (Fig. 2.) and numerous tumour glands that mimicked well-differentiated foveolar epithelium scattered throughout all layers of the wall (Figs. 3 and 4.). The latter part of the tumour exhibited foci of perineural invasion. One of the resected lymph nodes showed infiltration by the tumour glands. Immunohistochemical staining for p53 was negative. The tumour was signed out as pT2N1, stage IB. Ki-67 proliferation index was 24 %. *Helicobacter pylori* was not found (histochemically highlighted with Giemsa stain).

In further course of the treatment, the patient underwent adjuvant chemotherapy with 5 cycles of 5-fluorouracil (5-FU)/leucovorin, plus concomitant radiotherapy of 45 Gy in 25 fractions.

The patient had anastomotic recurrence of EWDGA 3 years after the surgery. Palliative surgery was performed (biliodigestive anastomosis). During the operation, conglomerate of the lymph nodes in hepatoduodenal ligament was removed and sent for the pathohistological examination. Metastasis of EWDGA was found. The patient was considered for involvement in the international phase III study for HER2-

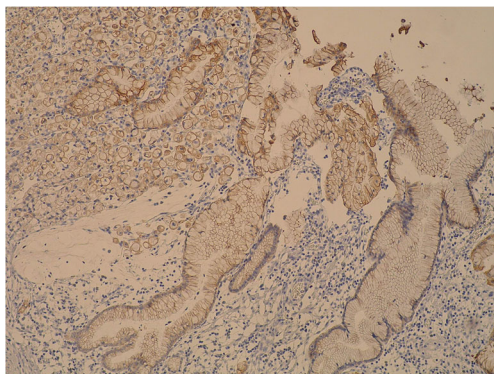


Fig. 2 Diffuse adenocarcinoma component (*upper left*) limited to the mucosa (immunohistochemical staining cytokeratin AE1/AE3, magnification $\times 100$)

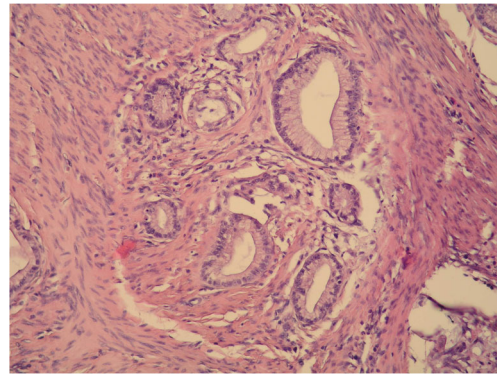


Fig. 3 Tumour glands are scattered throughout the muscular layer of the gastric wall (hematoxylin and eosin, magnification $\times 400$)

positive metastatic gastric or gastro-esophageal junction cancer (JACOB) [6], so immunohistochemical staining for HER2 was performed on the primary tumour and it was negative. The patient received 3 cycles of chemotherapy (5-FU/cisplatin). The following CT showed decrease in size of the tumour in the place of anastomosis (from 11- to 5-mm diameter), but the tumour invaded the surrounding fat tissue, truncus coeliacus, hepatic and lineal arteries and part of the portal vein. Also, dilatation of intrahepatal biliary ducts was found. There were no distant metastases. After the fifth cycle of chemotherapy (5-FU/cisplatin), there was a deterioration of the patient's health and he died 4 years after the gastric cancer was diagnosed. The autopsy was not performed.

Discussion

EWDGA is a rare entity which has been described in several case reports and two case studies (all from Japan). The described tumours measured 1 to 6 cm in the largest diameter [3–5, 7–9].

Yao et al. classified EWDGA in two categories, one having gastric phenotype and the other having intestinal phenotype. The authors described the gastric phenotype of EWDGA as the one “resembling gastric foveolar epithelium, mucous neck cells or pyloric glands, with mild or no nuclear atypia and

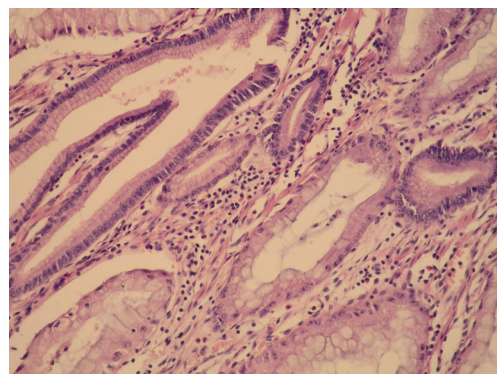


Fig. 4 The tumour glands mimic well-differentiated foveolar epithelium (hematoxylin and eosin, $\times 400$)

architectural distortion of the glands”. Intestinal type tumours (further divided into complete and incomplete intestinal phenotype) “resemble intestinal metaplasia with minimal nuclear atypia and irregular glands” [4]. Most reported cases of EWDGA were of intestinal type [3, 4].

EWDGA usually appeared in the upper or middle third of the stomach [4, 5, 7] [8, 9], and in our case, the tumour arose in the lower third of the stomach.

Previous reports [4, 5, 8, 9] indicate that EWDGA represents a subset of gastric adenocarcinoma with a more favorable outcome compared to conventional gastric adenocarcinoma. As was stated by Yao et al., the favorable biological behavior is supported immunohistochemically by low activity of cell proliferation marker Ki-67 (the mean value being 8.7 %, range 0.5–23.9 %) and a lack of tumour suppressor gene p53 and HER-2 overexpression [4]. Rarely, lymphovascular invasion and lymph node metastasis have been noted [4]. Even when they were present (as in our case), the patient’s outcome was better compared to other gastric adenocarcinomas presenting in the same stage [4, 5]. Our patient did not present with distant metastases, but he died of complications of locally invasive tumour.

Until now, the only case of EWDGA associated with the death of a patient was described by Terada. In his case, the patient had carcinomatosis of unknown origin. Multiple tumours in the liver and tumour-like lesion in the colon were found, but the biopsies were not taken from these sights because of the weakness of the patient. Gastroscopy was performed, and ulcerated lesion of the gastric corpus was found. The biopsy was taken, and EWDGA was diagnosed. The patient died of carcinomatosis 3 months after the admission. Autopsy was not performed [7]. Because the autopsy was not performed, the existence of the secondary tumour (other than EWDGA) that might have caused carcinomatosis cannot be confidentially excluded. The gastroscopic biopsy sample has its limitation because of its size, which is well demonstrated in our case, as the component of diffuse adenocarcinoma was not initially found in the gastroscopic biopsy sample.

Currently, there are no separate guidelines for the treatment of EWDGA so this tumour is treated as its gastric adenocarcinoma counterparts, according to the stage of the disease [6].

In our case, the patient presented with stage IB disease so according to the guidelines provided by the European Society for Medical Oncology (ESMO), the European Society of Surgical Oncology (ESSO) and the European Society of Radiotherapy and Oncology (ESTRO), for patients who undergo surgery for \geq stage IB gastric cancer without administration of preoperative chemotherapy, the treatment option was adjuvant chemoradiotherapy that he received.

Considering there was no metastatic spread of the disease in our case nor in the previous reports of this tumour [2–5, 8, 9],

we agree that this tumour is a low-grade malignancy and this should be emphasized in the pathological report. Although this tumour is considered to have favorable prognosis and it usually does not present with lymph node involvement, in our case, the metastases in the lymph node of hepatoduodenal ligament and its spread to the surrounding tissue lead to deterioration of the patient’s state and eventually to his death.

There, we conclude that although EWDGAs have lower metastatic potential compared to their gastric adenocarcinoma counterparts, the stage of the disease remains the main prognostic factor for these tumours and they should be treated accordingly.

Compliance with Ethical Standards

Conflict of Interest The authors declare that they have no conflict of interest.

References

1. Ferlay J SH, Bray F, Forman D, Mathers C, Parkin DM (2010) Cancer incidence and mortality worldwide: IARC CancerBase No.10
2. Lauren P. The two histological main types of gastric carcinoma: diffuse and so-called intestinal-type carcinoma. An attempt at a histo-clinical classification. *Acta pathologica et microbiologica Scandinavica*. 1965;64:31–49.
3. Endoh Y, Tamura G, Motoyama T, Ajioka Y, Watanabe H. Well-differentiated adenocarcinoma mimicking complete-type intestinal metaplasia in the stomach. *Hum Pathol*. 1999;30(7):826–32.
4. Yao T, Utsunomiya T, Oya M, Nishiyama K, Tsuneyoshi M. Extremely well-differentiated adenocarcinoma of the stomach: clinicopathological and immunohistochemical features. *World J Gastroenterol: WJG*. 2006;12(16):2510–6.
5. Yamamoto J, Ohshima K, Kohno S, Ichimiya H, Nakagaki M, Yao T, Iwasaki H, Ikeda S. Extremely well differentiated adenocarcinoma of the stomach diagnosed preoperatively as esophageal achalasia: report of a case. *Surg Today*. 2005;35(6):488–92. doi:10.1007/s00595-004-2944-9.
6. Hoff P, Tabernero J, Shen L, Ohtsu A, Yu R, Szado T, Kang Y-K (2013) P-01111 Pertuzumab, trastuzumab and chemotherapy in HER2-positive metastatic gastric or gastro-oesophageal junction cancer: an international phase III study (JACOB). *Annals of Oncology* 24 (suppl 4):iv67. doi: 10.1093/annonc/mdt203.109
7. Terada T. Well differentiated adenocarcinoma of the stomach composed of chief cell-like cells and parietal cells (gastric adenocarcinoma of fundic gland type). *Int J Clin Exp Pathol*. 2011;4(8):797–8.
8. Ueyama H, Yao T, Nakashima Y, Hirakawa K, Oshiro Y, Hirahashi M, Iwashita A, Watanabe S. Gastric adenocarcinoma of fundic gland type (chief cell predominant type): proposal for a new entity of gastric adenocarcinoma. *Am J Surg Pathol*. 2010;34(5):609–19. doi:10.1097/PAS.0b013e3181d94d53.
9. Tsukamoto T, Yokoi T, Maruta S, Kitamura M, Yamamoto T, Ban H, Tatematsu M. Gastric adenocarcinoma with chief cell differentiation. *Pathol Int*. 2007;57(8):517–22. doi:10.1111/j.1440-1827.2007.02134.x.