

A Novel PGAP3 Mutation in a Croatian boy with Brachytelephalangy and a Thin Corpus Callosum

Sakaguchi, Tomohiro; Žigman, Tamara; Petković Ramadža, Danijela; Omerza, Lana; Pušeljić, Silvija; Ereš Hrvaćanin, Zrinka; Miyake, Noriko; Matsumoto, Naomichi; Barić, Ivo

Source / Izvornik: **Human Genome Variation, 2018, 5, 1 - 4**

Journal article, Published version

Rad u časopisu, Objavljena verzija rada (izdavačev PDF)

<https://doi.org/10.1038/hgv.2018.5>

Permanent link / Trajna poveznica: <https://urn.nsk.hr/urn:nbn:hr:239:345932>

Rights / Prava: [Attribution-NonCommercial-NoDerivatives 4.0 International/Imenovanje-Nekomercijalno-Bez prerada 4.0 međunarodna](#)

Download date / Datum preuzimanja: **2023-12-01**



Repository / Repozitorij:

[Repository UHC Osijek - Repository University Hospital Centre Osijek](#)

DATA REPORT

A novel *PGAP3* mutation in a Croatian boy with brachytelephalangy and a thin corpus callosumTomohiro Sakaguchi^{1,7}, Tamara Žigman^{2,7}, Danijela Petković Ramadža^{2,3}, Lana Omerza^{2,3}, Silvija Pušeljić^{4,5}, Zrinka Ereš Hrvacánin⁶, Noriko Miyake¹, Naomichi Matsumoto¹ and Ivo Barić^{2,3}

Biallelic mutations in the post-GPI attachment to proteins 3 (*PGAP3*) gene cause hyperphosphatasia with mental retardation syndrome 4 (HPMRS4), which is characterized by elevated serum alkaline phosphatase, severe psychomotor developmental delay, seizures, and facial dysmorphism. To date, 15 *PGAP3* mutations have been reported in humans. Here we report a novel homozygous *PGAP3* mutation (c.314C>A, p.Pro105Gln) in a Croatian patient and fully describe the clinical features.

Human Genome Variation (2018) 5, 18005; doi:10.1038/hgv.2018.5; published online 8 March 2018

Hyperphosphatasia with mental retardation syndrome (HPMRS), also known as Mabry syndrome, is an autosomal recessive disease that is associated with inherited glycosylphosphatidylinositol (GPI) deficiencies (IGDs).¹ There are two types of genes involved in IGDs: phosphatidylinositol glycan (PIG) genes and post-GPI attachment to proteins (PGAP) genes. PIG genes are involved in the biosynthesis and transfer of GPI, while PGAP genes play a role in the remodeling, sorting, and transport of GPI-anchored proteins (GPI-APs).¹ To date, at least six genes responsible for HPMRS have been reported: *PIGO* (MIM 614730),² *PIGV* (MIM 610274),³ *PIGW* (MIM 610275),⁴ *PIGY* (MIM 610662),⁵ *PGAP2* (MIM 615187),⁶ and *PGAP3* (MIM 611801, NM_033419.4).⁷ HPMRS is registered in the Online Mendelian Inheritance in Man (OMIM) database as a phenotypic series (HPMRS1-6, OMIM PS239300), and *PGAP3* is the gene responsible for HPMRS4 (MIM 615716). Although there are a variety of clinical features of HPMRS, the major features include intellectual disability, hyperphosphatasia, seizures, and facial dysmorphism, as well as anomalies, such as brachytelephalangy.^{1,8}

We encountered a patient with HPMRS. He was born to healthy and nonconsanguineous parents (from the same region) after an uneventful pregnancy with no asphyxia at birth (Apgar score was 10/10) (Figure 1a). He has no siblings, and his family history is unremarkable. His birth length, weight, and head circumference were 51 cm (+0.59 SD), 3,360 g (+0.03 SD), and 35.5 cm (+0.82 SD), respectively. Multiple congenital anomalies, including a broad nasal bridge, tented upper lip vermilion, cleft palate, low set ears, micrognathia, retrognathia, brachytelephalangy, left sided cryptorchidism, wide feet, and broad toes, were noticed at birth. Palatoplasty was performed at 1 year of age, and left orchiopexy was performed at 4 years of age. Progressive thoracic scoliosis started at 5 years of age and was treated with orthotics at 6 years with no improvements. At 2.5 months, he started intensive physical therapy for his marked generalized hypotonia that has been continued until now. He was unable to sit up by himself until 4 years of age. He first experienced recurrent generalized

seizures with dysrhythmic electroencephalographic paroxysmal changes at 3 years of age, and these seizures were well controlled with phenobarbital. The seizures started again at 5 years of age and were controlled with valproate. When HPMRS was suspected at 6.5 years of age, he started treatment with 200 mg of pyridoxine daily and has been free of seizures since. Sleep disturbance (awake at night and sleeping during the daytime) started at 3 years of age, a condition that was normalized with pyridoxine. Pyridoxine was administered since it has been reported to be effective for neuronal symptoms in hyperphosphatasia with neuronal deficits.⁹ A brain magnetic resonance imaging at 5 years of age showed a thin corpus callosum without any other gross abnormalities (Figure 2).

Currently, at the age of 8 years, he shows severe psychomotor developmental delay, autistic behavior, and bruxism. Eye contact is possible for short periods of time, but he has a short attention span. He can sit alone, crawl clumsily, and occasionally stand with support, but he cannot walk independently or speak any meaningful words. He often smiles and vocalizes with simple words. He cannot understand simple commands, but he can understand daily tasks, such as going for a walk or eating meals. He partially participates in dressing himself. He is unable to use cutlery and eats with his fingers. His vision and hearing are normal, but he cannot control egestion. His serum alkaline phosphatase (ALP) has been elevated (in the range from 500–1200 U/L) since the age of 1 year when it was first measured, and his ALP level was 578 U/L at the age of 7.5 years (reference range: 172–405 U/L). His serum 25-OH-vitamin-D3, calcium, and phosphorus levels have been in the normal range.

To identify the genetic cause of his condition, we performed whole-exome sequencing (WES) on the proband as reported previously.¹⁰ DNA was extracted from peripheral blood leukocytes after obtaining written informed consent. This study protocol was approved by the institutional review board of Yokohama City University School of Medicine. Using WES, 96.8% of the coding region of RefSeq genes was covered by 10 reads. We checked for

¹Department of Human Genetics, Yokohama City University Graduate School of Medicine, Kanazawa-ku, Yokohama, Japan; ²Department of Pediatrics, University Hospital Centre Zagreb, Zagreb, Croatia; ³School of Medicine, University of Zagreb, Zagreb, Croatia; ⁴Department of Pediatrics, University Hospital Centre Osijek, Osijek, Croatia; ⁵School of Medicine, Osijek University, Osijek, Croatia and ⁶Department of Pediatrics, General Hospital "Dr. Josip Benčević", Slavonski Brod, Croatia.

Correspondence: N Matsumoto (naomat@yokohama-cu.ac.jp)

⁷These authors contributed equally to this work.

Received 6 November 2017; revised 19 December 2017; accepted 9 January 2018

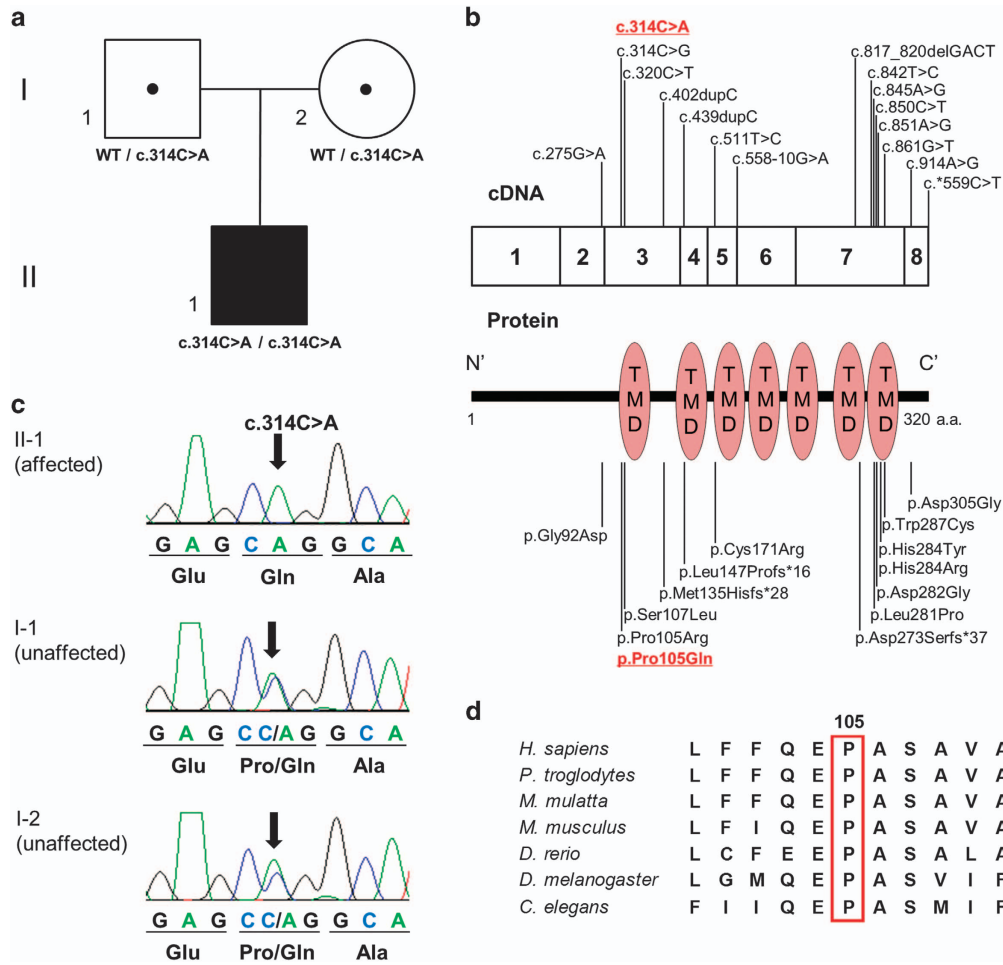


Figure 1. Genetic analysis of the patient. **(a)** Familial pedigree and the *PGAP3* mutation. **(b)** Human *PGAP3* cDNA and the *PGAP3* protein structure with previously reported mutations and a newly identified mutation (underlined and in red). *PGAP3* consists of eight exons, and the *PGAP3* protein contains seven transmembrane domains (TMD). The description of the mutation was based on NM_033419.4. **(c)** Electropherograms of the patient (II-1) and his parents (I-1 and I-2). **(d)** Evolutionary conservation of p.Pro105 in *PGAP3*. Protein sequences of different species were aligned using CLUSTALW (<http://www.genome.jp/tools/clustalw/>).

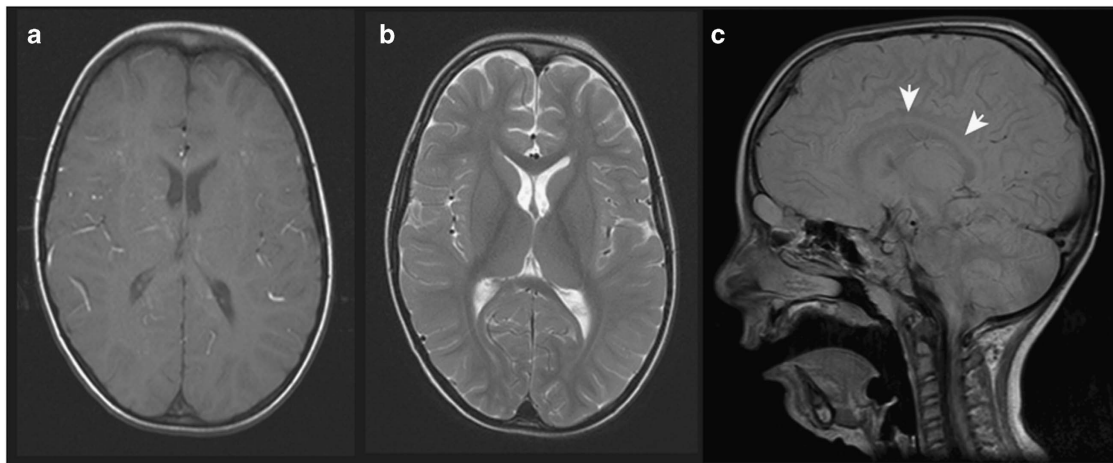


Figure 2. Brain magnetic resonance imaging of the proband at the age of 5 years. T1- **(a)** and T2-weighted **(b)** axial images and a proton density-weighted sagittal image **(c)** are shown. A thin corpus callosum was observed (white arrows).

variants in the known disease genes responsible for HPMRS and found a homozygous missense variant (NM_033419.4, c.314C>A, p.Pro105Gln) in *PGAP3*. This mutation was predicted as pathogenic by the *in silico* software: SIFT=0, PolyPhen2=1, and MutationTaster=disease causing. This variant was not registered in the Exome Aggregation Consortium (ExAC: <http://exac.broad-institute.org/>), NHLBI GO Exome Sequencing Project 6500 (ESP6500: <http://evs.gs.washington.edu/EVS/>), Human Genetic Variation Database (HGVD: <http://www.hgvd.genome.med.kyoto-u.ac.jp/>), or our in-house exome database ($n=575$). Of note, this missense mutation was located at an identical position to a previously reported pathogenic mutation but led to a different base alteration to a different amino acid (c.314C>G, p.Pro105Arg) (Figure 1b).⁷ Sanger sequencing revealed that this new mutation was inherited from both unaffected carrier parents (Figure 1c). This amino residue is evolutionally conserved from *C. elegans* to *H. sapiens* (Figure 1d). In addition, similar to previously reported patients, the proband in this report showed facial dysmorphism, cryptorchidism, severe psychomotor developmental delay, speech impairment, hypotonia, autistic behavior, bruxism, and sleep disturbance (see also Supplementary Table S1).

To date, 15 mutations in *PGAP3* have been reported in 30 patients with HPMRS 4 (Figure 1b).^{7,8,11–15} More than half of the mutations (9/15; 60%) are in exon 3 and exon 7, and these regions are considered hotspots for mutations.^{13,14} The mutation identified in our proband is also located within this hotspot in exon 3.

The clinical features of the current patient were compared with those in previously reported patients (Supplementary Table S1). All patients, including the one in this study, showed facial dysmorphism, motor delay, speech impairment, and elevated serum ALP. Interestingly, our patient also showed brachytelephalangy, one of the characteristic features of HPMRS. However, while brachytelephalangy has never been reported in HPMRS4 caused by the *PGAP3* mutation, broad fingers and toenails have been reported in some patients with the *PGAP3* mutation.^{7,8,11–15} This finding indicates that the *PGAP3* mutation can cause brachytelephalangy, as the other types of HPMRS.

The proband in this study showed a thin corpus callosum, which is the most common type of brain abnormality among patients with the *PGAP3* mutation. Interestingly, a thin corpus callosum is observed in all patients with a missense mutation (c.314C>G, p.Pro105Arg) or truncating mutation (c.402dupC, p.Met135Hisfs*28) in a homozygous state but not in those with other mutations. Some genotype–phenotype correlation is possible, although information is limited.

Hyperphosphatasia is an important clinical feature of HPMRS. All patients showed hyperphosphatasia (28/28; 100%), and most patients with *PGAP3* mutations (22/28; 79%) had a higher serum ALP (1.1–3.6 times the upper limit) than the age-adjusted normal ranges (Supplementary Table S1). Patients with *PIGO*, *PIGW*, or *PIGY* mutations have been reported to have normal levels or mildly elevated ALP levels.^{5,13,16–18} By contrast, more than half of patients with *PIGV* or *PGAP2* mutations showed extremely high levels of ALP (over 3.6 times the normal upper limit).^{6,17,19,20} The degree of elevated serum ALP may be related to the mutated genes.

In conclusion, we report HPMRS4 in a patient with a novel missense *PGAP3* mutation. As there is a minimal number of patients with *PGAP3* mutations, further analysis of these patients is required to understand the genotype–phenotype correlation.

HGV DATABASE

The relevant data from this Data Report are hosted at the Human Genome Variation Database at <http://dx.doi.org/10.6084/m9.figshare.hgv.1755> (2018).

ACKNOWLEDGEMENTS

We thank the patient and his family for their participation in this study. This work was supported by grants from Research on Measures for Intractable Diseases; Comprehensive Research on Disability Health and Welfare; the Strategic Research Program for Brain Science (SRPBS); the Practical Research Project for Rare/Intractable Diseases; the Initiative on Rare and Undiagnosed Diseases from the Japan Agency for Medical Research and Development; a Grant-in-Aid for Scientific Research on Innovative Areas (Transcription Cycle) from the Ministry of Education, Culture, Sports, Science and Technology of Japan; Grants-in-Aid for Scientific Research (A and B); Grant-in-Aid for Young Scientists (B); Challenging Exploratory Research from the Japan Society for the Promotion of Science; the fund for Creation of Innovation Centers for Advanced Interdisciplinary Research Areas Program in the Project for Developing Innovation Systems from the Japan Science and Technology Agency; grants from the Ministry of Health, Labour and Welfare; and the Takeda Science Foundation. We thank Rhonna Gurevich, PhD, from the Edanz Group (www.edanzediting.com/ac) for editing a draft of this manuscript.

COMPETING INTERESTS

The authors declare no conflict of interest.

PUBLISHER'S NOTE

Springer Nature remains neutral with regard to jurisdictional claims in published maps and institutional affiliations.

REFERENCES

- Kinoshita T. Biosynthesis and deficiencies of glycosylphosphatidylinositol. *Proc Jpn Acad Ser B Phys Biol Sci* 2014; **90**: 130–143.
- Krawitz PM, Murakami Y, Hecht J, Kruger U, Holder SE, Mortier GR *et al*. Mutations in *PIGO*, a member of the GPI-anchor-synthesis pathway, cause hyperphosphatasia with mental retardation. *Am J Hum Genet* 2012; **91**: 146–151.
- Krawitz PM, Schweiger MR, Rodelsperger C, Marcellis C, Kolsch U, Meisel C *et al*. Identity-by-descent filtering of exome sequence data identifies *PIGV* mutations in hyperphosphatasia mental retardation syndrome. *Nat Genet* 2010; **42**: 827–829.
- Maydan G, Noyman I, Har-Zahav A, Neriah ZB, Pasmanik-Chor M, Yehekel A *et al*. Multiple congenital anomalies-hypotonia-seizures syndrome is caused by a mutation in *PIGN*. *J Med Genet* 2011; **48**: 383–389.
- Ilkovski B, Pagnamenta AT, O'Grady GL, Kinoshita T, Howard MF, Lek M *et al*. Mutations in *PIGY*: expanding the phenotype of inherited glycosylphosphatidylinositol deficiencies. *Hum Mol Genet* 2015; **24**: 6146–6159.
- Hansen L, Tawamie H, Murakami Y, Mang Y, ur Rehman S, Buchert R *et al*. Hypomorphic mutations in *PGAP2*, encoding a GPI-anchor-remodeling protein, cause autosomal-recessive intellectual disability. *Am J Hum Genet* 2013; **92**: 575–583.
- Howard MF, Murakami Y, Pagnamenta AT, Daumer-Haas C, Fischer B, Hecht J *et al*. Mutations in *PGAP3* impair GPI-anchor maturation, causing a subtype of hyperphosphatasia with mental retardation. *Am J Hum Genet* 2014; **94**: 278–287.
- Knaus A, Awaya T, Helbig I, Afawi Z, Pendziwiat M, Abu-Rachma J *et al*. Rare noncoding mutations extend the mutational spectrum in the *PGAP3* subtype of hyperphosphatasia with mental retardation syndrome. *Hum Mutat* 2016; **37**: 737–744.
- Thompson MD, Killoran A, Percy ME, Nezarati M, Cole DE, Hwang PA. Hyperphosphatasia with neurologic deficit: a pyridoxine-responsive seizure disorder? *Pediatr Neurol* 2006; **34**: 303–307.
- Iwama K, Sasaki M, Hirabayashi S, Ohba C, Iwabuchi E, Miyatake S *et al*. Milder progressive cerebellar atrophy caused by biallelic *SEPSECS* mutations. *J Hum Genet* 2016; **61**: 527–531.
- Yavarna T, Al-Dewik N, Al-Mureikhi M, Ali R, Al-Mesaifri F, Mahmoud L *et al*. High diagnostic yield of clinical exome sequencing in Middle Eastern patients with Mendelian disorders. *Hum Genet* 2015; **134**: 967–980.
- Abouelhoda M, Sobahy T, El-Kalioby M, Patel N, Shamseldin H, Monies D *et al*. Clinical genomics can facilitate countrywide estimation of autosomal recessive disease burden. *Genet Med* 2016; **18**: 1244–1249.
- Pagnamenta AT, Murakami Y, Taylor JM, Anzilotti C, Howard MF, Miller V *et al*. Analysis of exome data for 4293 trios suggests GPI-anchor biogenesis defects are a rare cause of developmental disorders. *Eur J Hum Genet* 2017; **25**: 669–679.

- 14 Abdel-Hamid MS, Issa MY, Otaify GA, Abdel-Ghafar SF, Elbendary HM, Zaki MS. *PGAP3*-related hyperphosphatasia with mental retardation syndrome: Report of 10 new patients and a homozygous founder mutation. *Clin Genet* 2017; **93**: 84–91.
- 15 Nampoothiri S, Hebbar M, Roy AG, Kochumon SP, Bielas S, Shukla A *et al*. Hyperphosphatasia with mental retardation syndrome due to a novel mutation in *PGAP3*. *J Pediatr Genet* 2017; **6**: 191–193.
- 16 Hoglebe M, Murakami Y, Wild M, Ahlmann M, Biskup S, Hortnagel K *et al*. A novel mutation in *PIGW* causes glycosylphosphatidylinositol deficiency without hyperphosphatasia. *Am J Med Genet A* 2016; **170**: 3319–3322.
- 17 Xue J, Li H, Zhang Y, Yang Z. Clinical and genetic analysis of two Chinese infants with Mabry syndrome. *Brain Dev* 2016; **38**: 807–818.
- 18 Zehavi Y, von Renesse A, Daniel-Spiegel E, Sapir Y, Zalman L, Chervinsky I *et al*. A homozygous *PIGO* mutation associated with severe infantile epileptic encephalopathy and corpus callosum hypoplasia, but normal alkaline phosphatase levels. *Metab Brain Dis* 2017; **32**: 2131–2137.
- 19 Krawitz PM, Murakami Y, Riess A, Hietala M, Kruger U, Zhu N *et al*. *PGAP2* mutations, affecting the GPI-anchor-synthesis pathway, cause hyperphosphatasia with mental retardation syndrome. *Am J Hum Genet* 2013; **92**: 584–589.
- 20 Jezela-Stanek A, Ciara E, Piekutowska-Abramczuk D, Trubicka J, Jurkiewicz E, Rokicki D *et al*. Congenital disorder of glycosylphosphatidylinositol (GPI)-anchor biosynthesis--the phenotype of two patients with novel mutations in the *PIGN* and *PGAP2* genes. *Eur J Paediatr Neurol* 2016; **20**: 462–473.



This work is licensed under a Creative Commons Attribution-NonCommercial-NoDerivs 4.0 International License. The images or other third party material in this article are included in the article's Creative Commons license, unless indicated otherwise in the credit line; if the material is not included under the Creative Commons license, users will need to obtain permission from the license holder to reproduce the material. To view a copy of this license, visit <http://creativecommons.org/licenses/by-nc-nd/4.0/>

© The Author(s) 2018

Supplementary Information for this article can be found on the Human Genome Variation website (<http://www.nature.com/hgv>)