

Kikuchi-Fujimoto Disease: the First Reported Case in Croatia

Kotromanović, Željko; Mihalj, Hrvoje; Kotromanović, Zdenka; Rajc, Jasmina; Včeva, Andrijana; Mihalj, Martina; Zubčić, Željko; Birtić, Darija

Source / Izvornik: **Collegium antropologicum, 2013, 37, 607 - 610**

Journal article, Published version

Rad u časopisu, Objavljena verzija rada (izdavačev PDF)

Permanent link / Trajna poveznica: <https://um.nsk.hr/um:nbn:hr:239:942187>

Rights / Prava: [In copyright](#)/[Zaštićeno autorskim pravom.](#)

Download date / Datum preuzimanja: **2025-01-04**



Repository / Repozitorij:

[Repository UHC Osijek - Repository University Hospital Centre Osijek](#)

Kikuchi-Fujimoto Disease: the First Reported Case in Croatia

Željko Kotromanović¹, Hrvoje Mihalj¹, Zdenka Kotromanović², Jasmina Rajc³, Andrijana Včeva¹,
Martina Mihalj⁴, Željko Zubčić¹ and Darija Birtić¹

¹ »J. J. Strossmayer« University, Osijek University Hospital Centre, Department of Otorhinolaryngology and Head and Neck Surgery, Osijek, Croatia

² »J. J. Strossmayer« University, Osijek University Hospital Centre, Department of Oncology and Radiotherapy, Osijek, Croatia

³ »J. J. Strossmayer« University, Osijek University Hospital Centre, Department of Pathology and Forensic Medicine, Osijek, Croatia

⁴ »J. J. Strossmayer« University, School of Medicine, Department of Physiology and Immunology, Osijek, Croatia

ABSTRACT

Kikuchi-Fujimoto disease (KFD) is an extremely rare disease known to have a worldwide distribution with higher prevalence among Japanese and other Asiatic individuals. KFD presents as benign and self-limited disorder, characterized by regional cervical lymphadenopathy with tenderness, usually accompanied with mild to high fever and night sweats. Less frequent symptoms include weight loss, nausea, vomiting and sore throat. Final diagnosis can only be determined on the basis of typical morphological changes in the lymph node, therefore lymph node biopsy is crucial for proving the diagnosis. Here we present a 16-year-old, native Croatian, Caucasian girl with KFD, as a first case of KFD reported in Croatia. We suggest that this disease should be considered as a possible cause of fever of the unknown origin followed by lymphadenopathy.

Key words: lymphadenopathy, fever, histiocytic necrotizing lymphadenitis, Kikuchi-Fujimoto

Introduction

Kikuchi-Fujimoto disease (KFD) is considered as uncommon, self-limited, benign, histiocytic, necrotising, systemic lymphadenitis of unknown etiology which was first described in a young Japanese woman in 1972^{1,2}. Although KFD was initially characterized as occurring exclusively in the cervical lymph nodes of young Asian women, it has been observed in patients of any age, sex and race, and it involves both nodal and extranodal locations. However, typical KFD presents as unilateral, cervical lymphadenopathy accompanied by mild to high fever; other symptoms are less frequent. The etiology remains unknown, but several theories involve viral infection and autoimmunity³⁻⁵. This disease can be easily mistaken for systemic lupus erythematosus (SLE), malignant lymphoma or even, though rarely, for adenocarcinoma. Thus, it is very important to recognize KFD on time to prevent unnecessary diagnostic and therapeutic manipulations. As the laboratory and radiographic findings appear to be non-specific, lymph node biopsy is crucial for giving the final diagnosis. Treatment is symptomatic, including

non-steroidal anti-inflammatory drugs (NSAID) and corticosteroids. Spontaneous recovery occurs in 1 to 6 months. Patients with KFD should be followed-up for several years to exclude the possibility of the development of SLE or Sjögren's syndrome⁶. Despite its low incidence, KFD should be considered in patients with persistent lymphadenopathy.

Case Report

A 16 year old, native Croatian, Caucasian girl presented with a three weeks history of high fevers and swelling in her upper neck. The mass was causing severe pain and tenderness over the right sternocleidomastoid muscle. Her past medical history revealed only appendectomy six years earlier. Both of her parents are alive and healthy, with no history of malignancy in the family. At the time of admission at our Department, she was afebrile, with obvious right cervical lymphadenopathy.

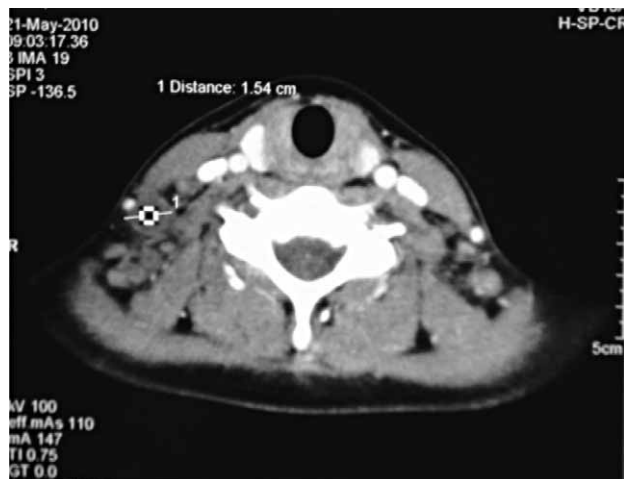

Fig. 1. Computed tomographic (CT) scan revealed a 15 mm mass in the right lower jugular node (level IV) with peripheral enhancement.

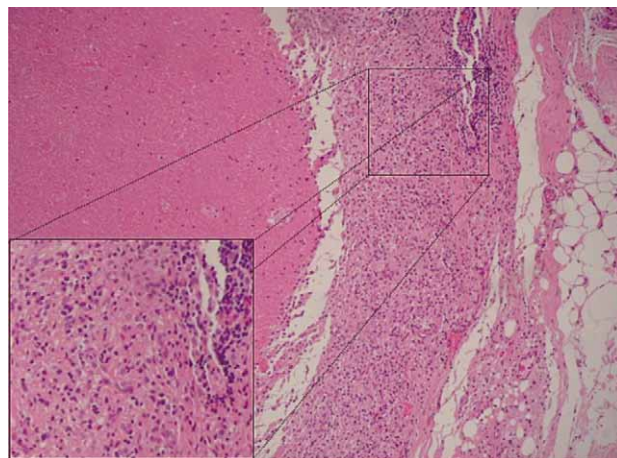


Fig. 2. Tissue section of extracted lymph node (HE, 200x) showing necrotizing change on the right side with abundant karyorrhectic debris, scattered fibrin deposits and collection of large mononuclear cells. There is a notable absence of neutrophils and eosinophils (showed in small section).

Nasal and oral examinations were unremarkable. Blood analysis at admission time presented with slight anaemia. White blood cell count was $5.0 \times 10^9/L$ (reference range $4.4\text{--}11.6 \times 10^9$) and consisted of 76% neutrophils, 10% monocytes, 13% lymphocytes, less than 1% basophils, and less than 1% eosinophils. Her haemoglobin level was 111 g/L, (reference range 118–149 g/L), and her platelet count was $272 \times 10^9/L$ (reference range $178\text{--}420 \times 10^9/L$). A computed tomographic (CT) scan revealed a 15 mm mass in the right lower jugular node (level IV) with peripheral enhancement (Figure 1). Adjacent lymph nodes along the right jugular chain were also enlarged. The patient underwent an excisional biopsy. During surgery, a solid mass was identified and removed. Histopathological analysis of extracted specimen revealed necrotizing changes with abundant karyorrhectic debris, scattered fibrin deposits and a collection of large mononuclear cells (Figure 2). No active treatment was initiated and the patient was discharged home after seven days of in-patient stay. At follow-up she reported no symptoms, remained well and there were no abnormalities found at clinical examination.

Discussion

KFD was first described in 1972 almost simultaneously by Kikuchi and Fujimoto as a case of lymphoma responding to therapy and having good prognosis^{1,2}. To date it is known as uncommon, self-limited, benign, histiocytic, necrotising lymphadenitis. It has been observed in patients aged 19 months to 75 years (typically 25–29 years old). KFD is 3 to 4 times more common in women than in men^{3,7}. Although patients can be of any race, most case reports are from Asia; hence KFD appearing elsewhere is often incorrectly diagnosed and forgotten in differential diagnosis of cervical lymphadenopathy.

Several infectious agents (Epstein-Barr virus, human herpesvirus, HIV, HTLV1, dengue virus, parvovirus B19,

Yersinia enterocolitica, *Bartonella*, *Brucella* and *Toxoplasma*) have been appointed as possible cause of KFD, but direct correlation could not be confirmed as their histopathological findings differ from those of KFD⁴. Because KFD and SLE have been found in some cases to affect the same patients, some authors have hypothesized an autoimmune background of KFD. Following, studies investigating correlation between different immunological parameters (i.e. antinuclear antibodies, rheumatoid factors) and KFD have failed to confirm this theory^{3–5, 8–10}. Recent studies have demonstrated activated CD8+ cells after viral infection in lymph nodes, which may induce apoptosis of CD4+ lymphocytes. Hypothetically, apoptotic lymphocytes could deliver nuclear antigens and trigger autoimmune T and B cells to produce antinuclear antibodies^{11,12}. Others have found that the primary mechanism of KFD necrosis involves perforin, a cytolytic protein.

Most patients (80%) present with cervical lymphadenitis, although any lymph node regions may be involved¹³. Neck involvement is usually unilateral. Cervical lymphadenopathy is common in the posterior cervical triangle and jugular carotid chain¹⁴, and the other affected areas are the axillar (14%) and supraclavicular (12%) lymph nodes. Occurring lymphadenopathy may be firm and sometimes painful. It is usually isolated, but 1% to 20% of patients have generalized lymphadenopathy¹⁵. Fever is usually high and appears as the first symptom in 30% to 50% of the cases; weight loss can be seen in 10% and shivering in 4% of KFD patients^{8,16–18}. Other less frequent symptoms include skin rash, gastrointestinal abnormalities and night sweating¹⁸. Skin lesions are non-specific and include erythematous papules, plaques, acneiform or morbilliform lesions and facial erythema, in addition to possible mucosal involvement¹⁹. Finding on skin biopsy usually gives the same picture like the one found in the affected lymph nodes^{4,8}.

Laboratory abnormalities that can occur in KFD include anemia, leukopenia or even pancytopenia, elevated erythrocyte sedimentation rate (ESR), and elevated lactate dehydrogenase (LDH). Currently there is no laboratory test specific for KFD.

Radiographic findings specific to KFD have not been established, and reports of KFD in the medical literature have largely focused on the disease pathology. Nevertheless, chest radiography should be included in the diagnostic evaluation to eliminate the possibility of malignancy or tuberculosis.

The radiographic differential diagnosis of KFD is very broad and includes Hodgkin and non-Hodgkin disease, metastatic tumor, tuberculosis, nontuberculous mycobacterial infection, SLE, human immunodeficiency virus infection, infectious mononucleosis, cat-scratch disease, mucocutaneous lymph node syndrome (Kawasaki disease) and toxoplasmosis.

In the past, fine needle aspiration (FNA) has been utilized for diagnosis, but the results are often ambiguous because the nodal architecture cannot be appreciated adequately. However, patients suspected of having KFD often undergo fine-needle aspiration before an excision biopsy is performed. Aspiration was not performed on our patient because ultrasonography indicated that the mass was solid.

Definitive diagnosis of KFD can only be made by lymph node biopsy and histological examination. There are several classic histological features of KFD (Figure 2). The affected lymph nodes have patchy necrotizing regions (the degree of necrosis varies widely among patients), mainly in the paracortical areas. They often contain well-circumscribed areas of eosinophilic fibrinoid material with a substantial degree of karyorrhexis. Transformed lymphocytes (immunoblasts) may surround the necrotic areas, creating a characteristic mottled appearance at low magnification. Nuclear debris («nuclear dust») is evenly scattered throughout the necrotic areas and is associated with atypical mononuclear cells, which may be macrophages phagocytosing the debris. Another characteristic histological observation is the absence of granulocytes and few or no plasma cells^{20,21}. Although histological lymph node features are distinct in KFD, some overlaps exist, especially with SLE. Therefore effective communication between the pathologist and oto-

rhinolaryngologist is critical for correct disease identification.

Although it usually follows a benign course, KFD has been repeatedly misdiagnosed as malignant lymphoma. Results of one survey revealed that 29% of patients with KFD were initially misdiagnosed as having Hodgkin or non-Hodgkin disease²¹; therefore, clinicians and pathologists alike need to be aware of this disease entity. There are some macroscopic features that help to differentiate KFD from lymphoma. KFD presents with an increased number of slightly enlarged lymph nodes, whereas lymphoma usually produces moderately to markedly enlarged lymph nodes. Excised lymph nodes of KFD patients are typically smaller than 3 cm.

In 80% of patients, KFD is self-limited and resolves within 1 to 6 months without specific treatment²². Patients with extensive systemic manifestations, pyrexia, lymphadenopathic pain, or a combination of these symptoms have been treated with steroidal or nonsteroidal anti-inflammatory medications, and patients with advanced KFD may benefit from treatment with systemic prednisone²³.

Conclusion

KFD is a self-limited and typically benign lymphadenitis of unknown etiology now recognized in multiple geographic regions and races. Despite the low incidence and its benignancy, it should be considered in cases of persistent lymphadenopathy to avoid unnecessary diagnostic manipulations and misdiagnosis with lymphoma or other overlapping entities. It usually resolves spontaneously over several weeks to months. Several authors have reported good responses to corticosteroid treatment for severe cases, but therapeutic measures are generally limited to patient education and symptomatic treatment with NSAIDs. Close follow up of KFD patients is indicated in order to confirm the resolution of their symptoms within the usual time course, and also to assess for signs suggesting the development of SLE. The two diseases share similar hosts and similar manifestations, and there have been reports of KFD patients going on to develop SLE²⁰. Therefore patients need to be followed closely even after all symptoms of KFD have resolved.

REFERENCES

1. KIKUCHI M, *Acta Hematol Jpn*, 35 (1972) 379. — 2. FUJIMOTO Y, KOJINIA Y, YAMAGUCHI K, *Inter Med*, 41 (1972) 323. — 3. LAZZARESCHI I, BARONE G, RUGGIERO A, LIOTTI L, MAURIZI P, LAROCCA LM, RICCARDI R, *Pediatr Blood Cancer*, 50 (2008) 119. DOI: 10.1002/pbc.20918. — 4. PARADELA S, LORENZO J, MARTÍNEZ-GÓMEZ W, YEBRA-PIMENTEL T, VALBUENA L, FONSECA E, *Lupus*, 17 (2008) 1127. DOI: 10.1177/0961203308092161. — 5. PARK HS, SUNG MJ, PARK SE, LIM YT, *Pediatr Allergy Immunol*, 18 (2007) 174. DOI: 10.1111/j.1399-3038.2006.00505.x. — 6. MIYASHITA Y, YAMAGUCHI M, FUJIMOTO W, *J Dermatol*, 30 (2003) 608. — 7. ONCIU M, MEDEIROS LJ, *Adv Anat Pathol*, 10 (2003) 204. — 8. ATWATER AR, LONGLEY BJ, AUGHENBAUGH WD, *J Am Acad Dermatol*, 59 (2008) 130. DOI: 10.1016/j.jaad.2008.03.012. — 9. YILMAZ M, CAMCI C, SARI I, OKAN V, SEVINC A, ONAT AM, BUYUKHATIPOGLU H, *Lupus*, 15 (2006) 384. DOI: 10.1191/0961203306lu2320cr. — 10. MONTEJO M, LEKERIKA N, ASTIGARRAGA I, AGUIRREBENGOA K, GOIKOETXEA J, ERDOZAIN JG, BIDAURRAZAGA N, *An Med Interna*, 23 (2006) 173. DOI: 10.4321/S0212-71992006000400006. — 11. ALLJOTAS-REIG J, CASELLAS-CARO M, FERRER-OLIVERAS R, CABERO-ROURA L, VILARDELL-TARRES M, *J Obstet Gynaecol Res*, 34 (2008) 595. DOI: 10.1111/j.1447-0756.2008.00727.x. — 12. BOSCH X, GUILABERT A, *Orphanet J Rare Dis*, 1 (2006) 18. DOI: 10.1186/1750-1172-1-18. — 13. GARCIA CE, GIRDHAR-GOPAL HV, DORFMAN DM, *Ann Otol Rhinol Laryngol*, 102 (1993) 11. — 14. MILLER WT JR, PEREZ-JAFFE LA, *J Comput Assist*

Tomogr, 23 (1999) 548. — 15. KRUEGER GRF, HUETTER ML, ROJO J, ROMERO M, CRUZ-ORTIZ H *Anticancer Res*, 21 (2001) 2155. — 16. IFEACHO S, AUNG T, AKINSOLA M, *Cases J*, 1 (2008) 187. DOI: 10.1186/1757-1626-1-187. — 17. MELIKOGLU MA, MELIKOGLU M, *Acta Reumatol Port*, 33 (2008) 402. — 18. NORRIS AH, KRASINSKAS AM, SALHANY KE, GLUCKMAN SJ, *Am J Med*, 101 (1996) 401. DOI: 10.1016/S0002-9343(96)00231-8. — 19. BOSCH X, GUILABERT A, MI-

QUEL R, CAMPO E, *Am J Clin Pathol*, 122 (2004) 141. DOI: 10.1309/YF081L4TKYWVYVPQ. — 20. KUNG IT, NG WF, YUEN RW, CHAN JK, *Acts Cytol*, 34 (1990) 323. — 21. DORFMAN RF, BERRY GJ, *Semin Diagn Pathol*, 5 (1988) 329. — 22. KWON SY, KIM TK, KIM YS, LEE KY, LEE NJ, SEOL HY, *AJNR Am J Neuroradiol*, 25 (2004) 1099. — 23. BAUMGARTNER BJ, HELLING ER, *Ear Nose Throat J*, 81 (2002) 331.

H. Mihalj

»J. J. Strossmayer« University, Osijek University Hospital Center, Department of Otorhinolaryngology and Head and Neck Surgery, Josipa Huttlera 4, 31000 Osijek, Croatia
e-mail: hrvoje.mihalj@gmail.com

KIKUCHI-FUJIMOTO BOLEST: PRVI ZABILJEŽENI SLUČAJ U HRVATSKOJ

SAŽETAK

Kikuchi-Fujimoto bolesti (KFB) je izuzetno rijetka bolest, koja se pojavljuje u cijelom svijetu s većom učestalošću među japanskom i drugim azijskim populacijama. KFB je dobroćudni, samo-ograničavajući poremećaj kojeg karakterizira regionalna cervikalna limfadenopatija, najčešće uz blagu vrućicu i noćno znojenje. Manje česti simptomi su gubitak težine, mučnina, povraćanje i bolovi u grlu. Konačna dijagnoza se određuje na temelju tipičnih morfoloških promjena u zahvaćenom limfnom čvoru, stoga je biopsija limfnog čvora presudna za potvrdu dijagnoze. Ovdje predstavljamo šesnaestogodišnju djevojčicu, autohtonu hrvaticu, bijele rase s dokazanom KFB, kao prvi zabilježeni slučaj KFB-i u Hrvatskoj. Također, ovdje želimo istaknuti da KFB treba razmotriti kao mogući uzrok vrućice nepoznatog porijekla praćene limfadenopatijom.