

Angiosarcoma of the Hypopharynx: Case Report

Kotromanović, Željko; Mihalj, Hrvoje; Zubčić, Željko; Včeva, Andrijana; Birtić, Darija; Kotromanović, Zdenka; Rajc, Jasmina

Source / Izvornik: **Collegium antropologicum, 2012, 36, 185 - 187**

Journal article, Published version

Rad u časopisu, Objavljena verzija rada (izdavačev PDF)

Permanent link / Trajna poveznica: <https://um.nsk.hr/um:nbn:hr:239:467585>

Rights / Prava: [In copyright](#)/[Zaštićeno autorskim pravom.](#)

Download date / Datum preuzimanja: **2024-11-05**



Repository / Repozitorij:

[Repository UHC Osijek - Repository University Hospital Centre Osijek](#)

Angiosarcoma of the Hypopharynx: Case Report

Željko Kotromanović¹, Hrvoje Mihalj¹, Željko Zubčić¹, Andrijana Včeva¹, Darija Birtić¹,
Zdenka Kotromanović² and Jasmina Rajc³

¹ »J. J. Strossmayer« University, Osijek University Hospital Centre, Department of Otorhinolaryngology and Head and Neck Surgery, Osijek, Croatia

² »J. J. Strossmayer« University, Osijek University Hospital Centre, Department of Oncology and Radiotherapy, Osijek, Croatia

³ »J. J. Strossmayer« University, Osijek University Hospital Centre, Department of Pathology and Forensic medicine, Osijek, Croatia

ABSTRACT

Angiosarcomas are malignant neoplasias of rapid growth that emerge from endothelial cells. They are rarely found in the area of the head and neck and account less than 0.1% of all head and neck malignancies. In some cases it has been linked to trauma, radiation and angiectasia but the etiology mainly remains unknown. Here we report a case of angiosarcoma of pyriform sinus manifested by dysphagia and dysphonia. The patient underwent endoscopic hypopharyngeal excision followed by radiation therapy with a good result. Our patient remains tumor free after two years. The purpose of this article is to add another case of primary angiosarcoma of a rare site, the hypopharynx.

Key words: angiosarcoma, hypopharynx, immunohistochemistry, factor VIII

Introduction

Angiosarcomas are malignant neoplasias of rapid growth that develop from endothelial cells^{1,2}. It is also known as malignant hemangioendothelioma, angioblastoma, hemangiosarcoma and intravascular endothelioma. They are rarely found in the area of the head and neck and account less than 0.1% of all head and neck malignancies. They represent 2% of all sarcomas and only 1–4% are located in the upper aerodigestive tract^{3,4}. The causes are unknown, even if, in some cases, it is believed to be linked to trauma, radiation and angiectasia. It may be multifocal in origin. Although it can be found throughout the human body and affect various organs and structures, the extremities are the most commonly involved sites. Angiosarcoma of the head and neck is very rare and when it does occur in this region, the scalp and facial skin are the most common sites of origin.

Case Report

A 75-year-old male came to our clinic with a month history of dysphagia and dysphonia. During physical examination, a smooth purplish exofitic tumor, 2 × 2 cm in size, on a narrow base located in the right pyriform sinus area was identified. A CT scan showed a nonenhanced

tumor in the right pyriform sinus area. The patient underwent endoscopic hypopharyngeal excision in general anesthesia. We performed intraoperative histological biopsy, and there was no tumor cells left in mucosa. The operation was followed by radiation therapy with a good result. A biopsy revealed an intermediate-grade angiosarcoma. Immunohistochemical evaluation by means of markers, such as vimentin and factor VIII, offered a significant contribution to the diagnosis of angiosarcoma. Microscopic review of the specimen revealed an elongated fusiform nucleus cells with atypia which were also observed between the vascular areas (Figure 1). Immunohistochemical stain with Factor VIII revealed a clear membranous positivity in tumor cells (Figure 2). The final diagnosis was an intermediate-grade angiosarcoma. The patient continues symptom-free and with no evidence of local or distant metastasis 2 years after initial treatment in 2009.

Discussion

Appearance of angiosarcoma in the head and neck region is very rare, and in these few cases it has been shown mostly to affect the scalp and facial skin. Only 16

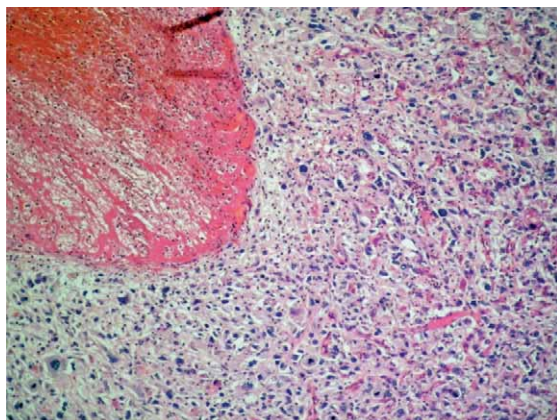


Fig. 1. (HE original magnification 100x) Showing typical angiosarcoma histological finding. Solid growth of markedly atypical epithelioid and spindle cells with only focal evidence of vascular differentiation.

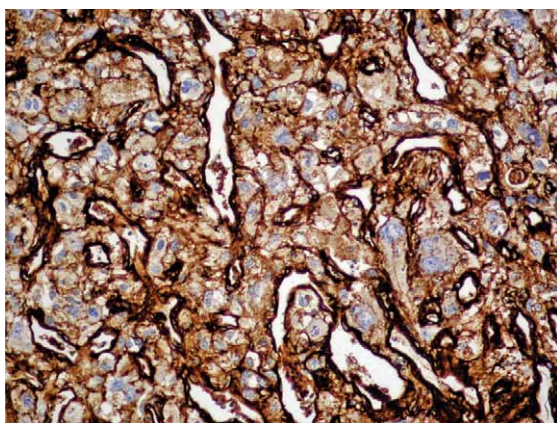


Fig. 2. (Factor VIII original magnification 200x). Immunohistochemical stain with Factor VIII reveals a clear membranous positivity in tumor cells.

cases of upper aerodigestive angiosarcomas have been reported since 1977⁵ in the world. Symptoms are non-specific: previous radiation exposure is frequently noted,

whereas the period of time for the presence of symptoms is short, usually one month. Tumours demonstrate the typical histomorphologic features of angiosarcoma in other soft tissue sites. Tumor cells are consistently positive with Factor VIII-related antigen, CD34 and CD31⁶. Our patient presented with a month history of dysphagia and dysphonia. Etiology is unknown and has been associated to certain risk factors such as chronic lymphedema, radiotherapy, vinyl chloride exposure, trauma and telangiectatic skin lesions.

Histological diagnosis is not always straightforward, as this neoplasm may be misdiagnosed as other vascular tumours (Kaposi's sarcoma, haemangiopericytoma), as non-neoplastic lesions (granulomas secondary to intubation) and as poorly differentiated squamous cell carcinoma⁷. In addition, appearance on unusual locations can lead to misdiagnosis. The histology of aerodigestive angiosarcomas is similar to that of angiosarcomas at other locations. It is characterized by multiple vascular anastomosis, sometimes having solid necrotic or hemorrhagic areas, particularly in high-grade tumors. The neoplastic vessels present atypical endothelium with prominent hyperchromatic nuclei and can be classified in high or low grade based on their microscopic appearance⁸. Diagnosis of angiosarcoma is established by pathological examination of the biopsy using hematoxylin-eosin staining. However, immunohistochemical staining with CD34 and factor VIII antigen is often required. Factor VIII-like antigen is synthesized in vascular endothelial cells and CD34 is specifically stained in vascular endothelial cells^{9–11}. Radical surgery with ample margins is the treatment of choice in patients with head and neck angiosarcoma. Free margins are the best prognostic factor for avoiding recurrence¹². Aerodigestive angiosarcomas have a better prognosis than angiosarcomas of other locations due to better cell differentiation and the presence of early symptoms. Recurrence can occur because of tumor tissue left during resection. Radical surgery followed by radiotherapy has been suggested as the treatment of choice. Good outcome in the case of our patient once more confirms the value of proposed therapy.

REFERENCES

1. VELEGRAKIS GA, PANAYIOTIDES JG, SKOULAKIS CE, PAPA-DAKIS CE, PAPA-DAKIS DG, BIZAKIS JG, HELIDONIS ES, *J Laryngol Otol*, 114 (5) (2000) 381. DOI: 10.1258/0022215001905634 — 2. KURIEN M, NAIR S, THOMAS S, *J Laryngol Otol*, 103 (9) (1989) 874. DOI: 10.1017/S0022215100110369 — 3. RUFUS MJ, POEN JC, TRAN LM, FU YS, JULLIARD GF, *Cancer*, 77 (1996) 2400. — 4. PISANI P, KRENGLI M, RAMPONI A, OLINA M, PIA M, *J Laryngol Otol*, 108 (1994) 905. DOI: 10.1017/S0022215100128476 — 5. TREVINO-GONZALEZ JL, SANTOS-LARTIGUE R, GONZALEZ-ANDRADE B, VILLAGOMEZ-ORTIZ VJ, VILLEGAS M, VENEGAS-GARCIA EM, *Cases Journal*, 2 (2009) 104. — 6. MAHESHWARI GK, BABOO HA, PATEL MH, GOPAL U, WADHWA K, *Turk J Canc*, 4 (2004) 34. — 7. LOOS ET AL., *The Laryngoscope*, 111

(2001) 1197. DOI: 10.1097/00005537-200107000-00012 — 8. KAZUTO F, KENJI D, SHINOBU K, GOU T, JUNJI A, MASAYO U, MAKOTO H, WATARU O, *Otolaryngology-Head and Neck Surgery*, 134 (2006) 886. — 9. WONG KF, SO CC, WONG N, SIU LL, KWONG YL, CHAN JK, *Cancer Genet Cytogenet*, 129 (2001) 64. DOI: 10.1016/S0165-4608(01)00431-9 — 10. KIMURA Y, TANAKA S, FURUKAWA M, *J Laryngol Otol* 106 (1992) 368. DOI: 10.1017/S0022215100119528 — 11. GNEPP DR, 1ST Edition, Philadelphia: Saunders 120 (2001). — 12. LEZAMA-DEL VALLE P, GERALD WL, TSAI J, MEYERS P, LA QUAGLIA MP, *Cancer*, 83 (1998) 1634. DOI: 10.1002/(SICI)1097-0142(19981015)83:8<1634::AID-CNCR20>3.3.CO;2-J

H. Mihalj

»J. J. Strossmayer« University, Osijek University Hospital Centre, Department of Otorhinolaryngology and Head and Neck Surgery, Josipa Huttlera 4, 31000 Osijek, Croatia
e-mail: mihalj.hrvoje@kbo.hr

ANGIOSARKOM HIPOFARINKSA: PRIKAZ SLUČAJA

S A Ž E T A K

Angiosarkomi su maligne neoplazme brzog rasta koje se razvijaju iz endotelnih stanica. Rijetko se nalaze u području glave i vrata, a incidencija im je manja od 0,1% svih malignih tumora glave i vrata. Uzroci nastanka su nepoznati, iako se u nekim slučajevima vjeruje da su povezani s traumom, zračenjem i angiektazijama. Prikazujemo slučaj angiosarkoma piriformnog sinusa hipofarinksa sa simptomima disfagije i disfonije. Pacijentu je učinjena endoskopska hipofaringelna ekscizija nakon koje je provedena adjuvantna radioterapija. Nakon dvije godine pacijent je i dalje bez recidiva tumora. Svrha ovog članka je prikazati još jedan slučaj primarnog angiosarkoma neuobičajenog sjela, hipofarinksa.