

The Significance of Helicobacter pylori in Patients with Nasal Polyposis

Včeva, Andrijana; Đanić, Davorin; Včev, Aleksandar; Birtić, Darija; Mihalj, Hrvoje; Zubčić, Željko; Kotromanović, Željko; Hadžibegović Đanić, Ana

Source / Izvornik: **Medicinski glasnik, 2012, 9, 281 - 286**

Journal article, Published version

Rad u časopisu, Objavljena verzija rada (izdavačev PDF)

Permanent link / Trajna poveznica: <https://um.nsk.hr/um:nbn:hr:239:387998>

Rights / Prava: [Attribution-NonCommercial-NoDerivatives 4.0 International](#)/[Imenovanje-Nekomercijalno-Bez prerada 4.0 međunarodna](#)

Download date / Datum preuzimanja: **2025-03-26**



Repository / Repozitorij:

[Repository UHC Osijek - Repository University Hospital Centre Osijek](#)

The significance of *Helicobacter pylori* in patients with nasal polyposis

Andrijana Včeva¹, Davorin Đanić², Aleksandar Včev³, Darija Birtić¹, Hrvoje Mihalj¹, Željko Zubčić¹, Željko Kotromanović¹, Ana Đanić Hadžibegović²

¹Department of Otorhinolaryngology, Head and Neck Surgery, University Hospital Centre Osijek, ²Department of Otorhinolaryngology, Head and Neck Surgery, General Hospital Slavonski Brod, ³Department of Internal Medicine, University Hospital Centre Osijek; Croatia

ABSTRACT

Aim To determine the presence of *Helicobacter pylori* in nasal polyps and the transmission of *H. pylori* from stomach to nasal polyps.

Methods In a prospective, controlled clinical research, 35 subjects with nasal polyps and 30 controls with concha bullosa (CB) were involved, and had been subjected to endoscopic sinus surgery (ESS). In the biopsies of removed polyps and CB, polymerase chain reaction (PCR) was used for detecting the *H. pylori* DNA. Blood samples of the test and control group were evaluated for *H. pylori* immunoglobulin (Ig) G and A antibodies by ELISA. The test and control group underwent esophagogastroduodenoscopy with taking biopsies from the stomach for PCR detection of *H. pylori* DNA.

Results In blood samples, specific IgG and IgA antibodies to *H. pylori* were found in 30 (85.71%) of 35 polyp patients and in 16 (53.33%) of 30 controls. In 10 (28.57%) of 35 patients *H. pylori* DNA was identified in the nasal polyp tissue, but it was not detected in the CB specimens. *H. pylori* DNA was found in the stomach mucosa samples of all test and control group of subjects. Significant statistical difference was found in the *H. pylori* specific IgG and IgA between the test and control group ($p < 0.006$) and between the polyp and control biopsy specimens of *H. pylori* DNA by PCR ($p < 0.001$).

Conclusion This research points to the colonisation of nasal polyps with *H. pylori*, the transfer of *H. pylori* from stomach to nasal polyps and potential role of *H. pylori* in emergence of nasal polyps.

Key words: *H. pylori*, nasal polypus, PCR, ELISA

Corresponding author:

Andrijana Včeva
Department of Otorhinolaryngology, Head
and Neck Surgery
University Hospital Centre Osijek
J. Huttlera 4, 31 000 Osijek, Croatia
Phone: +385 31 203 945;
fax.: +385 31 512 203;
E-mail: vceva.andrijana@yahoo.com

Original submission:

25 October 2011;

Revised submission:

04 January 2011;

Accepted:

09 January 2012.

INTRODUCTION

The history of nasal polyposis reaches far back to ancient past, since writings concerning this disease appear in 4,000 years old papyruses. Despite being known for such a long time, it remains a great mystery even today and the exact cause of the disease is unknown (1). Mechanisms assumed to have some influence in the emergence of nasal polyps are allergy, infection, autonomic imbalance, mucopolysaccharidosis, enzymatic disorder, sensitivity to medication, mechanical obstruction, histamine, proto-oncogenes and, more recently, gastroesophageal reflux disease (2). Recent insights concerning a high prevalence of *Helicobacter pylori* infection among patients suffering from various other diseases outside of the digestive system, e.g. among patients with acute coronary diseases, some skin diseases (chronic urticaria, rosacea), immune and vascular disorders etc., point to its potential role in the aetiologies of these conditions (3). In the last fifteen years, the number of studies indicating the relation between chronic rhinosinusitis and gastroesophageal reflux is increasing, from proving the presence of *H. pylori* on aspirates and sinus biopsies to pH-metric evidence of increased acidity and pepsin in epipharynx and nasal cavities in some patients with gastroesophageal reflux (4,5). These studies are particularly related to paediatric population, where a significant improvement in the rhinosinusitis symptoms has been evidenced following treatment with proton pump inhibitors (6,7,8,9,10). *H. pylori* is a slow pathogenicity bacterium that actively alters the immune response of an infected host, constantly supporting the imbalanced state between the bacterium's multiplication and the host's immune response (11). This explains the existence of a long-term (chronic) inflammatory reaction of relatively low intensity, which is characteristic in the pathological signs of *H. pylori* caused chronic gastritis (12). *H. pylori* organisms have been found in the sinonasal tissue by applying different diagnostic methods (13,14). Further, the mode of *H. pylori* infection spread to nose and sinuses has not been fully clarified yet. According to present knowledge, the basic route is human-to-human. It is assumed there are two modes of transmission: oral-oral (or stomach-to-mouth) and faecal-oral (15,16).

Main goal of our study is to determine the presence of *H. pylori* in nasal polyps and to determine the transmission of *H. pylori* from stomach to nasal

polyps. To detect *H. pylori* we used PCR detection of *H. pylori* DNA biopsy specimens and enzyme-linked immunoadsorbent assay (ELISA) of sera.

PATIENTS AND METHODS

In the prospective clinical research, 35 patients with nasal polyps and 30 controls with bullous middle nasal concha (CB) were involved and had been subjected to endoscopic sinus surgery (ESS) at the Department of Otorhinolaryngology, Head and Neck Surgery, University Hospital Centre of Osijek, Croatia.

Patients were included in the test group if they had histologically diagnosed nasal polyposis. Patients with CB without any signs of nasal polyposis constituted the control group. If they had any nasal pathology beyond CB on endoscopic or computed tomography (CT) exam they were excluded from the study.

Subjects with the following conditions were excluded from the research: ulcer disease, chronic atrophic gastritis with a history of taking H2 blockers, antacids or proton pump inhibitors one week prior to the surgical procedures or antibiotics within four weeks.

Prior to the ESS, serums of both groups were analyzed for *H. pylori* specific immunoglobulins (IgG, IgA) by ELISA. All subjects had undergone esophagogastroduodenoscopy prior to the ESS and two stomach biopsies were taken from antrum and corpus. The biopsies were frozen at -80°C for PCR detection of *H. pylori* DNA. Each ESS was done with local intensified anesthesia. Multiple biopsies were taken from the patients with nasal polyposis and from patients with CB. The biopsies were frozen at -80°C for PCR detection of *H. pylori* DNA. If two of the specimens from a patient were confirmed to be positive, that patient was recorded as positive for *H. pylori* (or when PCR was positive). The pathologist was unaware of the ELISA and PCR test results and the clinical diagnosis. All specimens were examined by one experienced pathologist from the Department of Pathology University Hospital Centre Osijek, Croatia. The study design was approved by ethics committees of the Clinical Hospital Center of Osijek and School of Medicine of the Josip Juraj Strossmayer University in Osijek.

All patients gave their written informed consents before being included in this study.

Serologic Analysis

Sampled vein blood was centrifuged at 2500 rpm for 5 minutes. Using the enzymatic immunoassay DRG *Helicobacter pylori* IgG, IgA ELISA kit (DRG Instruments, Marburg, Germany) on a microtiter plate, IgG and IgA antibodies for *Helicobacter pylori* in human serum were determined. Microtiter wells as a solid phase are coated with recombinant *Helicobacter pylori* Cag A antigen. Diluted patient specimens and ready-for-use controls are pipetted into these wells. During incubation *Helicobacter pylori*-specific antibodies of positive specimens and controls are bound to the immobilized antigens. After a washing step to remove unbound sample and control material horseradish peroxidase conjugated antihuman IgG, IgA antibodies are dispensed into the wells. During the second incubation this anti-IgG, IgA conjugate binds specifically to IgG, IgA antibodies resulting in the formation of enzyme-linked immune complexes. After the second washing step to remove unbound conjugate, the immune complexes formed (in case of positive results) are detected by incubation with TMB substrate and the development of blue color. The blue color turns into yellow by stopping the enzymatic indicator reaction with sulfuric acid. The intensity of this color is directly proportional to the amount of *Helicobacter pylori*-specific IgG, IgA antibodies in the patient specimen. Absorbance at 450 nm is read using an ELISA microtiter plate reader. The sensitivity and specificity of this kit are 99% and 97%, respectively (17).

PCR Analysis

DNA was isolated from the nasal polyp tissue samples, mucosa of bullous middle nasal concha and mucosa of stomach antrum and corpus using the QIAGEN DNeasy tissue kit mini-spin columns according to the manufacturer's instructions (QIAGEN, Hilden, Germany). Obtained tissue samples of 25 mg were placed in a 1.5 mL microcentrifuge tubes, added 180 uL buffer ATL, and 20 uL proteinase K, and incubate at 55 °C in a heat block until tissue is lysed. It was shaken occasionally, every 20-30 minutes. The incubation take approximately 1.5 hours. After 1.5 hours it was added 200 uL buffer AL to sample, mixed by hand, and incubated at 70° C for 10 min. in a heat block. Than 200 uL ethanol (96-100%) was added to the sample, mixed thoroughly by hand. DNeasy mini column was placed in a 2 mL collection tube, the mixture was pipetted from the microcentrifuge tube into the mini-column so that the mixture touched the filter but the pipette tip did

not, it was centrifuged for 1 min. at maximum speed (8000 rpm). Mini-column was placed in a new 2 mL collection tube, discarded flow-through, 500 uL buffer AW1 was added and centrifuged for 1 min. at maximum speed. Then, mini-column was placed in a new 2 mL collection tube, discarded flow-through, 500 uL buffer AW2 added and centrifuged for 3 min. at maximum speed. The filter was spun dry so there was no ethanol. After that the mini-column was placed in a new 1.5 mL microcentrifuge tube, pipetted 100 uL buffer AE directly onto the mini-column membrane, incubated at room temperature for 1 min., and then centrifuged for 1 min. at 8000 rpm. Leachates potentially containing *Helicobacter* DNA were analyzed using the standard fluorescent ABI *Helicobacter* plus – minus PCR assay, and the final fluorescence values were read using the ABI Prism 7000 real-time PCR device and analyzed with the appertaining software (18).

Statistical Analysis

The Pearson chi-square test was used to examine the relationship between the test and control groups. A P value less than 0.05 was considered significant. Statistical analyses were performed with SPSS for Windows, version 15.0., Chicago, IL, USA.

RESULTS

The nasal polyposis group comprised 35 consecutive patients: 25 (71.43%) males and 10 (28.57%) females. The median age of the patients was 54 years, with a range between 27 and 78 years, whereby the highest number of the patients was in the age group between 53 and 65 years (n=13, 37.14%) (Figure 1). The control group with CB

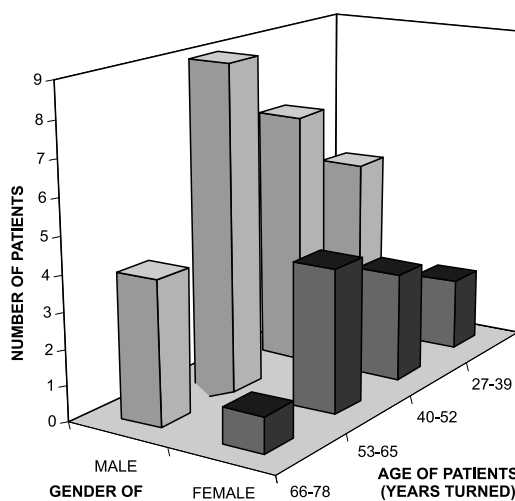


Figure 1. Distribution of patients with nasal polyposis according to age and gender

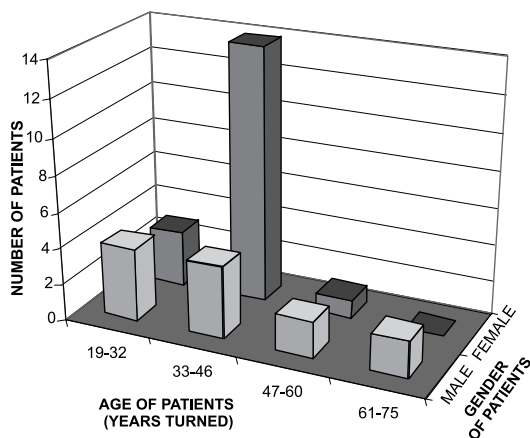


Figure 2. Distribution of control group with CB according to age and gender

consisted of 30 patients, of whom 12 (40%) were males and 18 (60%) were females, ranging in the age from 19 to 75 (median age 42.5) years, while the highest number of patients was in the age group of 33 to 46 (n=18, 60%) (Figure 2).

H. pylori specific IgG and IgA antibodies were detected in 30 (85.71%) of 35 patients with polyp, and in 16 (53.33%) of 30 controls. Negative results for the presence of IgG and IgA antibodies were found only in 5 (14.29%) out of 35 patients with nasal polyposis and in 14 (46.67%) out of 30 control group subjects (Table 1).

Ten of 35 (28.57%) biopsy specimens of polyps were positive, whereas none of the control group samples were positive for *H. pylori* DNA in PCR analysis. The patients with polyp in which *H. pylori* DNA was detected by PCR had *H. pylori*-specific IgG and IgA in the serum.

H. pylori DNA was detected in the stomach mucosa samples of all test and control group of subjects by PCR analysis.

Twenty six (out 74.29%) patients with nasal polyps and 18 (out 60%) patients with CB in the stomach mucosa samples were shown to be positive for *H. pylori* by histology (Table 2) (p=0.224).

Significant statistical difference was found in the *H. pylori* specific IgG and IgA between the test and control groups (p<0.006). The comparisons between the polyp biopsy specimens and the control biopsy specimens by the PCR analysis of *H.*

Table 1. Distribution of test and control patients with regard to presence of IgG and IgA antibodies to *H. pylori* by ELISA

IgG and IgA antibodies to <i>H. pylori</i>	N (%) of patients	
	Examinees	Controls
Positive	30 (85.71%)	16 (53.33%)
Negative	5 (14.29%)	14 (46.67%)
Total	35 (100%)	30 (100%)

Table 2. Distribution of test and control patients with regard to stomach histology

Histology of the stomach	N (%) of patients	
	Examinees	Controls
Gastritis chr. activa <i>H. pylori</i> (+)	26 (74.29%)	18 (60%)
Gastritis chr. <i>H. pylori</i> (-)	9 (25.71%)	12 (40%)
Total	35 (100%)	30 (100%)

pylori DNA revealed a significant statistical difference (p<0.001).

DISCUSSION

Nasal polyposis is marked by the formation of benign, stem-like growths on the mucous membrane with 1-4% prevalence in the total population and growing tendency (2). It is more frequent in males and its incidence increases with age (2), as confirmed by this research.

It is considered today that nasal polyps form as a result of local reaction of the sinus mucous membrane with a resulting mucosal hyperplasia as the secondary response to chronic inflammation (2). However, the initial or persisting stimulus for the chronic inflammation remains unknown (2). Recently, it has been considered that gastroesophageal reflux is in connection with several aerodigestive disorders, especially with sinusitis (19). Although the mechanism by which the gastroesophageal reflux causes sinusitis is unclear, we know that exposure to acid leads to mucosal oedema, secretion and chronic inflammation of the respiratory mucosa (19).

H. pylori colonizes the stomach, which is the most suitable medium for its survival. This is a medium with acid pH level, low oxygen concentration and all the ingredients that the microorganism requires, i.e. an environment where no other infective agent can compete with the bacterium. However, *H. pylori* was also discovered in other areas adjacent to the stomach, such as esophagus, duodenum, feces, oral cavity, saliva, dental plaque, tonsils and even nasal cavity (20,21).

There are contradictory data among studies about the presence and possible role of *H. pylori* in emergence of nasal polyps (13,14,20,22-26). Some studies (13,20,22,23) have confirmed the colonisation of *H. pylori* in nasal polyps and possible impact on the pathophysiology and management of nasal polyps. On the other hand, some studies (14, 24-26) did not find *H. pylori* in the tissue specimens of patients suffering from nasal polyposis. Furthermore, there are large differences in sensitivity and specificity of the diagnostic methods used in previous studies for the detection of *H. pylori* in the

nasal polyps (26). In the previous studies (13,14) researchers did not use highly sensitive and gold standard methods for *H. pylori* detection, such as PCR, so the negative and positive results could be criticized (26). On the other hand, in recent studies there are contradictions among researchers who used PCR for detecting *H. pylori* DNA in nasal polyps and control tissues (23,26). Ozyurt et al (23) detected *H. pylori* DNA by real-time PCR in nasal polyps, but also in normal nasal mucosa samples, and in larynx samples. However, Nemati et al (26) used three methods (i.e. PCR, culture, and urease test) to detect *H. pylori* and all three tests in the biopsied specimens of nasal polyps and in the control group were negative for *H. pylori*. They concluded that *H. pylori* can be considered as an accidental finding, rather than an etiological factor, in patients with nasal polyposis (26). However, they based their conclusions on patients without gastroesophageal reflux signs and symptoms and without investigating *H. pylori* DNA in stomach samples (26). So, they did not reveal the mechanism by which *H. pylori* colonizes nasal cavity or not. That mechanism is still unknown, and could be explained by three possibilities (13). First, the nasal cavity can be *H. pylori* reservoir (23). Second, the oral cavity can represent *H. pylori* reservoir and microorganisms can reach the sinonasal cavity by oronasal reflux (27). Third, stomach can be the primary infection reservoir and the transmission of *H. pylori* from stomach to nasal cavity can occur by means of gastroesophageal reflux (13).

REFERENCES

- Bernstein JM. Nasal Polyposis. In: Kennedy DW, Bolger WE, Zinreich SJ, eds. Diseases of the sinuses: diagnosis and management. Hamilton: BC Decker, 2001: 69-75.
- Tos M, Larsen PL. Nasal polyps: Origin, Etiology, Pathogenesis and Structure. In: Kennedy DW, Bolger WE, Zinreich SJ, ur. Diseases of the sinuses: diagnosis and management. Hamilton: BC Decker, 2001:57-68.
- Gasbarrini A, Franceschi F, Gasbarrini G, Pola P. Extradigestive diseases and *Helicobacter pylori* infection. Eur J Gastroenterol Hepatol 1997; 9:231-3.
- Morinaka S, Ichimiya M, Nakamura H. Detection of *Helicobacter pylori* in nasal and maxillary sinus specimens from patients with chronic sinusitis. Laryngoscope 2003; 113:1557-63.
- Ozmen S, Yücel OT, Sinici I, Ozmen OA, Süslü AE, Öğretmenoğlu O, Onerci M. Nasal pepsin assay and pH monitoring in chronic rhinosinusitis. Laryngoscope 2008; 118:890-4.
- Cunningham JM, Chiu EJ, Landgraf JM, Glicklich RE. The health impact of chronic recurrent rhinosinusitis in children. Arch Otolaryngol Head Neck Surg 2000; 126:1363-8.
- Phipps CD, Wood WE, Gibson WS, Cochran WJ. Gastroesophageal reflux contributing to chronic sinus disease in children. A prospective analysis. Arch Otolaryngol Head Neck Surg 2000; 126:831-6.
- DelGaudio JM. Direct nasopharyngeal reflux of gastric acid is a contributing factor in refractory chronic rhinosinusitis. Laryngoscope 2005; 115:946-57.
- Bothwell MR, Parsons DS, Talbot A i sur. Outcome of reflux therapy on pediatric chronic sinusitis. Otolaryngol Head Neck Surg 1999; 121:255-62.
- Dinis PB, Subtil J. *Helicobacter pylori* and laryngopharyngeal reflux in chronic rhinosinusitis. Otolaryngol Head Neck Surg 2006; 134:67-72.
- Blaser MJ. *Helicobacter pylori*: microbiology of a « slow » bacterial infection. Trends in Microbiology 1994; 1:255-60.
- Appemelt BJ, Negrini R, Moran AP, Kuipers EJ. Molecular mimicry between *Helicobacter pylori* and the host. Trends Microbiol 1997; 5:70-3.

All the aforementioned studies did not analyse nasal polyps and stomach mucosa for *H. pylori* DNA in regard to revealing the colonisation and transmission of *H. pylori* into nasal cavity. This study, for the first time ever, used real-time PCR, a gold standard method for *H. pylori* detection, to detect *H. pylori* DNA in tissue samples of nasal polyps, CB and stomach mucosa. The results of this study have shown the presence of *H. pylori* DNA in stomach mucosa of all tested and control subjects, in nasal polyp tissues (28.57%), but not in CB tissues.

It can be concluded that stomach is the primary *H. pylori* reservoir, it is transferred to the nasal cavity by gastroesophageal reflux, and consequently it colonizes nasal polyps, as opposed to the control subjects with CB where no *H. pylori* was found.

The results of this study have shown that real-time PCR is an appropriate method to assess *H. pylori* in tissues due to its sensitivity and specificity. Other methods assessed in this study (i.e., histology, serology) produce many false-negatives.

It should be emphasized that further epidemiological studies are necessary to use real-time PCR in order to prove the presence of *H. pylori* DNA in nasal polyps and stomach mucosa as a potential pathogenetic mechanism in the development of nasal polyps.

FUNDING

No specific funding was received for this study.

TRANSPARENCY DECLARATIONS

Competing interests: none to declare.

13. Koc C, Arikian OK, Atasoy P, Aksoy A. Prevalence of *Helicobacter pylori* in patient with nasal polyps: a preliminary report. Laryngoscope 2004; Volume 114:1941-4.
14. Szczygalski K, Jurkiewicz D, Rapiejko P. Detection of *Helicobacter pylori* in nasal polyps specimens using urease test GUT plus. Pol Merkuriusz Lek 2005; Volume 19:309-11.
15. Oshowo A, Tunio M, Gillam D, Botha AJ, Holton J, Boulos P, Hobsley M. Oral colonization is unlikely to play an important role in *Helicobacter pylori* infection. Br J Surg 1998; 85:850-2.
16. Cronmiller JR, Nelson DK, Jackson DK, Kim CH. Efficacy of conventional endoscopic disinfection and sterilization methods against *Helicobacter pylori* contamination. Helicobacter 1999; 483:198-203.
17. Stolte M, Eidt S. Healing gastric MALT lymphomas by eradicating *H. pylori*. Lancet 1993; 342:568
18. Jakobsson HE, Jernberg C, Andersson AF, Sjölund-Karlsson M, Jansson JK, Engstrand L. Short-term antibiotic treatment has differing long-term impacts on the human throat and gut microbiome. PLoS One 2010 Mar 24; 5:e9836.
19. Uluap SO, Toohill RJ, Hoffmann R, Shaker R. Possible relationship of gastroesophago-pharyngeal acid reflux with pathogenesis of chronic sinusitis. Am J Rhinol 1999; 13:197-202.
20. Ozdek A, Cirak MY, Samim E, Bayiz U, Safak MA, Turet S. A possible role of *Helicobacter pylori* in chronic rhinosinusitis: a preliminary report. Laryngoscope 2003; 113:679-82.
21. Song Q, Lange T, Spahr A, Adler G, Bode G. Characteristic distribution pattern of *Helicobacter pylori* in dental plaque and saliva detected with nested PCR. J Med Microbiol 2000; 49:349-53.
22. Cvorovic Lj, Brajovic D, Strbac M, Milutinovic Z, Cvorovic V. Detection of *Helicobacter pylori* in nasal polyps: preliminary report. J Otolaryngol Head Neck Surg. 2008; 37:192-5.
23. Ozyurt M, Gungor A, Ergunay K, Cekin E, Erkul E, Haznedaroglu T. Real-time PCR detection of *Helicobacter pylori* and virulence-associated cagA in nasal polyps and laryngeal disorders. Otolaryngol Head Neck Surg 2009; 141:131-5.
24. Cellini L, Allocati N, Dainelli B. Failure to detect *Helicobacter pylori* in nasal mucus in *Helicobacter pylori* positive dyspeptic patients. J Clin Pathol 1995; 48:1072-3.
25. Ozcan C, Polat A, Otag F, Gorur K. Does *Helicobacter pylori* play a role in etiology of nasal polyposis? Auris Nasus Larynx 2009; 36:427-30.
26. Nemati S, Mojtahedi A, Naghavi SE, Banan R, Zia F. Investigating *Helicobacter pylori* in nasal polyposis using polymerase chain reaction, urease test and culture. Eur Arch Otorhinolaryngol 2011; 268:1848-8.
27. Eyigor M, Eyigor H, Gultekin B, Aydin N. Detection of *Helicobacter pylori* in adenotonsillar tissue specimens by rapid urease test and polymerase chain reaction. Eur Arch Otorhinolaryngol 2009; 266:1611-13.

Značaj *Helicobacter pylori* u bolesnika s nosnom polipozom

Andrijana Včeva¹, Davorin Đanić², Aleksandar Včev³, Darija Birtić¹, Hrvoje Mihalj¹, Željko Zubčić¹, Željko Kotromanović¹, Ana Đanić Hadžibegović²

¹Klinika za otorinolaringologiju i kirurgiju glave i vrata, Klinički bolnički centar Osijek; ²Odjel za otorinolaringologiju i kirurgiju glave i vrata, Opća bolnica "Dr. Josip Benčević", Slavonski Brod; ³Klinika za unutarnje bolesti, Klinički bolnički centar Osijek; Hrvatska

SAŽETAK

Cilj Utvrditi prisutnost *Helicobacter pylori* u nosnim polipima i utvrditi prijenos *H. pylori* iz želuca u nosne polipe.

Metode U prospektivno, kontrolirano kliničko istraživanje, uključeno je 35 ispitanika s nosnom polipozom i 30 kontrolnih ispitanika s buloznom srednjom nosnom školjkom, a koji su podvrgnuti endoskopskoj sinusnoj kirurgiji (ESS). U biopsijama odstranjenih polipa i sluznice bulozne srednje nosne školjke, PCR-om je utvrđivana prisutnost *H. pylori* DNA. Uzorci krvi testne i kontrolne grupe ispitanika analizirani su na prisutnost specifičnih *H. pylori* protutijela klase IgG i IgA ELISA testom. I testnoj i kontrolnoj grupi ispitanika učinjena je ezofagogastroduodenoskopija s uzimanjem biopsija iz želuca radi PCR određivanja *H. pylori* DNA.

Rezultati U uzorcima krvi, *H. pylori* specifična protutijela klase IgG i IgA, pronađena su u 30 (85,71%) od 35 pacijenata s polipima, i u 16 (53,33%) od 30 kontrolnih ispitanika. U 10 (28,57%) od 35 pacijenata *H. pylori* DNA je otkrivena u tkivu nosnih polipa, ali nije otkrivena u uzorcima srednje nosne školjke. *H. pylori* DNA otkrivena je u uzorcima sluznice želuca u svih ispitanika testne i kontrolne grupe. Postoji statistički značajna razlika u ELISA dobivenim vrijednostima *H. pylori* protutijela IgG i IgA između pacijenata s nosnim polipima i kontrolne grupe ($p < 0.006$). Također, postoji statistički značajna razlika u PCR detekciji *H. pylori* DNA između biopsijskih uzoraka polipa i kontrolnih biopsijskih uzoraka ($p < 0.001$).

Zaključak Ovo istraživanje ukazuje na kolonizaciju nosnih polipa s *H. pylori*, na put prijenosa *H. pylori* iz želuca u nosne polipe, te na moguću ulogu *H. pylori* u nastanku nosnih polipa.

Ključne riječi: *H. pylori*, nosni polipi, PCR, ELISA