

Anterior Cervical Discectomy with Instrumented Allograft Fusion: Lordosis Restoration and Comparison of Functional Outcomes among Patients of Different age Groups

Mužević, Dario; Splavski, Bruno; Boop A, Frederick; Arnautović I., Kenan

Source / Izvornik: **World Neurosurgery, 2018, 109, 233 - 243**

Journal article, Published version

Rad u časopisu, Objavljena verzija rada (izdavačev PDF)

<https://doi.org/10.1016/j.wneu.2017.09.146>

Permanent link / Trajna poveznica: <https://urn.nsk.hr/urn:nbn:hr:239:190272>

Rights / Prava: [Attribution-NonCommercial-NoDerivatives 4.0 International/Imenovanje-Nekomercijalno-Bez prerada 4.0 međunarodna](#)

Download date / Datum preuzimanja: **2024-07-28**



Repository / Repozitorij:

[Repository UHC Osijek - Repository University Hospital Centre Osijek](#)



Anterior Cervical Discectomy with Instrumented Allograft Fusion: Lordosis Restoration and Comparison of Functional Outcomes among Patients of Different Age Groups

Dario Muzević¹, Bruno Splavski¹, Frederick A. Boop^{2,3}, Kenan I. Arnautović^{2,3}

■ **OBJECTIVE:** To investigate clinical parameters of anterior cervical discectomy and fusion (ACDF) treatment and outcomes using osseous allografts in different age groups, study the postoperative results of restoration of lordosis, and evaluate the utility of bone allografts for ACDF, including graft subsidence.

■ **METHODS:** We reviewed data from 154 patients with clinical symptoms and radiologic signs of disc herniation and/or cervical spondylosis. Decompression was achieved through discectomy, osteophyte ablation, endplate drilling, and foraminotomy. Fusion was achieved with allografts, demineralized bone matrix, and cervical plates/screws. The relationships between preoperative and postoperative cervical spine configuration (ie, Benzel's criteria), pain intensity, and neurologic status were analyzed.

■ **RESULTS:** The mean patient age was 51 years, and the median duration of symptoms was 6 months. The mean age differed significantly between the patients with diabetes and those without diabetes. The mean body mass index (BMI) was 30.36. Fifty-two patients had disc herniation, and 102 had spondylosis. Surgery was performed on a total of 313 levels. The median duration of follow-up was 24 months. Marked improvements in postoperative spine configuration or preservation of lordosis were recorded. Overall, 122 patients were neurologically intact, and 32 patients experienced residual postsurgery neurologic deficits (minor, n = 22; moderate, n = 9; severe, n = 1). Postoperative pain intensity and neurologic status were significantly improved. Outcomes were excellent in 66

patients, good in 61, fair in 24, and poor in 3 (no mortality). No significant differences in patient age, smoking habits, diabetes, or BMI were seen among outcomes, or between patients with soft disc herniation or spondylosis.

■ **CONCLUSIONS:** Osseous allografting can excellently restore cervical lordosis regardless of age and is an excellent graft choice for ACDF. Patients of advanced age with comorbidities should not be denied surgery.

INTRODUCTION

Anterior cervical discectomy and fusion (ACDF) is a widespread surgical procedure used to treat degenerative disease of the cervical spine. This procedure allows for ample neural decompression, the restoration of cervical lordosis as the optimal configuration, and achievement of solid bone fusion, resulting in spinal stability. The early surgical technique advocated by Smith and Robinson included the use of iliac bone autografts for bone fusion,¹ but patients undergoing autograft harvesting suffered various complications at the donor site. Thus, neurosurgeons began to use polyetheretherketone cages, titanium cages, and allograft bone to prevent these complications.² Since then, allografts have been reported to be inferior to autografts for interbody fusion, resulting in greater interspace collapse and angulation, increased failure rates, and an increased rate of radiographic nonunion.³ Recently, a systematic review comparing the efficacy and safety of ACDF procedures that used either titanium cages or iliac crest autografts indicated similar rates of interbody fusion and

Key words

- Age distribution
- Allograft
- Anterior cervical discectomy and fusion
- Lordosis
- Outcome

Abbreviations and Acronyms

ACDF: Anterior cervical discectomy and fusion
BMI: Body mass index
NDI: Neck disability index
RLN: Recurrent laryngeal nerve
VAS: Visual analog scale

From the ¹Department of Neurosurgery, Josip Juraj Strossmayer University of Osijek, School of Medicine, Osijek Clinical Hospital Center, Osijek, Croatia; ²Semmes-Murphey Neurologic and Spine Institute, Memphis, Tennessee, USA; and ³Department of Neurosurgery, University of Tennessee Health Science Center, Memphis, Tennessee, USA

To whom correspondence should be addressed: Kenan I. Arnautović, M.D., Ph.D.
 [E-mail: kenanarnaut@yahoo.com]

Citation: *World Neurosurg.* (2018) 109:e233-e243.
<https://doi.org/10.1016/j.wneu.2017.09.146>

Journal homepage: www.WORLDNEUROSURGERY.org

Available online: www.sciencedirect.com

1878-8750/© 2017 The Author(s). Published by Elsevier Inc. This is an open access article under the CC BY-NC-ND license (<http://creativecommons.org/licenses/by-nc-nd/4.0/>).

outcomes among 277 patients.⁴ Some authors have also used bioabsorbable implants, including anterior spinal interbody reconstruction with cervical spacers and biodegradable instrumentation.⁵⁻⁸ Few studies to date have investigated ACDF treatment outcomes with osseous allografts, however.

Our understanding of cervical lordosis and the correction of cervical deformity continues to evolve. Kyphosis is the most common degenerative deformity of the cervical spine, and its correction results in improved clinical outcomes.⁹ Nevertheless, the exact degree to which restoration of cervical spine lordosis contributes to the overall outcomes has not been well elucidated. Furthermore, the aging population means increasing numbers of patients of advanced age who are potential candidates for cervical spine surgery and who often have significant comorbidities. Treatment outcomes in this subgroup of patients require particular assessment, and have not been investigated adequately so far.

To our knowledge, this is the first study to investigate all the relevant clinical parameters of ACDF outcomes using osseous allografts after partial endplate drilling. We also studied results on restoring cervical lordosis after surgery. In addition, we evaluated the utility of bone allograft for ACDF, including graft subsidence. Finally, we compared all outcomes among 3 different age subgroups of ACDF patients to identify any differences in any outcome parameters across age groups.

METHODS

Our study cohort comprised consecutive patients who underwent surgery performed by the senior author (K.I.A.) at a single institution over a 3-year period (January 2011–December 2013). We reviewed all patients who had undergone ACDF surgery during that period. We then excluded all patients who had undergone previous ACDF surgery or a previous operation of any kind on the cervical spine. That left us only with patients who underwent first-time surgery for cervical degenerative disk disease. Basic demographic data were recorded for all included patients. The investigated sample was intended to be as homogeneous as possible with respect to demographic characteristics, presenting diagnosis, and number of cervical levels operated on. This was tested statistically. Patients were also screened for tobacco consumption and the presence of diabetes. Body mass index (BMI) was calculated for each patient as well.¹⁰ This study was approved by the hospital's Institutional Review Board.

The patients were divided into 3 subgroups according to age: 20–39 years, 40–59 years, and ≥ 60 years. The outcomes for each subgroup were analyzed separately to identify any differences that may be dependent on age before being analyzed together and compared.

In all patients, magnetic resonance imaging of the cervical spine was done preoperatively with conventional techniques. Preoperative assessment also included anterior-posterior, lateral, and flexion and extension lateral radiographs. The main degenerative pathology was assessed by an independent radiologist. The surgical approach was planned to address all clinically symptomatic cervical levels in the patients with radiologically documented compression. Diagnostic studies during postoperative follow-up included postoperative functional lateral radiography in flexion and extension performed at

6, 12, 18, and 24 months, as the criteria used for fusion assessment. In all indicated cases with any question regarding fusion, computed tomography scans of cervical spine thin cuts with sagittal and coronal reconstruction were performed. Images were analyzed by an independent neuroradiologist.

The surgical technique included a standard left-sided anterior approach to the cervical spine to prevent injury to the right recurrent nerve. Occipitontal traction was applied preoperatively with a chin strap to facilitate positioning and stability. The anterior surface of the cervical spine was exposed routinely, and radical decompression was achieved through discectomy, osteophyte ablation, and drilling of the cranial and caudal cartilaginous endplates, as well as a foraminotomy involving 2 nerve-root pairs for each level addressed. Fusion was achieved with cortical or corticocancellous grafts (Cornerstone SR and Cornerstone ASR; Medtronic Sofamor Danek USA, Memphis, Tennessee, USA), demineralized bone matrix (Progenix DBM Putty; Medtronic Sofamor Danek USA), and an anterior cervical plate and screws (Atlantis Vision Elite; Medtronic Sofamor Danek USA).

Radicular and axial pain intensity was assessed in all patients before and after surgery using a self-administered and self-reported visual analog scale (VAS).¹¹ Patients' preoperative and postoperative neurologic status was expressed semiquantitatively as follows:

- Normal: no objective neurologic findings
- Minor deficit: sensory changes in the arms and/or minor loss of motor strength in the arms
- Moderate deficit: significant sensory and motor deficits in the arms
- Severe deficit: signs of compressive myelopathy.

Each patient's status was assessed by an independent neurologist, and the overall treatment outcome was assessed using Odom's criteria¹² as the validated standardized outcome measure. The Neck Disability Index (NDI) questionnaire was used for additional assessment of preoperative clinical status and postoperative outcome.¹³ All patients were followed up for at least 2 years after surgery.

Each patient's cervical spine configuration was assessed on digitally processed cervical spine radiographs before and after surgery according to Benzel's criteria¹⁴ (Figure 1). The cervical spine configuration was defined accordingly as lordosis, straight spine, or kyphosis. A quantitative analysis of each patient's preoperative and postoperative cervical spine configuration was done using the posterior tangent angle according to Harrison¹⁵ (Figure 2). This method involves measuring the angle between tangents drawn at the posterior aspects of the vertebral bodies of C2 and C7, with negative values denoting kyphosis. Postoperative functional lateral radiographs in flexion and extension performed at 6, 12, 18, and 24 months were the criteria used for fusion assessment. In all indicated cases where there was any question regarding fusion, computed tomography scans of cervical spine thin cuts with sagittal and coronal reconstruction were performed.

The relationships among preoperative and postoperative pain intensity, neurologic status, cervical spine configuration, patient

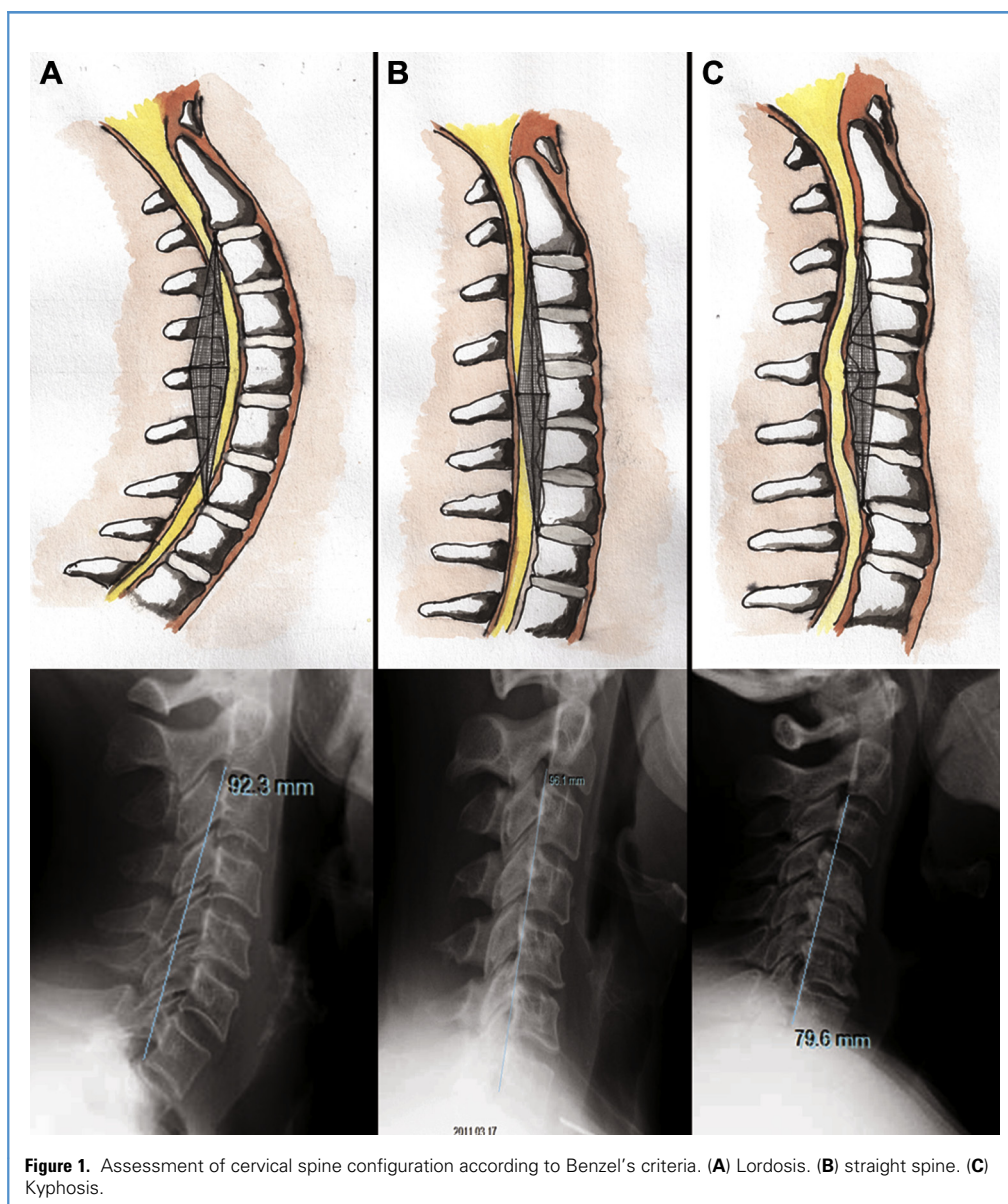


Figure 1. Assessment of cervical spine configuration according to Benzel's criteria. (A) Lordosis. (B) straight spine. (C) Kyphosis.

age, tobacco consumption, presence of diabetes, BMI, and treatment outcomes were analyzed.

All data were statistically analyzed with appropriate parametric and nonparametric tests using SPSS version 20.0 (IBM, Armonk, New York, USA). A significance level of $\alpha = 0.05$ was used to interpret results.

RESULTS

The study included 154 consecutive patients, predominantly females (100, vs. 54 males, a statistically significant difference), with a mean age of 51 years (range, 27–80 years) and a median

duration of symptoms of 6 months (range, 1–84 months). There were 27 patients (17.5%) in the younger subgroup (20–39 years), 73 patients (47.4%) in the middle subgroup (40–59 years), and 54 patients (35.1%) in the older subgroup (≥ 60 years). Demographic details of these patients are presented in [Table 1](#). The mean age of patients with diabetes and those without diabetes differed significantly (56.4 years vs. 49.6 years; $P < 0.01$, t test). The patients' mean BMI was 30.36 ± 5.58 , and no correlation was observed between patient age and BMI (Spearman's correlation coefficient, $\rho = -0.029$; $P = 0.719$).

Degenerative disc disease was single level in 48 patients (31.2%), 2-level in 56 (36.4%), 3-level in 47 (30.5%), and 4-level in 3

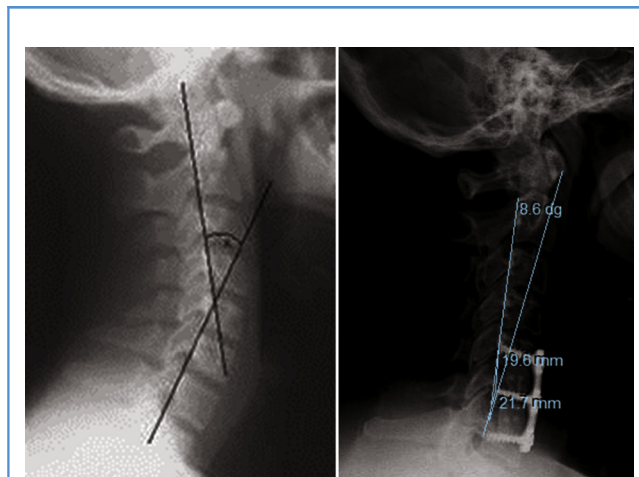


Figure 2. Cervical spine curvature measurement using the posterior tangent angle according to Harrison.

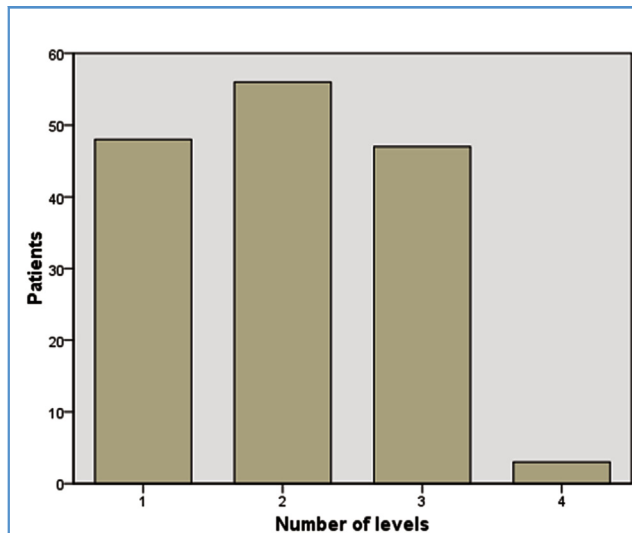


Figure 3. Distribution of patients according to the number of levels operated on (n = 154).

(1.9%) (Figure 3). A total of 313 levels were operated on, including 31 at C3/C4 (9.9%), 68 at C4/C5 (21.7%), 123 at C5/C6 (39.3%), and 91 at C6/C7 (29.1%) (Figure 4).

Preoperatively, the median axial and radicular pain intensity assessed with the VAS was 8 (range, 2–10) (Figure 5). Other preoperative status and spine configuration details are listed in Table 2. The mean preoperative posterior tangent angle according to Harrison was $12.23 \pm 14.84^\circ$ (Figure 6). A statistically significant positive correlation was observed between the Benzel and Harrison measurements (Spearman's $\rho = 0.794$; $P < 0.01$) (Figure 7).

Cortical allografts were used in 51 segments (16.3%), and corticocancellous allografts were used in 262 segments (83.7%). No allografts other than bone were used. Solid fusion was achieved in 97.92% of patients and 98.37% of levels at a mean follow-up of

5.97 ± 2.86 months. Graft sizes ranged from 8 mm to 15 mm. The most frequently used graft size for fusion was 11 mm (119 levels; 38%), followed by 10 mm (72 levels; 23%) and 12 mm (70 levels; 22.4%) (Figure 8). Other graft sizes were used only sporadically.

The median duration of follow-up was 24 months, and no patients were lost to follow-up. Preoperative spine configuration included kyphosis in 24%, loss of lordosis in 33%, and lordosis in 42%. Postoperative spine configuration improved; kyphosis was noted in 6.5%, loss of lordosis was noted in 32.5%, and lordosis was present in 61%. Postoperative spine configurations are shown in Table 2. The mean postoperative posterior tangent angle according to Harrison was $17.36 \pm 11.95^\circ$ (Figure 6). A

Table 1. Demographic Data (n = 154)		
Characteristic	Number of Patients	Percentage
Sex		
Female	100	64.9
Male	54	35.1
Age (years)		
20–39	27	17.5
40–59	73	47.4
≥60	54	35.1
Presence of diabetes	23	14.9
Tobacco use	59	38.3
Disc herniation	52	33.8
Cervical spondylosis	102	66.2

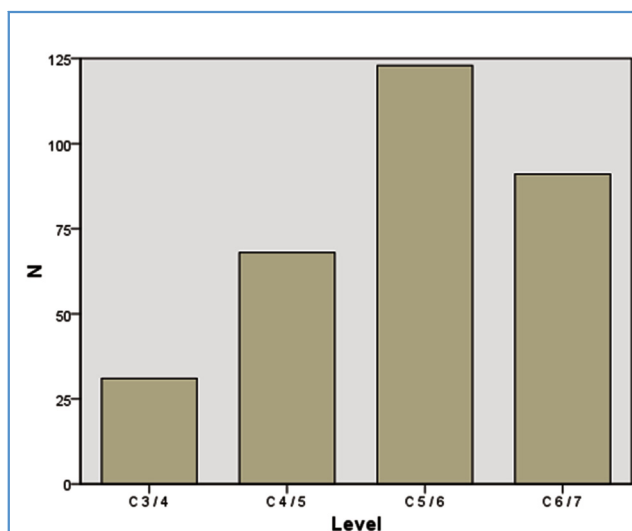
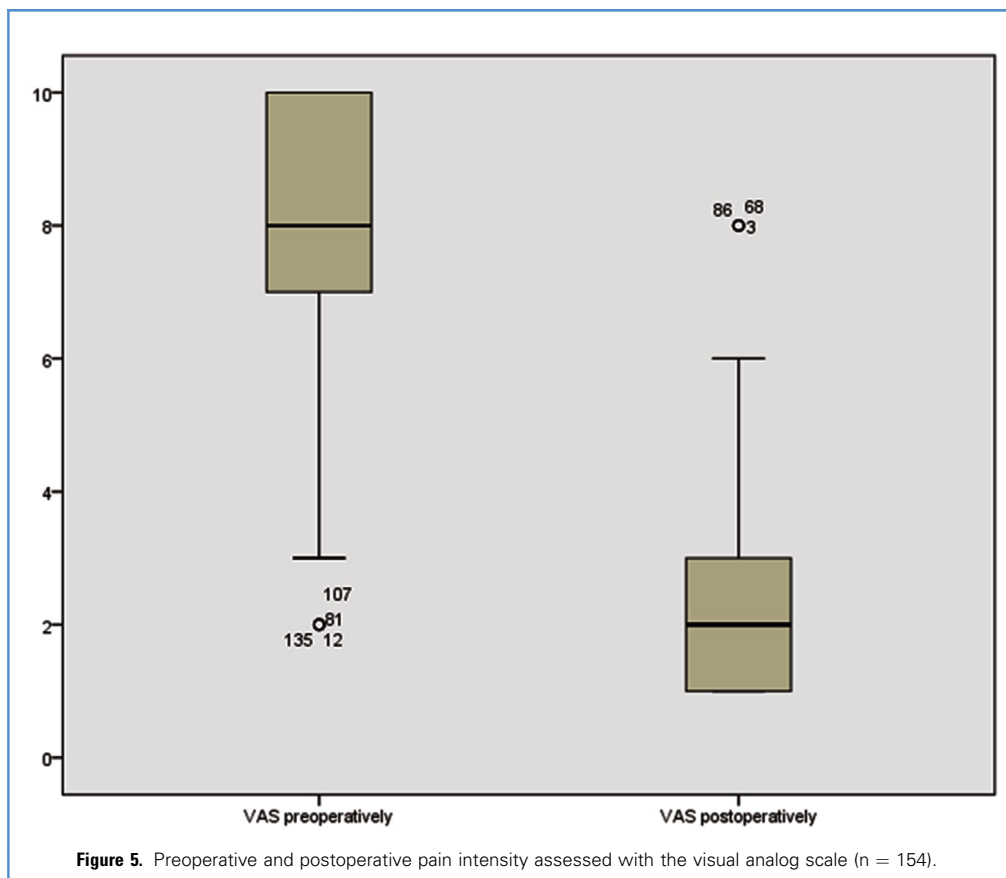


Figure 4. Distribution of vertebral segments operated on (n = 313).



statistically significant positive correlation was observed between cervical spine configuration according to Benzel and posterior tangent angle according to Harrison (Spearman's $\rho = 0.729$; $P < 0.01$) (Figure 9). A statistically significant difference also was observed between preoperative and postoperative cervical spine configurations assessed with Benzel's criteria ($P < 0.01$, Wilcoxon test), and as measured by the posterior tangent angle according to Harrison ($P < 0.01$, t test) (Figure 6). Improvement in cervical spine configuration assessed with Benzel's criteria (from kyphosis to straight spine, or from straight spine to lordosis) or preservation of preoperative lordosis was achieved in 114 patients (74%). No improvement or further decline in cervical spine configuration was noted in 40 patients (26%).

Graft subsidence was noted in 301 allograft implants (96.17%). The mean subsidence value was $7.12 \pm 4.44\%$.

Postoperatively, the median axial and radicular pain intensity assessed with the VAS was 2 (range, 1–8). Figure 5 compares preoperative and postoperative pain VAS scores. The postoperative neurologic status of patients and spine configuration details are shown in Table 2. A statistically significant difference was observed between preoperative and postoperative pain intensity ($P < 0.01$, Wilcoxon test), and between preoperative and postoperative neurologic status ($P < 0.01$, Wilcoxon test). The mean preoperative NDI was 61.15 ± 13.71 , and mean postoperative NDI was 14.25 ± 3.21 . A

statistically significant difference was observed between these values ($P < 0.01$, t test).

Treatment outcomes assessed by using Odom's criteria were excellent in 66 patients (42.9%), good in 61 (39.6%), fair in 24 (15.6%), and poor in 3 (1.9%), regardless of age (Figure 10). No postoperative mortality was noted in this series. Morbidity included 1 patient with transitory dysphagia and 1 patient with Horner's syndrome.

No statistically significant difference in patients' age was observed among 4 categories of treatment outcomes according to Odom's criteria ($P = 0.613$, Kruskal–Wallis test) (Figure 11). The outcomes among 3 different age subgroups of patients did not differ significantly. No statistically significant difference in treatment outcome was noted between patients with and without diabetes ($P = 0.835$, Mann–Whitney U test) or between smokers and nonsmokers ($P = 0.104$, Mann–Whitney U test). Furthermore, no statistically significant difference in treatment outcome was observed between patients in whom an improvement in cervical spine configuration or preservation of cervical lordosis was achieved and patients with unsuccessful lordosis restoration ($P = 0.112$; Mann–Whitney U test). Regarding the dominant degenerative pathology, no statistically significant difference in outcomes was observed between patients with cervical spondylosis and those with soft disc herniations ($P = 0.724$, Mann–Whitney U test). Finally, no

Table 2. Preoperative and Postoperative Neurologic Status and Configuration (n = 154)

Neurologic Status	Preoperative, Number (%)	Postoperative, Number (%)
Intact	18 (11.7)	122 (79.2)
Minor	86 (55.8)	22 (14.3)
Moderate	36 (23.4)	9 (5.8)
Severe	14 (9.1)	1 (0.6)
Configuration*		
Lordosis	65 (42.2)	94 (61)
Straight spine	51 (33.1)	50 (32.5)
Kyphosis	38 (24.7)	10 (6.5)

*According to Benzel's criteria.¹⁴

statistically significant difference in BMI was observed between patients with different treatment outcomes ($P = 0.199$, analysis of variance), and no statistically significant difference in treatment outcome was noted between female and male patients ($P = 0.596$, Mann–Whitney U test).

DISCUSSION

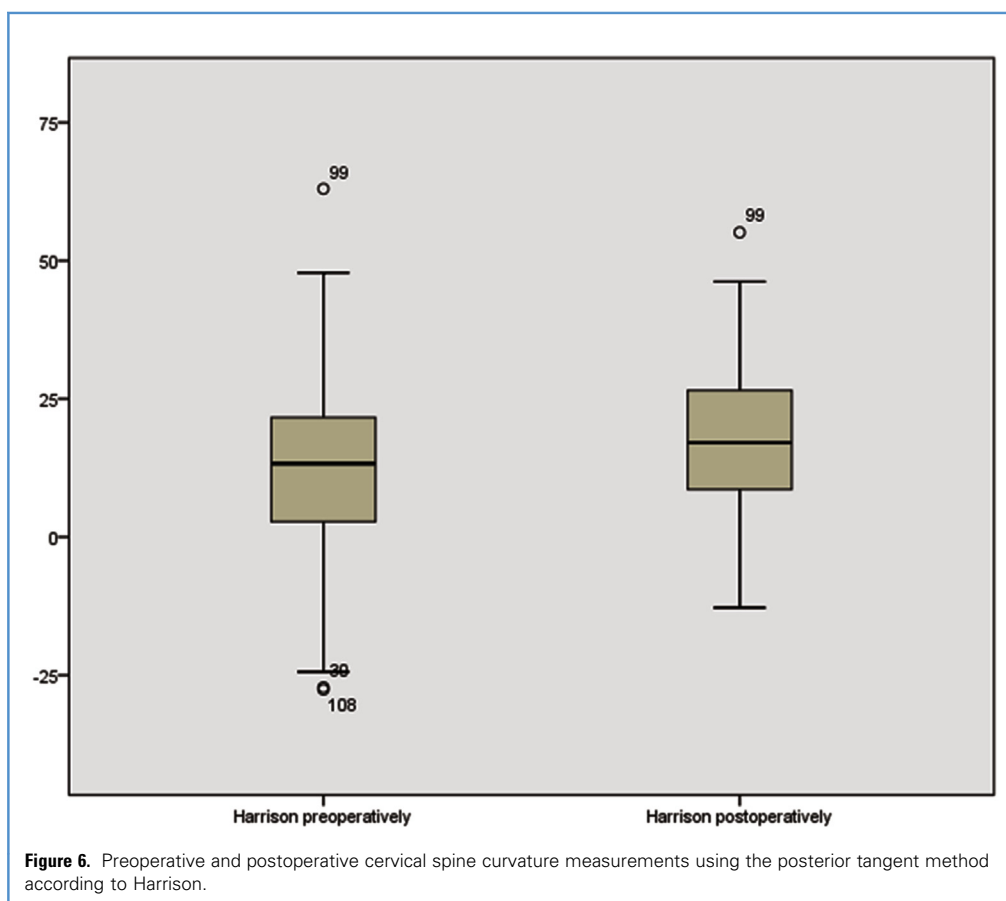
Demographics

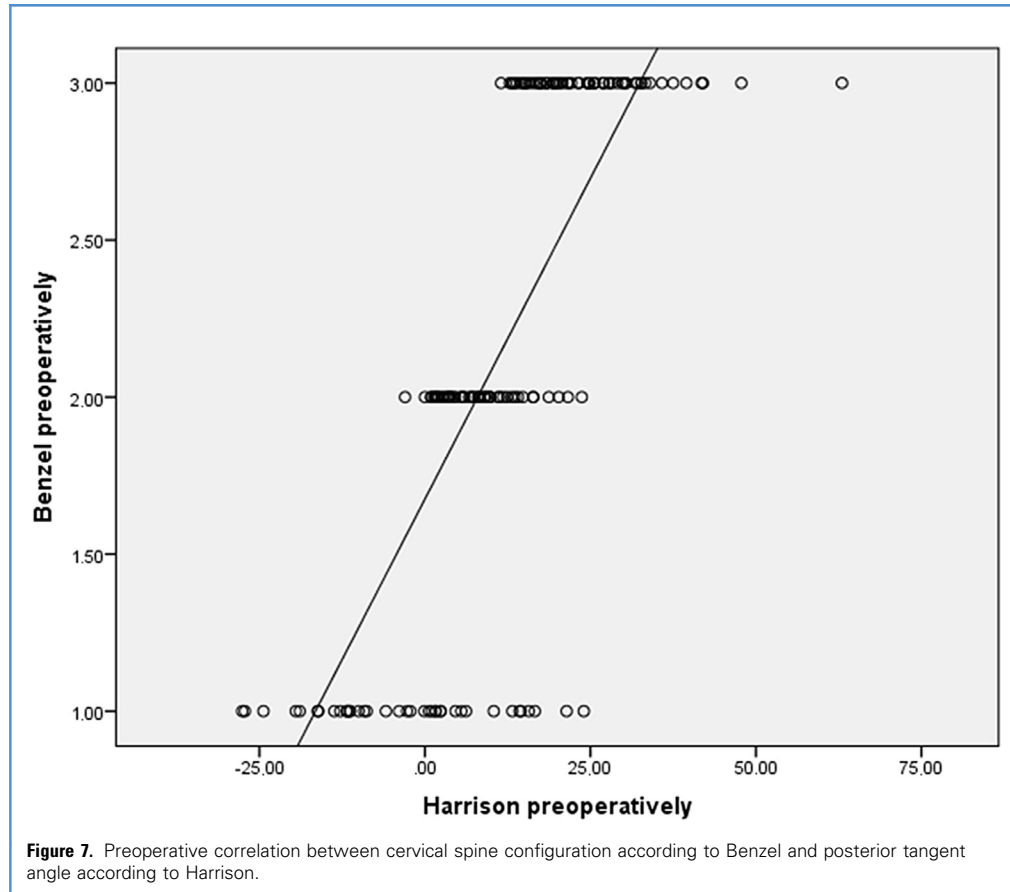
Our study included 154 patients, the significant majority female. Some investigators have speculated that disc degeneration in general depends on estrogen,^{16,17} which may partly explain the female predominance.

The mean patient age of ~50 years corresponds to the pathophysiology of cervical spine degenerative disease. Patients with soft disc herniations were generally younger than those with cervical spondylosis, as might be expected. However, we found no differences in outcomes across age subgroups, leading us to conclude that osseous allograft ACDF is not influenced by age-related parameters.

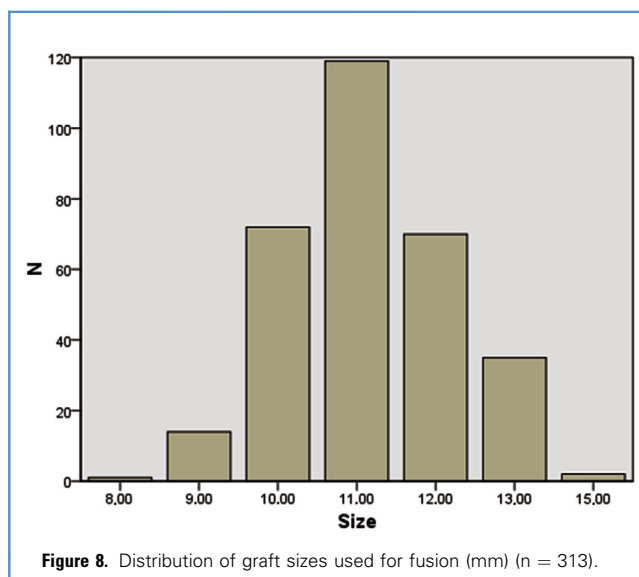
Surgical Technique

The cornerstones of the surgical technique used in this series are a left-sided approach and partial endplate cartilaginous drilling. None of the 154 patients in our series had permanent hoarseness or other signs of a recurrent laryngeal nerve (RLN) injury, which can be explained by the fact that these were patients with first-time ACDF surgery and not revisions. Erwood et al.¹⁸ reported a greater risk of hoarseness and dysphagia with repeated ACDF surgery resulting from RLN palsy compared with published rates of RLN injury after primary ACDF operations. None of the 154





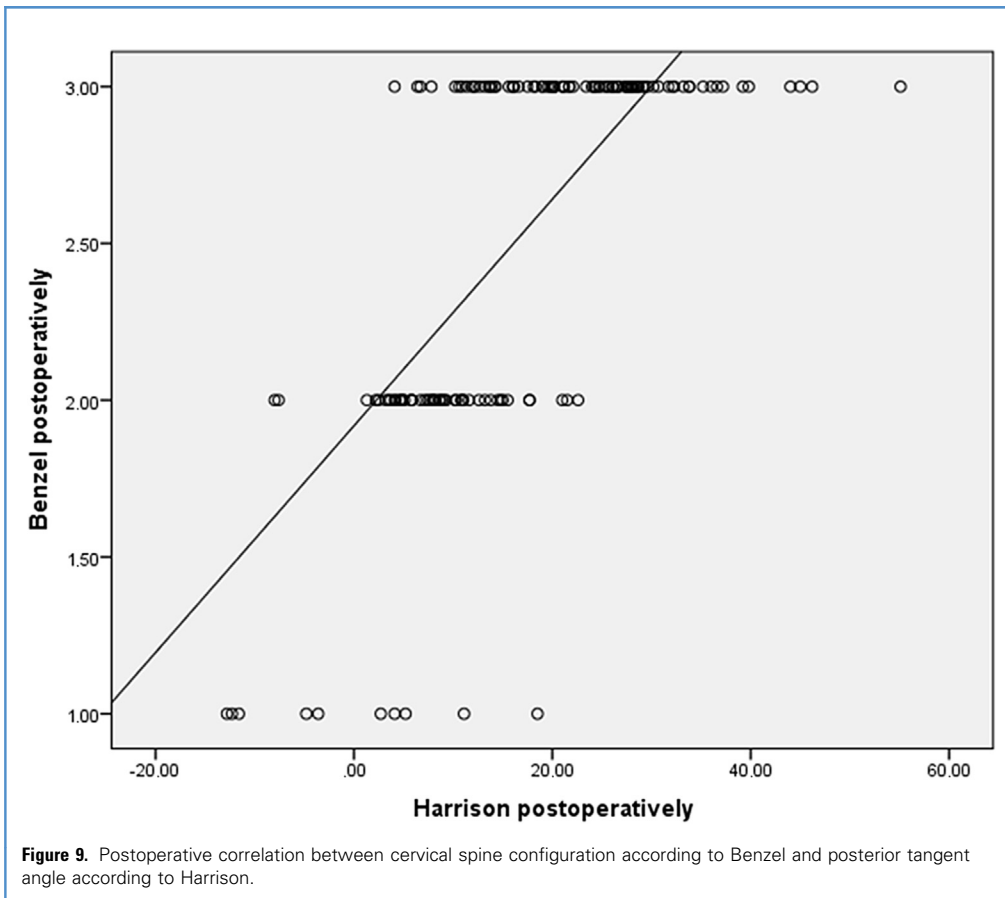
patients in our series had permanent hoarseness or other signs of an RLN lesion. We have not encountered any difficulties with injury to the thoracic duct during an approach from the left.



The allograft size (height) used to achieve solid bone fusion was between 10 and 12 mm in the vast majority of cases (83%). The use of these larger allografts is subsequent to decompression of the cervical medulla in the craniocaudal direction to an extent that enables foraminotomy for 2 pairs of nerve roots at each level. It does not imply that excessive traction was used to fit grafts into intervertebral spaces, because our technique included partial drilling of endplates to remove cartilaginous part and improve fusion. Therefore, slightly taller allografts could be used without overdistraction. This does not imply that excessive traction was used to fit grafts into intervertebral spaces. Obviously, excessive traction should be avoided, to prevent putting tensile forces on zygapophyseal joints. We were not able to identify any studies in which the authors reported allograft sizes, but we hypothesize that the use of slightly taller allografts contributed to better restoration of lordosis. Interestingly, graft subsidence was noted in the majority of levels (95%), but mean subsidence was only 7%.

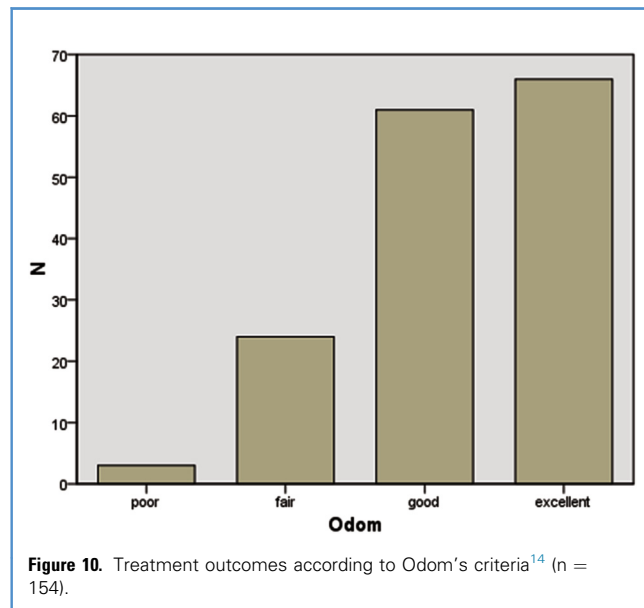
Anterior cervical plates and screws were used in all patients. The importance of a plate in load sharing is recognized, especially in patients with a kyphotic cervical spine.¹⁹ The improved fusion rate and negligible complication rate associated with anterior cervical plating are compelling factors to justify its use in the treatment of cervical spondylosis.²⁰

Transitory Horner's syndrome was noted in 1 patient, resulting from injury to the sympathetic chain. This injury was likely due



to retraction of the anterior longus colli muscle toward the uncovertebral joints, which enables safer orientation to the vertebral artery during foraminotomy. It should be noted that the

vertebral artery can be found within 1 mm of the lateral surface of the uncovertebral joint.²¹ It also should be emphasized that osseous allografts have multiple width and height sizing options. These grafts have proven to be an outstanding option for our patients, and their use precludes the need for tricortical ilium autografts.²²



Clinical Outcomes and Cervical Spine Configuration

In the vast majority of patients (74%), we were able to improve the cervical spine configuration or maintain preoperative lordosis. However, we have not been able to demonstrate a positive effect on overall treatment outcomes, which can be attributed to generally favorable results in the majority of patients, as well as to a relatively short follow-up period of 2 years. In other words, patients generally did very well postoperatively, and it was difficult to detect minute differences between very good and excellent clinical outcomes. We can speculate that the positive effects of an improvement in cervical spine configuration can be observed after a longer (5- or 10-year) follow-up. Furthermore, some studies have demonstrated the influence of ACDF on not only cervical but also whole-spine alignment, including thoracic kyphosis, lumbar lordosis, and whole sagittal balance.²³ Our results also imply that it is not necessary to use wedge-shaped implants with a pre-defined lordotic angle to restore cervical lordosis; implants with

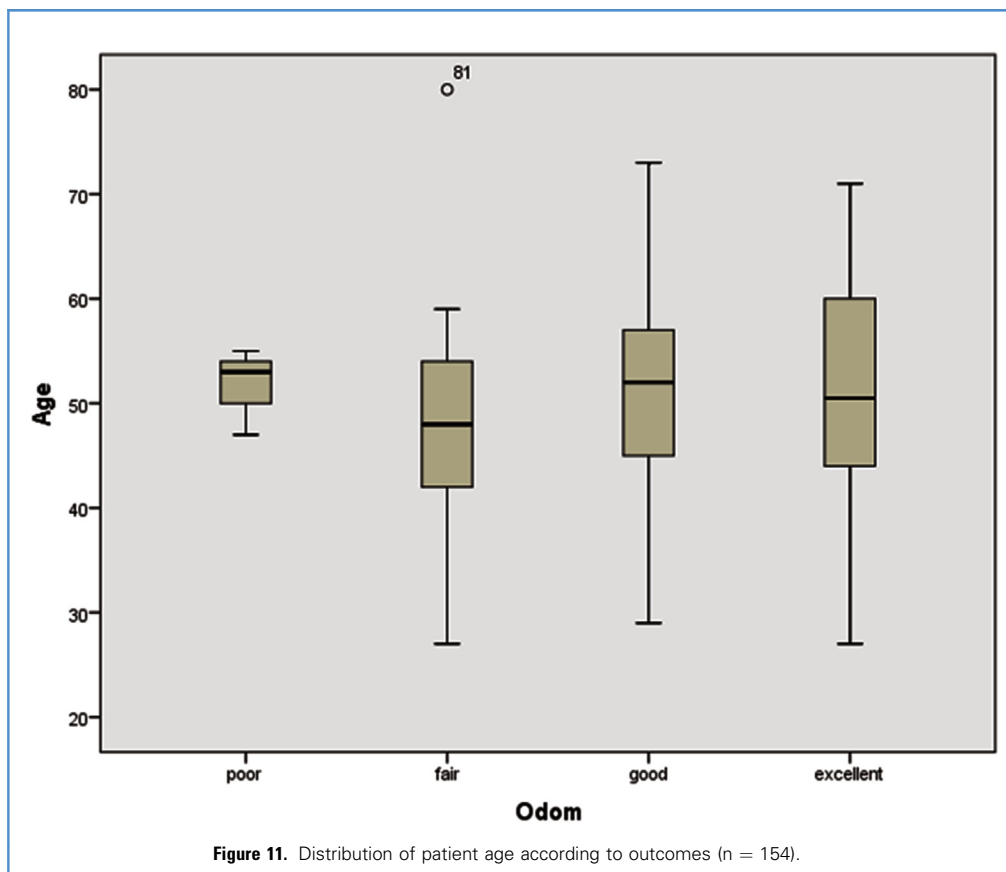


Figure 11. Distribution of patient age according to outcomes (n = 154).

parallel surfaces with adequate decompression and strategic drilling of vertebral bodies can achieve the same result.

Further questions arise regarding dynamic analysis of the cervical spine after fusion. Lin et al²⁴ compared dynamic radiographic changes of the cervical spine among patients with 1-, 2-, and 3-level fusion with a cage, and concluded that more extensive surgery improves lordosis, but at the expense of reduced range of motion.

A systematic review of trials to determine which ACDF technique provides the best outcome analyzed 4 studies (with a total of 220 patients) that compared fusion with autograft with any kind of allograft.²⁵ The authors concluded that the treatments examined in this comparison were too clinically heterogeneous to allow an analysis of which technique results in better outcomes. In addition, a systematic review was performed to evaluate clinical and radiographic outcomes in different ACDF studies that used allograft versus autograft, cage devices, and cervical disc arthroplasty.²⁶ This review found similar improvements in pain, functioning, and quality of life for all ACDF procedures, ensuring high bone-fusion rates. In other words, maintaining the lordotic curve to prevent adjacent segment disease can be achieved with various implants. Based on our experience, bone appears to be an excellent and natural allograft choice. Simultaneously, the authors stressed that allogeneic bone grafts have an excellent safety and effectiveness profile. In a recent retrospective

comparative study of 126 patients, Schulz et al.²⁷ reported that cages are a safe and effective alternative to autogenous bone graft, associated with significant improvements in clinical and radiologic outcome parameters. In a recent systematic review and evidence-based analysis of the effectiveness of biologically active graft alternatives, such as demineralized bone matrix in ACDF, patient-reported outcomes were not inferior compared with those associated with autografts and other bone substitutes, whereas outcomes associated with fusion and preservation of cervical lordosis were acceptable.²⁸ Obviously, additional studies on static and dynamic biomechanics after cervical fusion are needed.

We measured cervical spine configuration using a semi-quantitative method¹⁴ and a quantitative¹⁵ method. According to our findings, these 2 measures of cervical spine configuration are closely correlated. For everyday clinical practice, we believe it sufficient to use Benzel's method as a quick and reliable means of assessing the cervical spine configuration.

Regarding overall treatment outcomes, we achieved excellent and good outcomes in more than 80% of patients, regardless of age. Most had complete remission of their preoperative symptoms or had only minor residual complaints. The most obvious treatment effect was decreased pain intensity reported on the VAS, from a median of 8 to a median of 2. This decrease can be explained by the meticulous decompression of neural structures,

which promptly diminishes radicular pain. Eighty percent of patients had no neurologic deficit postoperatively, and only 1 patient had persistent symptoms of compressive myelopathy.

An important finding of this study is that treatment outcomes were independent of patient age, presence of diabetes, tobacco use, BMI, or type of compressive pathology (soft disc vs. spondylosis). Although whether smoking affects treatment outcomes is unclear, a recent study showed that patients with a history of smoking should be considered higher-risk surgical candidates for ACDF.²⁹

Patients should be selected for surgical treatment based on their symptoms and radiologic findings alone rather than on their age, possible comorbidities (e.g., diabetes, obesity), or other factors. Emphasizing this finding is important, given a recently reported study of neurosurgeons' opinions on patient selection for ACDF identifying age >65 years and the presence of diabetes as negatively influencing treatment outcomes.³⁰ Nonetheless, the average age of patients undergoing surgery for cervical spine degenerative disease is steadily increasing.³¹ Instrumented ACDF is both effective and durable, resulting in a favorable cost per quality-adjusted life-year gained compared with other widely accepted health care interventions.³²

Yue et al.³³ reported a similar study analyzing ACDF with allograft and plating, but with a somewhat longer follow-up (7 years), which demonstrated improved cervical lordosis in the majority of patients. The authors did not examine any correlation between the restoration of lordosis and clinical outcomes. They also reported good clinical outcomes in more than 80% of patients. Nevertheless, as noted by Hu et al.,³⁴ restoring cervical alignment may contribute to improved clinical outcomes in

patients undergoing 1- or 2-level ACDF surgery, and maintaining global cervical sagittal alignment is an important surgical factor in patients with ACDF.

To the best of our knowledge, this is the first study to investigate all the relevant clinical parameters of ACDF using osseous allograft after partial endplate drilling, including radiologic and clinical outcomes with particular emphasis on restoring cervical lordosis. In addition, we evaluated the utility of bone allografts for ACDF in a relatively large series of patients. We also studied and compared outcomes across 3 age subgroups of patients. Study limitations include a relatively short follow-up of 2 years, the retrospective design, and the subjective character of VAS self-reporting.

CONCLUSIONS

ACDF with osseous allograft and partial endplate drilling is effective for restoring cervical lordosis, resulting in excellent treatment outcomes regardless of patients' age. The use of bone allografts is an excellent choice for anterior cervical fusion with high rate of fusion and low mean subsidence rate. Older patients (≥ 60 years) and patients with co-morbidities have equally beneficial outcomes after this procedure and should not be denied surgical treatment.

ACKNOWLEDGMENTS

We thank Julie Yamamoto, MA for editorial assistance and language review and Andrew Gienapp, BA for copyediting, preparation of the manuscript and figures for publication, and publication assistance.

REFERENCES

- Robinson RA, Smith GW. Anterolateral cervical disc removal and interbody fusion for cervical disc syndrome. *Bull John Hopkins Hosp.* 1955;96:223-224.
- Gulsen S. The effect of the PEEK cage on the cervical lordosis in patients undergoing anterior cervical discectomy. *Open Access Maced J Med Sci.* 2015;3:215-223.
- Bishop RC, Moore KA, Hadley MN. Anterior cervical interbody fusion using autogeneic and allogeneic bone graft substrate: a prospective comparative analysis. *J Neurosurg.* 1996;85:206-210.
- Shao MH, Zhang F, Yin J, Xu HC, Lyu FZ. Titanium cages versus autogenous iliac crest bone grafts in anterior cervical discectomy and fusion treatment of patients with cervical degenerative diseases: a systematic review and meta-analysis. *Curr Med Res Opin.* 2017;35:803-811.
- Chen M, Yang S, Yang C, Xu W, Ye S, Wang J, et al. Outcomes observed during a 1-year clinical and radiographic follow-up of patients treated for 1- or 2-level cervical degenerative disease using a biodegradable anterior cervical plate. *J Neurosurg Spine.* 2016;25:205-212.
- Khajavi K, Shen A. Safety and efficacy of bioabsorbable cervical spacers and low-dose rhBMP-2 in multi-level ACDF. *Int J Spine Surg.* 2014;8:9.
- Vaccaro AR, Singh K, Haid R, Kitchel S, Wuisman P, Taylor W, et al. The use of bioabsorbable implants in the spine. *Spine J.* 2003;33:227-237.
- Vaccaro AR, Venger BH, Kelleher PM, Singh K, Carrino JA, Albert T, et al. Use of a bioabsorbable anterior cervical plate in the treatment of cervical degenerative and traumatic disk disruption. *Orthopedics.* 2002;25(10 Suppl):S1191-S1199 [discussion: S1199].
- Gillis CC, Kaszuba MC, Traynelis VC. Cervical radiographic parameters in 1- and 2-level anterior cervical discectomy and fusion. *J Neurosurg Spine.* 2016;25:421-429.
- World Health Organization. Physical status: the use and interpretation of anthropometry. Report of a WHO Expert Committee. *World Health Organ Tech Rep Ser.* 1995;854:1-452.
- Huskisson EC. Measurement of pain. *Lancet.* 1974; 2:1127-1131.
- Odom GL, Finney W, Woodhall B. Cervical disk lesions. *JAMA.* 1958;166:23-28.
- Vernon H, Mior S. The Neck Disability Index: a study of reliability and validity. *J Manipulative Physiol Ther.* 1991;14:409-415.
- Benzel EC. Degenerative and inflammatory disease of the spine. In: Benzel EC, ed. *Biomechanics of Spine Stabilization.* New York: Thieme; 2001:45-60.
- Harrison DE, Harrison DD, Cailliet R, Troyanovich SJ, Janik TJ, Holland B. Cobb method or Harrison posterior tangent method: which to choose for lateral cervical radiographic analysis. *Spine (Phila Pa 1976).* 2000;25:2072-2078.
- Wang YX, Griffith JF. Effect of menopause on lumbar disk degeneration: potential etiology. *Radiology.* 2010;257:318-320.
- Wang YX, Griffith JF. Menopause causes vertebral endplate degeneration and decrease in nutrient diffusion to the intervertebral discs. *Med Hypotheses.* 2011;77:18-20.
- Erwood MS, Hadley MN, Gordon AS, Carroll WR, Agee BS, Walters BC. Recurrent laryngeal nerve injury following reoperative anterior cervical discectomy and fusion: a meta-analysis. *J Neurosurg Spine.* 2016;25:198-204.
- Wang M, Gourab K, McGrady LM, Rao RD. Alteration of load sharing of anterior cervical implants with change in cervical sagittal alignment. *Med Eng Phys.* 2008;30:768-773.
- Kaiser MG, Haid RW Jr, Subach BR, Barnes B, Rodts GE Jr. Anterior cervical plating enhances arthrodesis after discectomy and fusion with

- cortical allograft. *Neurosurgery*. 2002;50:229-236 [discussion: 236-238].
21. Pait TG, Killefer JA, Arnautovic KI. Surgical anatomy of the anterior cervical spine: the disc space, vertebral artery, and associated bony structures. *Neurosurgery*. 1996;39:769-776.
 22. Arnautovic KI, Olinger RG. Anterior cervical discectomy, drainage and non-instrumented cortico-cancellous allograft fusion: a treatment option for ventral cervical spinal epidural abscess. *Med Arch*. 2012;66:194-197.
 23. Kim JH, Park JY, Yi S, Kim KH, Kuh SU, Chin DK, et al. Anterior cervical discectomy and fusion alters whole-spine sagittal alignment. *Yonsei Med J*. 2015;56:1060-1070.
 24. Lin HL, Cho DY, Liu YF, Lee WY, Lee HC, Chen CC. Change of cervical balance following single to multi-level interbody fusion with cage. *Br J Neurosurg*. 2008;22:758-763.
 25. Jacobs W, Willems PC, Kruyt M, van Limbeek J, Anderson PG, Pavlov P, et al. Systematic review of anterior interbody fusion techniques for single- and double-level cervical degenerative disc disease. *Spine (Phila Pa 1976)*. 2011;36:E950-E960.
 26. Miller LE, Block JE. Safety and effectiveness of bone allografts in anterior cervical discectomy and fusion surgery. *Spine (Phila Pa 1976)*. 2011;36:2045-2050.
 27. Schulz C, Mauer UM, Mathieu R. [Clinical and radiological results after anterior cervical corpectomy with cage fusion: a retrospective comparison of PEEK vs. titanium cages]. *Z Orthop Unfall*. 2017;155:201-208 [in German].
 28. Zadegan SA, Abedi A, Jazayeri SB, Vaccaro AR, Rahimi-Movaghar V. Demineralized bone matrix in anterior cervical discectomy and fusion: a systematic review. *Eur Spine J*. 2017;26:958-974.
 29. Purvis TE, Rodriguez HJ, Ahmed AK, Boone C, De la Garza-Ramos R, Elder BD, et al. Impact of smoking on postoperative complications after anterior cervical discectomy and fusion. *J Clin Neurosci*. 2017;38:1106-110.
 30. Tetreault LA, Nouri A, Singh A, Fawcett M, Fehlings MG. Predictors of outcome in patients with cervical spondylotic myelopathy undergoing surgical treatment: a survey of members from AOSpine International. *World Neurosurg*. 2014;81:623-633.
 31. Oglesby M, Fineberg SJ, Patel AA, Pelton MA, Singh K. Epidemiological trends in cervical spine surgery for degenerative diseases between 2002 and 2009. *Spine (Phila Pa 1976)*. 2013;38:1226-1232.
 32. Carreon LY, Anderson PA, Traynelis VC, Mummaneni PV, Glassman SD. Cost-effectiveness of single-level anterior cervical discectomy and fusion five years after surgery. *Spine (Phila Pa 1976)*. 2013;38:471-475.
 33. Yue WM, Brodner W, Highland TR. Long-term results after anterior cervical discectomy and fusion with allograft and plating: a 5- to 11-year radiologic and clinical follow-up study. *Spine (Phila Pa 1976)*. 2005;30:2138-2144.
 34. Hu X, Ohnmeiss DD, Zigler JE, Guyer RD, Lieberman IH. Restoration of cervical alignment is associated with improved clinical outcome after one and two level anterior cervical discectomy and fusion. *Int J Spine Surg*. 2015;9:61.

Conflict of interest statement: Dr. Boop serves as a consultant for Medtronic. The authors declare that the article content was composed in the absence of any commercial or financial relationships that could be construed as a potential conflict of interest.

Received 14 July 2017; accepted 21 September 2017

Citation: World Neurosurg. (2018) 109:e233-e243.

<https://doi.org/10.1016/j.wneu.2017.09.146>

Journal homepage: www.WORLDNEUROSURGERY.org

Available online: www.sciencedirect.com

1878-8750/© 2017 The Author(s). Published by Elsevier Inc.

This is an open access article under the CC BY-NC-ND license (<http://creativecommons.org/licenses/by-nc-nd/4.0/>).