

# Heterotopic Trigeminal Pregnancy in Infertile Women after Ovulation Stimulation and Embolisation of a Uterine Myoma

---

Muller-Vranješ, Andrijana; Popović, Zoran; Kasač, Zoran; Vlahović, Ivan; Habek, Dubravko

Source / Izvornik: **Fetal Diagnosis and Therapy, 2006, 21, 81 - 83**

Journal article, Published version

Rad u časopisu, Objavljena verzija rada (izdavačev PDF)

<https://doi.org/10.1159/000089054>

Permanent link / Trajna poveznica: <https://um.nsk.hr/um:nbn:hr:239:233275>

Rights / Prava: [Attribution-NonCommercial-NoDerivatives 4.0 International/Imenovanje-Nekomercijalno-Bez prerada 4.0 međunarodna](#)

Download date / Datum preuzimanja: **2024-08-11**



Repository / Repozitorij:

[Repository UHC Osijek - Repository University Hospital Centre Osijek](#)

# Heterotopic Trigeminal Pregnancy in Infertile Women after Ovulation Stimulation and Embolisation of a Uterine Myoma

A. Müller Vranješ Z. Popović Z. Kasač I. Vlahović D. Habek

Department of Obstetrics and Gynaecology, Division of Perinatology, Osijek University Hospital, Osijek, Croatia

## Key Words

Heterotopic pregnancy · Clomiphene citrate · Ultrasonography · Myoma embolisation · Laparoscopic salpingectomy

## Abstract

Heterotopic pregnancy is a simultaneous occurrence of intra-uterine pregnancy and ectopic pregnancy. The incidence of ectopic pregnancy has increased as a consequence of assisted reproduction and ovulation stimulation agents. In this report, we describe the case of a 34-year-old nulliparous woman who became pregnant after ovulation induction with clomiphene. According to her gynaecologic history, she had embolisation of a uterine myoma. The report presents a case of ectopic and twin intra-uterine pregnancy. After total laparoscopic salpingectomy, she had normal intra-uterine pregnancy.

Copyright © 2006 S. Karger AG, Basel

## Introduction

Simultaneous occurrence of intra-uterine and extra-uterine pregnancy is called heterotopic pregnancy (HP). It is a very rare complication in pregnancy, above all if there are no predisposed factors such as methods of assisted reproduction (MAR). It is characterized by different symptoms, which very often postpone the final and accurate diagnosis.

## Case Report

Ž.F., a 34-year-old pregnant woman, was admitted to out-patient surgery of the Gynaecological Department. She had symptoms of a haemorrhagic shock: faintness, RR 90/60 and rapid pulse about 90 with beaded sweat.

Gynaecological findings were: vagina narrow, wrinkled, with mucous discharge, cylindrical vaginal part, cervical canals closed, uterus enlarged as for pregnancy of the 3rd month, diffuse pain in the lower abdomen with defence of the intra-umbilical muscle system.

Gynaecologic history was: 5 years of sterility, 1 miscarriage in the 10 weeks of pregnancy following induction of ovulation by clomiphene. Five months later, she had embolisation of a uterine myoma on the anterior uterine wall (7 × 9 cm).

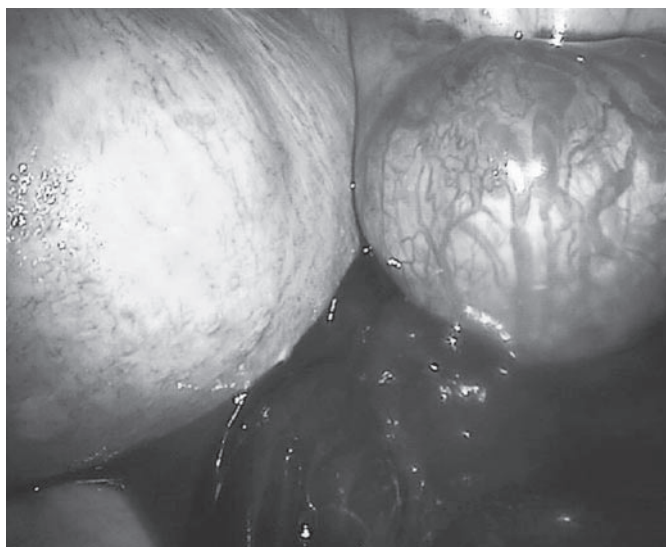
Ten months after embolisation, the cycle was stimulated by clomiphene citrate 2 × 50 mg from 3 to 8 days. Before stimulation, the myoma was 37 × 39 mm. After ovulation stimulation, control sonography revealed two visible gestation sacs in the uterus, whereas both adnexa were without visible pathological forms.

The pregnant woman was monitored on a regular basis, both by ultrasonography and clinically, every 14 days with recommended therapy with progesterone and folic acid substitution.

Following the admittance examination, the patient was examined by ultrasound: in the uterine cavity, two visible gestation sacs were detected with vital fetuses – CRL1 = 29.6, i.e. 9–10 weeks; FHR (fetal heart rate) +; CRL2 = 34, i.e. 10 weeks; FHR +. In the fundus, a myoma knot (43 mm) was found.

On the right, next to the uterus, a gestation sac was detected with visible fetal echo (CRL = 34, i.e. 10 weeks; FHR +). In the abdomen and in the cavum douglasi, visible anechogenic echo-free liquid was detected. Lab results were as follows: L 22.9; E 2.97; Hb 85.7; Htc 0.262; Tr 240.

Due to acute abdomen and haemorrhagic shock and HP discovered by ultrasonography, an urgent laparoscopical surgery was performed.



**Fig. 1.** Fundal subserous myoma, right tubal ectopic pregnancy with abortus tubarius.

Intra-operatively, liquid and coagulated blood was found (approx. 400 ml), as well as an enlarged gravid uterus, and in the fundus, a right subserous, myomatous knot. Right adnexa were thicker, thin walls bluish, blood was dripping through the abdominal orifice, and adnexal wall was partly bleeding (abortus tubarius; fig. 1). The right ovary was normal as were the left adnexa. By bipolar current and scissors, the gravid tube was separated and salpingectomy on the right side was performed. Haemostasis was evaluated and the abdomen bathed. The operation was performed with no irregularities.

During the operation, the patient had standard infusion treatment, low-molecular heparin and progesterone depot. Control postoperative haemogram and coagulogram were within reference values. Postoperative course was normal. On the eighth day postoperatively, sutures were taken out; the wound healed per primam.

On the day of discharge from hospital, control ultrasonography revealed the following results: CRL40, i.e. 11 weeks; FHR for the first and second twins was positive. On the right and on the front, there was a knot of 46 × 42 × 58 mm.

The patient was discharged in good condition with the recommendation to take folic acid and iron preparations.

## Discussion

Frequency of HP occurrence increases due to MAR. The incidence of HP is 1:30,000 and the present percentage seems to be significantly higher [1–4]. Reasons for that are more frequent ectopic pregnancies and the use of clomiphene in the treatment of infertile women. Clomiphene citrate is an anti-oestrogen used for ovulation induction, very often empirically, in women who seem to

have ovulation, but who are infertile [5]. The analysed complications following treatment with clomiphene citrate are hyperstimulation, adnexal torsion, HP, change of mood [6, 7] and there are cases of convulsions after the above therapy [5]. The percentage of HP in MAR is about 1.14%, which is rather frequent [1, 8, 9]. This is according to Hulvert et al. [1] who monitored the occurrence of HP when applying MAR. They prospectively monitored 618 clinical pregnancies out of which 23 (3.7%) were ectopic. Of these 23 pregnancies, 7 were heterotopic (30.5%). Following a concrete treatment, the prognoses for intra-uterine gestation were promising and in the above study, in 78% cases birth was given to a live child [10, 11]. Very often HP is not diagnosed early enough to avoid serious consequences. To arrive at an accurate diagnosis, risk factors should be taken into account [3, 4, 11] as well as transvaginal and transabdominal ultrasonography, which proved to be complementary methods [12, 13]. Both of them are valuable if performed by an experienced sonography expert.

Laparoscopic treatment of ectopic pregnancy has become a very frequent method. According to the reference literature [10, 11, 14–16], laparoscopic surgery has its advantages. In all published papers which analyse laparoscopic surgery of HP, no complications have been mentioned. The same applies to our case. The first step of a surgical treatment is laparoscopic salpingectomy. Following laparoscopic treatment, the intra-uterine gestation develops successfully [10], which can be confirmed by our case report as well. The first early ultrasonography in our case did not reveal ectopic pregnancy, which confirms the fact that about 20–50% of ectopic pregnancies cannot be verified by ultrasound.

The accurate diagnosis of HP indicated adequate and timely surgery, prevented complications of ectopic pregnancy and enabled successful twin intra-uterine gestation.

## References

- 1 Hulvert J, Merdesic T, Vuborij J, Muller P: Heterotopic pregnancy and its occurrence in assisted reproduction. *Ceska Gynekol* 1999; 64:299–301.
- 2 Ludwig M, Kaisi M, Bauer O, Diedrich K: Heterotopic pregnancy in a spontaneous cycle: do not forget about it! *Eur J Obstet Gynecol Reprod Biol* 1999;87:91–93.
- 3 Tellez Velasco S, Vital Reyes VS, Rosales de la Rosa D, Hinojosa Cruz JC, Reyes Fuentes A: Heterotopic pregnancy following ovulation induction by clomiphene citrate and prednisone. Report of a case. *Ginecol Obstet Mex* 1999;87: 91–93.
- 4 Dammann G, Murphy L, Ellis J: Twin heterotopic pregnancy after assisted reproduction. A case report. *J Reprod Med* 2002;47:246–248.
- 5 Rimmington MR, Vine SJ, Chui DKC, Walker SM: Drug points: convulsions after clomiphene citrate. *BMJ* 1994;309:512.
- 6 Glassner MJ, Aron E, Eskin BA: Ovulation induction with clomiphene and the risk in heterotopic pregnancies. A report of two cases. *J Reprod Med* 1990;35:175–178.
- 7 Sotrel G, Rao R, Scommegna A: Heterotopic pregnancy following clomid treatment. *J Reprod Med* 1976;16:78–80.
- 8 Dumesic DA, Damarico MA, Session DR: Intestinal heterotopic pregnancy in a woman conceiving by in vitro fertilization after bilateral salpingectomy. *Mayo Clin Proc* 2001;76: 90–92.
- 9 Barron Vallejo J, Ortega Diaz R, Kably Ambre A: Heterotopic pregnancy with intrauterine dizygotic twins following embryo transfer in the blastocyst phase. *Ginecol Obstet Mex* 1999;67: 169–172.
- 10 Wang PH, Chao HT, Tseng Jy, Wang TS, Chang SP, Yuan CC, Ng HT: Laparoscopic surgery for heterotopic pregnancies: a case report and a brief review. *Eur J Obstet Gynecol Reprod Biol* 1998;80:267–271.
- 11 Berliner I, Mesbah M, Zalud I, Maulik D: Heterotopic triplet pregnancy. Report of a case with successful twin intrauterine gestation. *J Reprod Med* 1998;43:237–239.
- 12 Ousehal A, Mamouchi H, Ghazil M, Kadiri R: Heterotopic pregnancy: value of transabdominal sonography. *J Radiol* 2001;82:851–853.
- 13 Franke C, Rohrborn A, Thiele H, Glatz J: Combined intrauterine and extrauterine gestation. A rare cause of acute abdominal pain. *Arch Gynecol Obstet* 2001;265:51–52.
- 14 Schafer MT, Henrich W: Intact unilateral twin pregnancy – Sonographic diagnosis and laparoscopic treatment. *Ultraschall Med* 1999;20: 171–173.
- 15 Mistry BM, Balasubramaniam S, Silverman R, Sakabu SA, Troop BR: Heterotopic pregnancy presenting as an acute abdomen: a diagnostic masquerader. *Am Surg* 2000;66:307–308.
- 16 Pschera H, Gatterer A: Laparoscopic management of heterotopic pregnancy: a review. *J Obstet Gynaecol Res* 2000;26:157–161.