

From Postpartum Metastatic Cancer to Parathyroid Adenoma: a Case Report

Baćun, Tatjana; Kibel, Aleksandar; Wertheimer, Vjekoslav; Kibel, Dijana; Degmečić, Dunja; Pavić, Roman

Source / Izvornik: **Collegium antropologicum, 2015, 39, 451 - 455**

Journal article, Published version

Rad u časopisu, Objavljena verzija rada (izdavačev PDF)

Permanent link / Trajna poveznica: <https://um.nsk.hr/um:nbn:hr:239:083776>

Rights / Prava: [In copyright](#)/[Zaštićeno autorskim pravom.](#)

Download date / Datum preuzimanja: **2024-11-24**



Repository / Repozitorij:

[Repository UHC Osijek - Repository University Hospital Centre Osijek](#)

From Postpartum Metastatic Cancer to Parathyroid Adenoma: A Case Report

Tatjana Bačun^{1,2}, Aleksandar Kibel^{1,3}, Vjekoslav Wertheimer⁴, Dijana Kibel⁵, Dunja Degmečić^{6,7} and Roman Pavić^{8,9}

¹»J. J. Strossmayer« University, University Hospital Centre Osijek, Internal Medicine Clinic, Osijek, Croatia

²»J. J. Strossmayer« University, School of Medicine Osijek, Department of Internal Medicine, Osijek, Croatia

³»J. J. Strossmayer« University, School of Medicine, Department of Physiology and Immunology, Osijek, Croatia

⁴»J. J. Strossmayer« University, University Hospital Centre Osijek, Orthopaedic Clinic, Osijek, Croatia

⁵Health Center Osijek, Osijek, Croatia

⁶»J. J. Strossmayer« University, University Hospital Centre Osijek, Clinic of Psychiatry, Osijek, Croatia

⁷»J. J. Strossmayer« University, School of Medicine, Department of Psychiatry, Osijek, Croatia

⁸University of Zagreb, University Hospital of Traumatology, Zagreb, Croatia

⁹»J. J. Strossmayer« University, School of Medicine, Department of Surgery, Osijek, Croatia

ABSTRACT

We present a 36 year old female patient with suspected postpartum advanced metastatic cancer and multiple osteolytic lesions due to which she was referred to the Internal medicine clinic for further diagnostic evaluation. After extensive investigation, it was discovered that the underlying condition was a parathyroid gland adenoma and the patient was treated surgically. Clinicians should note that parathyroid adenoma can mimic metastatic malignant disease, and should make appropriate diagnostic tests that will lead to the correct diagnosis.

Key words: parathyroid gland adenoma, osteolysis, metastasis, parathyroid hormone, calcium

Introduction

Primary hyperparathyroidism usually presents as hypercalcemia in an otherwise asymptomatic patient, or with complications such as nephrocalcinosis, osteoporosis, or a severe psychoneurologic disorder¹. It is most frequently caused by a single parathyroid gland adenoma¹. Rarely, primary hyperparathyroidism can even be caused by parathyroid carcinoma (in about 0.5–5%)^{2,3}, and an adenoma can be localized ectopically^{4–6}. In many cases, primary hyperparathyroidism and parathyroid gland adenoma can represent a diagnostic and therapeutic challenge because it is often not recognized correctly and at an appropriate time point. Timely diagnosis is, however, crucial in a clinical setting and can be vital for the patient involved. In this report, we are reviewing a case of suspected metastatic cancer at initial presentation, which – after thorough additional investigation – was in fact revealed to be a parathyroid adenoma. The report illustrates the necessity of taking this disease into consideration in diagnostic workups of suspected oncologic patients and describes one of the many faces of parathyroid gland adenoma. The pa-

tient described gave her informed consent for being reviewed in this work.

Clinical Case

A 36-year-old female patient, who gave birth by caesarean section 2 weeks earlier, was examined in the Department of Orthopedic Surgery Outpatient Clinic because of pain in her right hip. The analysis identified a fracture in the upper branches of the right pubic bone and the patient was hospitalized for further treatment. From her sixth month of pregnancy the patient experienced bilateral lumbar pain. She was examined by an orthopedist who concluded lumboischialgia, but X-ray diagnostics were not performed due to the pregnancy. Also in the sixth month of pregnancy she was diagnosed with extirpated tumor formation in the lower right jaw. Histopathology was found to be a gigantocellular granuloma. Ten months prior to pregnancy the patient underwent a left adnexectomy due

to ovarian endometriosis. The patient's family history included a father with angina pectoris and a mother who was diagnosed with breast cancer at the age of 64 years.

Radiographs of the lungs and heart were normal. In the projections of the rear tail ends of the ribs there were round, reasonably well limited soft tissue shadows with pathological fractures of the modified bone, to the right and left of the 5th–7th rib, which suggested metastatic changes in the ribs. Abdominal ultrasound findings were normal with hyperechoic bilateral renal parenchyma. The breast ultrasound showed numerous cystic zones that corresponded to dilated milk ducts, considered normal because the patient was nursing. Computed tomography of the thorax and abdomen showed a set of oval shaped bulges and areas of bone destruction up to 2.5 cm in diameter, positioned symmetrically at the rear ends of upper ribs, and multiple zones of destruction within several vertebrae and especially in the fifth lumbar vertebral body to the right consistent with osteolytic processes. Normal findings of the lungs, heart, upper abdominal organs and kidneys were reported. Computed tomography of the pelvis showed a hypodense expansive lesion 6×3 cm in diameter in the small joint of the fifth lumbar vertebra to the right which went on to destroy and infiltrate the vertebral body extending into the right neural recess. Inside the pelvic bones several osteolytic zones up to 2.5 cm in diameter were revealed, the most numerous along the left sacroiliac juncture, some of which destroyed the bone cortex. Another identical zone was at the base of the upper branch of the right pubic bone with pathological fracture of the bone. The uterus was enlarged corresponding to the condition 4 weeks after birth. It was concluded that these changes indicated metastatic bone lesions.

The main laboratory findings showed a slightly elevated leukocyte count ($11.2 \times 10^9/L$ with 79% neutrophilic granulocytes and lymphocytes 15%), mild normocytic anemia (hemoglobin 113 g/L), slightly increased platelet count ($468 \times 10^9/L$), mildly decreased protein (61.1 g/L) and albumin (34.2 g/L), alkaline phosphatase (541 U/L), mildly elevated creatinine (90 $\mu\text{mol/L}$, reference value to 80) and normal phosphates, total bilirubin, alanine transaminase (AST), aspartate aminotransaminase (ALT), gamma-glutamyl transpeptidase (GGT), lactate dehydrogenase (LD), urea, sodium and potassium, glucose and C-reactive protein (CRP). Findings of tumor markers (CA 15-3, CA 125, alpha fetoprotein (AFP) and CA 19-9) were normal with mildly elevated beta human chorionic gonadotropin (β HCG) levels. To determine the primary tumor the patient underwent positron emission tomography (PET/CT)—an established method for the visualization of tumors of unknown origin and localization⁷, which visualized intense pathological accumulation of fluorodeoxyglucose (FDG) in multiple regions of the skeleton (cranial bones, most notably in the right angulus of the mandible, in the left maxillary sinus and in the right side of the epipharynx, in upper arms, shoulder girdle bones, ribs, left and right sides of the thorax, thoracic and lumbar vertebrae, pelvis and upper leg) (Figure 1). A focal increase of metabolism was accentuated in the parenchyma of the right kidney. It was

concluded that the findings suggest secondary metastatic changes. A review by an endocrinologist was requested.

We performed additional processing. Elevated levels of total (3.43 mmol/L, reference interval 2.14 to 2.53) and ionized calcium (2.01 mmol/L, reference interval 1.13 to 1.32) were found with multiple elevated PTH (170.04, 236.88 and 251.27 pg/mL, reference range 6–29), and elevated alkaline phosphatase (455 U/L, reference interval 54–119) and normal phosphates in serum and 24 hour urine. Calcium in 24 hour urine was mistakenly not run, but this was corrected by the testing of calcium in the morning urine – it was found elevated (calcium/creatinine 1.83; reference interval 0.05 to 0.60). Thyroid ultrasound revealed a marginally elongated right lobe and an enlarged left lobe with nodal changes in both lobes and the lower two thirds of the left lobe were occupied by a hypoechoic node with good blood supply and a size of 5.0×2.4×2.3 cm (Figure 2). Cytological analysis of a fine needle biopsy sample suggested parathyroid neoplasm, which was confirmed by determining PTH levels in the sample – 1415 pg/mL, with a second (control) determination of PTH levels yielding an immeasurably high result, higher than 2500 pg/mL (reference range 6–29) with normal thyroglobulin in the aspirate. In the right submandibula a hypoechoic node was observed, surrounded by a hyperechoic rim (dimensions 3.1×2.8×2.8cm); in the cytological aspirate there were numerous osteoclasts. Densitometry of the spine revealed osteoporosis (T-score -4.6), hip (right hip T-score -5.0, left hip: -2.7) and forearm (T-score -3.4) with elevated osteocalcin (87.49 ng/mL, reference range 5–25) and pyrilinks D (37.53 nM DPD/mM; reference interval from 3.0 to 7.4) and mildly decreased 25 (OH) vitamin D (46.9 pmol/L). Detection of thyroid-stimulating hormone (TSH) was normal with minimally decreased free thyroxine (FT4) and normal anti-thyroid peroxidase (anti-TPO). Incurred additional tumor markers carcinoembryonic antigen (CEA), NSE, chromogranin A, CA 72-4, CA 242, CYFRA 21-1 and repeated findings of β HCG were normal. Other repeated laboratory findings showed no changes with a proper value of erythrocyte sedimentation rate and normal leukocytes and platelets. Electrophoresis and immunoelectrophoresis findings of serum proteins were normal, while free lambda light chains and caps in the serum and urine were markedly elevated with a normal ratio. After infusion of 0.9% NaCl with the diuretic furosemide Furosemide intravenously, there was a decrease in total (3.31 and 3.11 mmol/L) and ionized (2.01 and 1.85 mmol/L) calcium. The evaluation included review by maxillofacial surgeons, who concluded that the panoramic radiograph findings suggest hyperparathyroidism with the earlier pathologic finding of oral gigantocellular granuloma fitting well in. A dermatologist was consulted to rule out possible metastases of malignant melanoma. It was recommended that the histopathologic material previously removed from the oral tumor formation should be used for immunohistochemical staining for melanoma markers and Merkelcell carcinoma. Additionally, dermatoscopic examination of nevus-like skin lesions was advised. All these findings were normal. Gynecological control examination was normal. Parathyroid scintig-

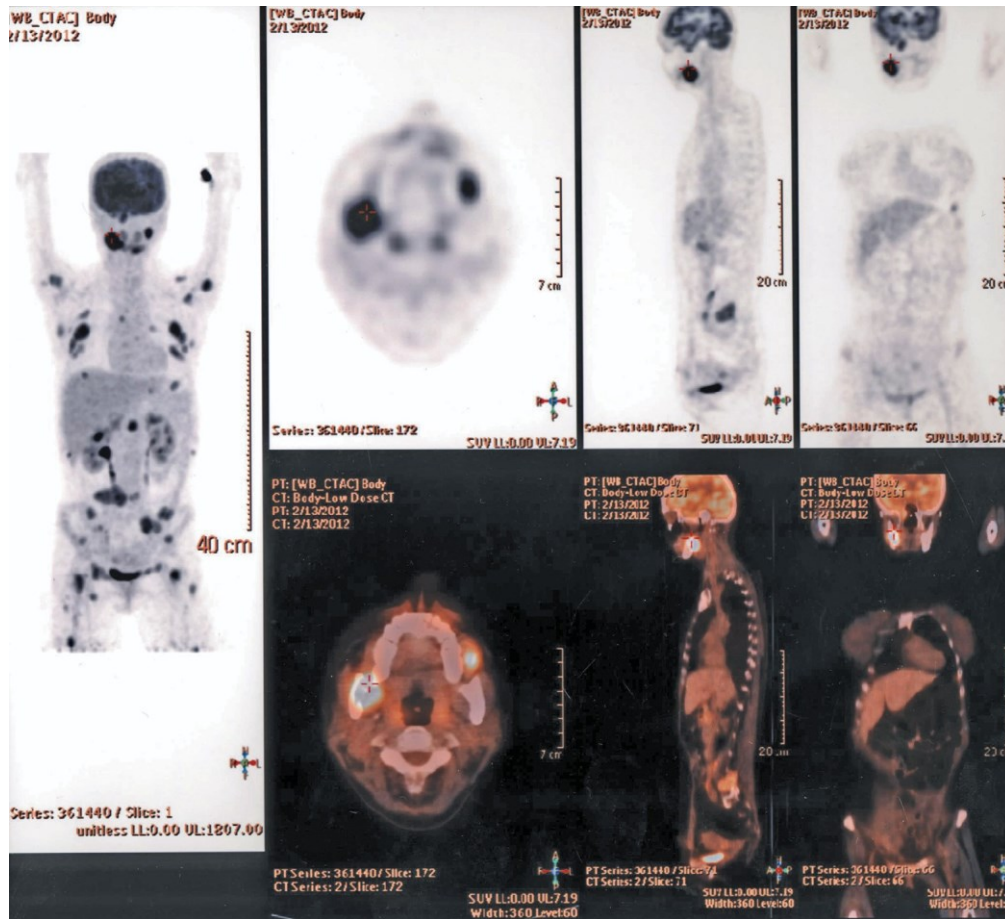


Fig. 1. PET/CT with intense pathological accumulation of fluorodeoxyglucose (FDG) in multiple regions of the skeleton.

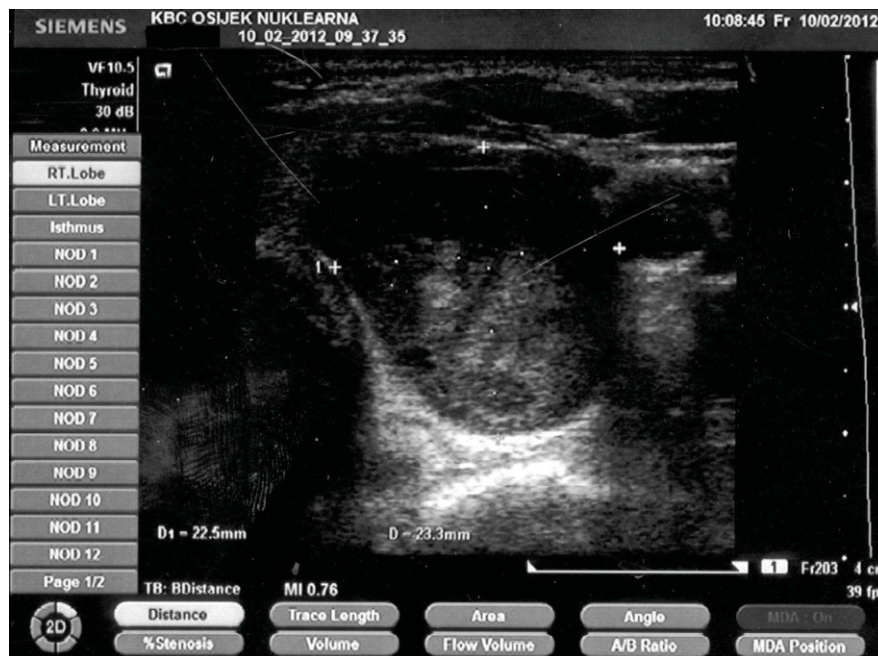


Fig. 2. Thyroid ultrasound showing lobe enlargement and nodal changes.

raphy has not been performed, because the family arranged to continue treatment at the Clinic for Tumors in another facility.

After the patient transfer was made, she underwent surgery to extirpate the left lower parathyroid gland. PTH before surgery was highly elevated (511 pg/mL, reference range up to 69), borderline (78.43 pg/mL) immediately after surgery, and normal (40.37 pg/mL) on the day after surgery. She was given calcium carbonate tablets 3×1 gram per day for therapy. Her son had a seizure and was hospitalized at the pediatric hospital. The child was diagnosed with hypocalcaemia. Following reimbursement of calcium and vitamin D, calcium levels were normal and the child was clinically well. The patient presented for a control examination after a month. PTH was still in normal range with normal values of total and ionized calcium and phosphate in serum and 24 hour urine. Calcium citrate tablets 2000 mg and calcitriol 0.5 mg (Rocaltrol capsules) were recommended to her as further therapy.

Conclusion

Although patients with parathyroid gland adenoma are mostly asymptomatic with hypercalcemia, uncommon presentations of this clinical condition have been described

before, such as hemorrhagic neck masses and recurrent laryngeal nerve paralysis with dysphonia^{8,9}, general bone pains¹⁰, quadriplegia¹¹, associations with other tumors^{12–15}, osteitis fibrosa cystica¹⁶ and others. Parathyroid gland adenoma has been reported during pregnancy^{17,18}.

In our case, a female patient who gave birth 2 weeks before presenting to our clinic, had radiological findings of multiple osteolytic lesions which suggested advanced metastatic disease. During pregnancy, an oral tumor was removed and pathologically identified as a gigantocellular granuloma. Prior to the pregnancy, she underwent adnexectomy because of endometriosis. After careful diagnostic follow-up, we concluded that the patient had in fact primary hyperparathyroidism associated with a parathyroid gland adenoma, which was managed effectively.

Parathyroid adenoma can mimic metastatic disease in certain cases. When presented with a suspected metastatic disease, with multiple osteolytic foci of the skeleton, a clinician should also keep in mind that a parathyroid adenoma can be a primary cause of such changes instead of metastatic cancer and that a broad differential diagnosis with additional tests such as total and ionized serum calcium and PTH (followed by thyroid imaging¹⁹ and biopsy) in such circumstances can be extremely helpful for a timely and precise diagnosis.

REFERENCES

1. AACE/AAES Task Force on Primary Hyperparathyroidism, Endocr Pract, 11 (2005) 49. — 2. RICCI G, ASSENZE M, BARRECA M, LIOTTA G, PAGANELLI L, SERAO A, TUFODANDRIA G, MARINI P, Int J Surg Oncol. 2012 (2012). DOI: 10.1155/2012/649148. — 3. KOTROMANOVIĆ Z, BIRTIĆ D, VCEVA A, MEDIĆ D, ZUBČIĆ Z, MIHALJ H, KOTROMANOVIĆ Z, ERIĆ S, DMITROVIĆ B, STEFANIĆ M. Coll Antropol. 36 (2012) 23. — 4. SPINELLI C, LISERRE J, PUCCI V, MASSART F, GROSSO M, BRANDI ML, J Pediatr Endocrinol Metab. 25 (2012) 781. DOI: 10.1515/jpem-2012-0101. — 5. TUBA LIMAN S, TOPCU S, DERVISOGLU E, DAGLIOZ GORUR G, ELICOR A, BURC K, AKGUL AG, Ann Thorac Cardiovasc Surg. (2012). — 6. KWEE HW, MARAPIN V, VERKEYN JM, VAN NEDERVEEN FH, Ned Tijdschr Geneesk, 156 (2012) A5146. — 7. DIRISAMER A, HALPERN BS, FLÖRY D, WOLF F, BEHESHTI M, MAYERHOEFER ME, LANGSTEGER W, Eur J Radiol. 73 (2010) 324. DOI: 10.1016/j.ejrad.2008.10.030. — 8. GIVENS DJ, HUNT JP, BENTZ BG, Head Neck, 2012 (2012). DOI: 10.1002/hed.23124. — 9. HUANG J, SOSKOS A, MURAD SM, KRAWISZ BR, YALE SH, URQUHART AC, 18 (2012) e57. DOI 10.4158/EP11329. CR. — 10. LI L, CHEN L, YANG Y, HAN J, WU S, BAO Y, JIA W, Clin Nucl Med, 37 (2012) 889. DOI: 10.1097/RLU.0b013e31825ae8b6. — 11. KAMALANATHAN S, BALACHANDRAN K, HALANAİK D, CHANDRA S, BMJ Case Rep, 2012 (2012).; DOI: 10.1136/bcr.01.2012.5578. — 12. ANDREASSON A, SULAIMAN L, DO VALE S, MARTINS JM, FERREIRA F, MILTENBERGER-MILTENYI G, BATISTA L, HAGLUND F, BJÖRCK E, NILSSON IL, HÖÖG A, LARSSON C, JUHLIN CC, Fam Cancer, 11 (2012) 355. DOI: 10.1007/s10689-012-9520-z. — 13. SYRO LV, SCHEITHAUER BW, KOVACS K, TOLEDO RA, LONDOÑO FJ, ORTIZ LD, ROTONDO F, HORVATH E, URIBE H, Clinics (Sao Paulo), 67 (2012) 43. DOI: 10.6061/clinics/2012(Sup01)09. — 14. LEE YS, NAM KH, CHUNG WY, CHANG HS, PARK CS, J Korean Surg Soc. 81 (2011) 316. DOI: 10.4174/jkss.2011.81.5.316. — 15. PASTA V, REDLER A, PALMIERI A, CHIARINI S, MEROLA R, MONTI M, Ann Ital Chir, 82 (2011) 55. — 16. AIRAGHI L, PISANO G, PULIXI E, BENTI R, BALDINI M, J Res Med Sci, 16 (2011) 1078. — 17. SCHNATZ PF, CURRY SL, Obstet Gynecol Surv, 57 (2002) 365. DOI: 10.1097/00006254-200206000-00022. — 18. EL OUAHABI H, SALHI H, BOUJARAF S, AJDI F, Indian J Endocrinol Metab, 16 (2012) 666. DOI: 10.4103/2230-8210.98045. — 19. ALIMANOVIĆ-ALAGIĆ R, BRKOVIĆ A, KUCUKALIĆ-SELIMOVIĆ E, Med Arh, 62 (2008) 303.

T. Bačun

»J. J. Strossmayer« University, School of Medicine, University Hospital Centre Osijek, Internal Medicine Clinic, Department of Endocrinology, J. Huttlera 4, Osijek, Croatia
e-mail: tatjana.bacun@os.t-com.hr

OD POSTPOROĐAJNOG METASTATSKOG TUMORA DO ADENOMA PARATIREOIDNE ŽLIJEZDE

SAŽETAK

Prikazuje se 36-godišnja bolesnica sa sumnjom na poslijeporođajni uznapredovali metastatski karcinom i s višestrukim osteolitičkim lezijama zbog čega je upućena na Internu kliniku radi daljnje dijagnostičke obrade. Nakon opsežne obrade, otkriveno je da se radi o adenomu paratireoidne žlijezde te je bolesnica operativno liječena. Kliničari trebaju imati na umu da adenom paratireoidne žlijezde može oponašati metastatsku malignu bolest te trebaju učiniti odgovarajuće dijagnostičke pretrage koje će uputiti na dijagnozu.